QM 28
.N42
Copy 1

LIBRARY OF CONGRESS.

[SMITHSONIAN DEPOSIT.]

Chap. QM 28

Shelf .N42

UNITED STATES OF AMERICA.

A

HAND-BOOK

OF

ANATOMY.

A

HAND-BOOK

OF

ANATOMY:

With One Hundred and Fifty-Nine Illustrations.

BEING A PORTION OF

AN ANALYTICAL COMPENDIUM

OF THE

VARIOUS BRANCHES OF MEDICINE.

BY

JOHN NEILL, M. D.,

SURGEON TO WILLS' HOSPITAL, DEMONSTRATOR OF ANATOMY IN THE UNIVERSITY OF PENNSYLVANIA, LECTURER ON ANATOMY IN THE PHILADELPHIA MEDICAL INSTITUTE, FELLOW OF THE COLLEGE OF PHYSICIANS, ETC.,

AND

FRANCIS GURNEY SMITH, M. D.,

LECTURER ON PHYSIOLOGY IN THE PHILADELPHIA ASSOCIATION FOR MEDICAL INSTRUCTION, PHYSICIAN TO THE ST. JOSEPH'S HOSPITAL, ETC.

SECOND EDITION, REVISED AND IMPROVED.

SMITHSONIAN INSTITUTION

PHILADELPHIA:
BLANCHARD AND LEA.
1852.

C. SHERMAN, PRINTER.

CONTENTS.

PAGE

Definition of Anatomy, - - - - - - 13

SECTION I.

BONES.

General anatomy of bone, - - - - - - 14
Periosteum, - - - - - - - - 14
Marrow, - - - - - - - - 15
Formation and growth of bone, - - - - - 15
Callus, - - - - - - - - 15
Cervical vertebræ, - - - - - - - 16
Dorsal vertebræ, - - - - - - - 17
Lumbar vertebræ, - - - - - - - 17
Sacrum, - - - - - - - - 18
Coccyx, - - - - - - - - 18
Innominatum, - - - - - - - 19
Sternum, - - - - - - - - 21
Ribs, - - - - - - - - 22
Bones of the cranium, - - - - - - 23
Bones of the face, - - - - - - - 30
Hyoid bone, - - - - - - - - 36
Scapula, - - - - - - - - 37
Clavicle, - - - - - - - - 38
Humerus, - - - - - - - - 38
Ulna, - - - - - - - - 39
Radius, - - - - - - - - 40
Carpus, - - - - - - - - 41
Metacarpus, - - - - - - - 42
Phalanges of the fingers, - - - - - - 42
Femur, - - - - - - - - 43
Patella, - - - - - - - - 44
Tibia, - - - - - - - - 44
Fibula, - - - - - - - - 46
Tarsus, - - - - - - - - 46
Metatarsus, - - - - - - - - 48
Phalanges of the toes, - - - - - - 49

SECTION II.

ARTICULATIONS.

	PAGE
Of ligaments generally,	49
Ligaments of the lower jaw,	51
Ligaments of the vertebræ,	52
Ligaments of the pelvis,	53
Ligaments of the ribs,	54
Ligaments of the shoulder,	55
Ligaments of the elbow,	57
Ligaments of the wrist,	58
Ligaments of the fingers	58
Ligaments of the hip,	59
Ligaments of the knee,	59
Ligaments of the ankle,	60
Teeth,	62
Cellular tissue,	64
Fat,	65
Skin,	65
Nails,	66
Hair,	67

SECTION III.

MUSCLES.

General anatomy of,	69
Muscles of the head and face,	70
Muscles of the neck,	72
Muscles of the chest,	74
Muscles of the abdomen,	76
Anatomy of Inguinal Hernia,	77
Muscles of the back,	83
Muscles of the shoulder and arm,	86
Muscles of the forearm,	87
Muscles of the hand,	90
Anatomy of femoral hernia,	92
Muscles of hip and thigh,	94
Muscles of the leg,	96
Muscles of the foot,	98

SECTION IV.

VISCERA.

Mouth,	100
Tongue,	100
Muscles of tongue,	101
Palate,	102
Salivary glands of the mouth,	103
Pharynx and œsophagus,	104

PAGE
Regions of abdomen, 106
Peritoneum, 107
Mesentery, 108
Stomach, 109
Intestines, 111
Liver, 116
Gall bladder, 119
Pancreas, 119
Spleen, 120
Kidneys, 121
Supra-renal capsules, 122
Bladder, 122
Penis, 123
Vesiculæ seminales, 126
Prostate gland, 126
Scrotum and testicles, 126
Spermatic cord, 128
Muscles of perineum and anus, 130
Larynx, 131
Trachea, 134
Thyroid gland, 135
Lungs, 135
Pleura, 136
Mediastinum, 137
Thymus gland, 137
Heart, 137
Pericardium, 137

SECTION V.

VESSELS.

Structure of arteries, 140
Aorta, 140
External carotid artery, 141
Internal maxillary artery, 142
Arteries of the brain, 143
Subclavian artery, 144
Axillary artery, 145
Brachial artery, 146
Thoracic aorta, 147
Abdominal aorta, 148
Cœliac axis, 148
Superior mesenteric artery, 149
Renal artery, 150
Inferior mesenteric artery, 150
Internal iliac artery, 151
External iliac artery, 153
Femoral, 153
Anterior and posterior tibial, 154
Veins, 156
Veins of the head and neck, 156
Sinuses of the dura mater, 157
Veins of the upper extremity, 159

PAGE
Ascending cava, - - - - - - - 160
Descending cava, - - - - - - - 160
Vena azygos, - - - - - - - - 161
Portal vein, - - - - - - - 161
Veins of the lower extremity, - - - - - - 162
Lymphatics, - - - - - - - 162

SECTION VI.

NERVOUS SYSTEM.

General anatomy of, - - - - - - - 163
Membranes of the spinal marrow, - - - - 163
Spinal marrow, - - - - - - - 164
Membranes of the brain, - - - - - - 165
Brain, - - - - - - - - - 166
Cranial nerves, - - - - - - - 169
Spinal nerves, - - - - - - - 174
Cervical nerves, - - - - - - 175
Dorsal nerves, - - - - - - - 176
Lumbar nerves, - - - - - - - 176
Sacral nerves, - - - - - - - 177
Sympathetic nerve, - - - - - - 179
Cervical ganglia, - - - - - - - 180
Thoracic ganglia, - - - - - - - 181
Lumbar and sacral ganglia, - - - - - 182

SECTION VII.

ORGANS OF SENSE.

Nose, - - - - - - - - 182
Eye and its appendages, - - - - - - 183
Ear, - - - - - - - - 187

ANATOMY.

Anatomy is the science which investigates the structure and organization of living beings.

Special Anatomy or *Descriptive Anatomy* is the consideration of each organ or part of the human body, including its size, weight, colour, shape, &c.

General Anatomy investigates the different tissues or structures out of which organs are formed.

Surgical Anatomy or *Regional Anatomy* is the study of the relation of one part to another, and is one of the most important applications of anatomy to the practice of medicine and surgery.

Physiological Anatomy considers the uses and functions of organs in a healthy state.

Pathological Anatomy regards the different organs altered by disease.

This is a compendium principally of special anatomy; and is divided into seven sections:

1. Bones.
2. Ligaments.
3. Muscles.
4. Viscera.
5. Vessels.
6. Nerves.
7. Special Senses.

SECTION I.

BONES.

GENERAL CONSIDERATIONS OF BONE.

The bones of the *skeleton* are two hundred and eleven in number, of which twenty-two belong to the head, fifty-six to the trunk, sixty-nine to the superior and sixty-four to the inferior extremity; when held together by ligaments and cartilages they form a natural skeleton, when by other means an artificial skeleton. They are hard, white, and inflexible; and more numerous in childhood than in old age.

They are *classified* into long, thick, and flat bones. The body or shaft of a long bone is called Diaphysis; its articulating extremities, Epiphyses; its processes and projections are called Apophyses. The small foramina on the surface of bones are for the transmission of nutritious vessels, the largest of which enters about the middle.

Bones are composed of two *structures, compact* and *cellular*. The compact structure consists of small fibres arranged in laminæ; each of these fibres has a canal running through its length, called the canal of Havers, transmitting vessels; it communicates with small lenticular excavations, called *corpuscles of Purkinje*, by radiating tubes. The cellular structure increases the volume and strength without increasing the weight, and also diminishes the effect of concussion. The cells communicate with each other, and contain marrow.

Composition of Bones.—Bones are chemically composed of animal and earthy matters, united in the proportion of two parts of earthy to one of animal. By the analysis of Berzelius, they consist of thirty-two parts of gelatine, one part of insoluble animal matter, fifty-one parts of phosphate of lime, eleven of carbonate of lime, two of fluate of lime, one of phosphate of magnesia, and one of soda and muriate of soda. The earthy matter is most abundant in bones of the cranium: the animal matter in the cellular structure. Combustion will remove the animal matter, and dilute acids will remove the earthy matter.

The *Periosteum* is a white fibrous membrane investing the external surface, adhering less firmly in infancy, and becoming ossified in old age. It is vascular, insensible in health, assists in the secretion of the external laminæ, restrains ossification within proper

limits, receives the insertion of muscles, tendons, &c. and protects the bone from suppuration in the vicinity.

Marrow is contained in a fine vascular membrane, lining the medullary canals and cells of bones, called the *Internal Periosteum.* It resembles fat, but consists of finer granules; in consumption, dropsy, &c., it is absorbed and its place is supplied with serum.

Formation and growth of bones.—There are three stages of ossification in the embryo. The first is the mucous or pulpy, which continues for one month; the second is the cartilaginous, and the third the osseous, commencing at the third month. The colour of the cartilage deepens and then a vessel conveys red blood to a central point, which first receives calcareous particles and is called *punctum ossificationis.* Bones increase in length by continued deposit at their extremities between the Diaphysis and the Epiphyses, as is proved by Hunter's experiment of placing two shot in the tibia of a young pig; after the animal had reached full size, the shot were found at their original distance from each other. Bones increase in thickness by external deposit and by secretion from the periosteum, which is proved by disease and the experiment of feeding a young pig with food coloured with madder. Various laminæ of white and coloured bone can be produced by suspending and resuming this mode of feeding. While deposit is taking place upon the surface of a bone, absorption is going on internally; this is proved by Duhamel's experiment of surrounding a long bone of a young animal with a metallic ring; after the animal was fully grown, the ring was found in the medullary canal, which increases in size by this constant deposit and absorption.

Callus.—When bones are fractured, the process of reparation resembles that of the formation of a bone. Blood is effused, and lymph is thrown out, causing a swelling. Afterwards the blood is absorbed and the lymph becoming cartilage ossifies in the form of a ring, which surrounds the seat of fracture, and also in the form of a pin in the medullary canal.

After the fractured extremities have united, the superfluous ring and pin of bone which acted as splints are absorbed. Whilst this process is going on, it is important that the parts should be maintained at rest, otherwise the process of ossification is arrested, and a false joint results.

BONES OF THE TRUNK.

The trunk consists of the Spine, Pelvis, and Thorax.

SPINE.

It extends from the head to the coccyx at the posterior part of the trunk, having several curvatures. In the neck it is

convex anteriorly, in the thorax concave, in the loins convex, and in the pelvis concave. It contains an osseous canal for the spinal marrow, and is formed of 28 or 29 separate bones, called *vertebræ*, 24 of which are classified as *true vertebræ*, on account of their mobility, and the 5 remaining are called *false vertebræ*. The true vertebræ are divided into 7 *cervical*, 12 *dorsal*, and 5 *lumbar*; the false vertebræ consist of the sacrum, and 3 or 4 coccygeal bones.

A vertebra consists of a body, 7 processes, and a spinal foramen. The *body* is in front, and is the thickest part; it supper and lower surfaces articulate with a contiguous vertebra by means of a cartilage; it is convex anteriorly from side to side. The *processes* are, one *spinous*, of a triangular shape, and situated behind for the attachment of muscles; two *transverse*, one projecting horizontally on either side for the attachment of muscles and ligaments; and four *oblique* processes, two of which are superior and two inferior, which are for the purpose of articulation. The *spinal foramen* is in the middle, and constitutes a portion of the spinal canal. The *intervertebral foramen* is formed on each side by a groove upon the upper and lower surface of each vertebra, and transmits a spinal nerve.

CERVICAL VERTEBRÆ.

Fig. 1.

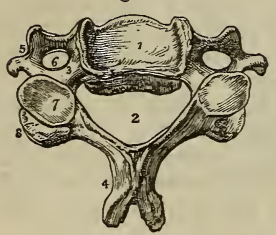

The *bodies* are small, and flattened in front; the superior surfaces[4] are concave laterally, the inferior are concave antero-posteriorly; they gradually increase in size. The *spinous processes*[4] are short, thick, horizontal, and bifid. The *oblique processes* are flat, oval, and short; the *superior*[7] look upwards and backwards, and the *inferior*[8] downwards and forwards at an angle of forty-five degrees. The *transverse processes*[5] are broad, perforated at their base by a foramen[6] for the transmission of the vertebral artery. The *spinal foramen*[2] is very large and triangular.

The *first cervical vertebra* is called the *atlas;* it has no body, and resembles a ring. In place of a body, there is an arch which has a tubercle in the middle of its anterior surface; in the corresponding part of its posterior surface is an articular fossa for the *processus dentatus* of the second vertebra. The posterior arch has a tubercle instead of the spinous process. The *superior oblique processes* are large, oblong, and concave, adapted to the condyloid processes of the occiput; and admit of flexion and extension. The

inferior oblique processes are round, flat and horizontal, adapted to the rotatory motion of the head. The transverse process is extremely long. On the inner side of the oblique processes is a tubercle for the attachment of the transverse ligament. It has the largest *spinal foramen.*

The *second* cervical vertebra is called *dentata*, from its tooth-like process projecting from the upper surface of the body; the tip of which is rough for the middle straight ligament, and on the sides of the tip there is a flatness for the attachment of the moderator ligaments. This process is smooth in front where it touches the arch of the atlas and also behind where the transverse ligament plays. Upon this process the head rotates. The *superior oblique process* is circular and slightly convex. The *spinous* process is long and bifid.

The *sixth* has a long and pointed *spinous* process.

The *seventh* is the largest and resembles a dorsal. The spinous process is the longest and tuberculated. The foramen at the base of the transverse process does not transmit the vessels.

DORSAL VERTEBRÆ.

These are twelve in number. The *bodies*[1] are cylindrical, and their transverse diameter decreases from the first to the third, and then increases. The upper and lower surfaces are flat, and the sides have articular marks[3] for the heads of the ribs. Each fossa is formed by two contiguous vertebræ. The *oblique* processes are vertical, the superior[8] looking backwards and the inferior[9] looking forwards. The *transverse* processes[7] are long, and their extremities are enlarged; in front there is an articular face for the tubercle of the rib. The *spinous* processes[5] are long and triangular, broad at the base, sharp-pointed and overlap each other. The spinal foramen is small and round. The intervertebral foramen is mainly formed by the inferior groove,[5] which is much deeper than the superior.[4]

Fig. 2.

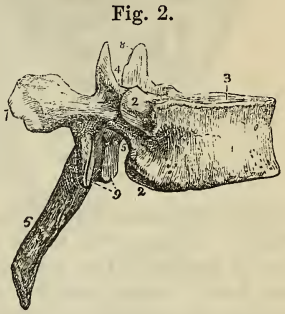

The *first* has a complete fossa for the head of the rib upon its side. The *eleventh* and *twelfth* have also complete fossæ for the heads of the ribs. Their transverse processes are short, directed backwards, and do not articulate with the ribs.

LUMBAR VERTEBRÆ.

Their number is five. The *bodies* are large and oval, the trans-

Fig. 3.

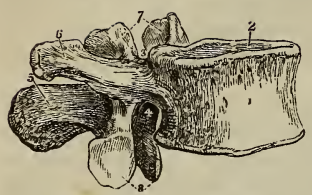

verse diameter being the longest. The spinal foramen is triangular and large. The grooves[3] [4] forming the intervertebral foramen are also large. The *oblique* processes are vertical; the superior[7] looking inwards and the inferior[8] looking outwards. The *transverse* processes[6] are long and at right angles. The *spinous*[5] processes are short, thick, quadrangular, and horizontal.

The *first* is the smallest; the *third* has the longest transverse process; the *fifth* has a wedge-shaped body.

SACRUM.

Is triangular, and originally consisted of five pieces; its *anterior surface* is concave, and has four funnel-shaped holes[6] [6] on each side, transmitting the anterior branches of the sacral nerves. Its *posterior surface* is rough and convex, and contains the representations of spinous and oblique processes. A fissure usually exists in place of the fourth and fifth spinous processes. There are four foramina on each side, smaller than those in front, for the transmission of the posterior branches of the nerves. The *base* has a large oval articular mark[1] upon which rests the last lumbar vertebra; it has also two oblique processes, and two grooves completing the intervertebral foramina.[9] The *apex*[2] is blunt and has a transverse articular surface[2] for the coccyx. The *sides* are rough, broader above than below, and have a large articular mark for the innominata; behind this surface arise muscles of the back, and below it the sacro-iliac ligaments. The *sacral canal* runs through the length of the sacrum. It is triangular, larger above than below;[6] and is continuous with the spinal canal. It contains the cauda equina; and with it communicate the foramina transmitting the nerves.

Fig. 4.

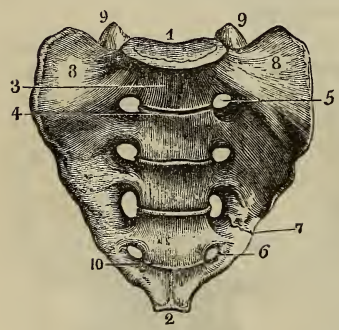

COCCYX.

The coccyx is flat and triangular, having its base upwards. It

consists of three or four bones united usually in the same curve as that of the sacrum. The pieces are frequently united with each other and the sacrum.

Fig. 5.

The *first* piece is the largest, and has two articular marks; behind, it has two *cornua*;[2 3] on its side are grooves,[4 5] which with the sacrum complete the canal for the fifth sacral nerve. The *last piece*[6] is a mere tubercle. The sides of the coccyx give origin to muscles and ligaments.

PELVIS.

The pelvis consists of the *sacrum*, *coccyx*, and the *two innominata* or hip bones.

INNOMINATUM.

This is a large flat bone forming the haunch or hip of common language, resembling in some measure the figure 8. In youth it

Fig. 6.

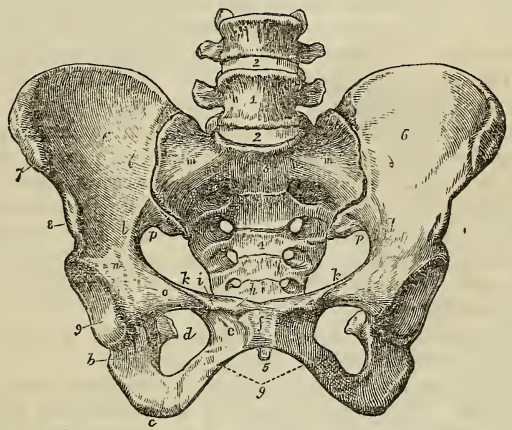

consists of three different parts, united in the acetabulum, viz. the ilium, ischium, and pubes.

Ilium.—This is the largest piece, and forms the wall of the upper pelvis. Its *external* surface is convex and rough, with a semicircular ridge crossing it; above this ridge arises the gluteus medius, and below it the gluteus minimus muscle; the posterior part of this surface is the roughest, and gives origin to the gluteus maximus.

The anterior part of the internal surface[6] contains a large, smooth concavity called the costa, which gives origin to the iliacus internus;

the posterior is rough and has a large articular mark for the sacrum, behind which arise muscles and ligaments. The *edge* or *crista* is arched and curved like the italic *f*. In front there are two eminences, one of which is called the *anterior superior spinous process*,[7] giving origin to the sartorius and tensor vaginæ muscles and Poupart's ligament; the other is the *anterior inferior spinous process*,[8] and gives origin to the rectus muscle; the space between the two gives origin to the gluteus medius. Below these processes is a large prominence[n] called *ilio-pectineal;* in the groove above this passes the iliacus internus and psoas magnus muscles. The posterior *superior* and *inferior spinous* processes are behind, and to them are attached ligaments. The *crista* has three lips, from the internal of which arises the transversalis muscle, from the middle arises the internal oblique, and into the external is inserted the external oblique. The inferior border of the ilium presents a *notch*,[p] called *sciatic.*

Ischium.—This is the most inferior part of the innominatum. It consists of a body and a branch; the external surface of the body[b] is rough; the internal surface is smooth, and is called the *plane* of the ischium. The posterior border presents a projection called the *spine,* into which is inserted the lesser sacro-sciatic ligament, and beneath the spine is a groove in which plays the tendon of the obturator internus muscle. The inferior portion of the body is called the *tuberosity,*[c] from which arise the semi-membranosus, semi-tendinosus, and the long head of the biceps muscles; in front there is a ridge into which is inserted the greater sacro-sciatic ligament; outside of the ridge is the origin of the adductor magnus muscle.

The *ramus* or branch is short and thick, and ascends forward and inward, joining the ramus of the pubes, and forming a portion of the pubic arch;[9] externally it is rough, and internally it is smooth, whence arises the crus of the penis.

Pubes.—It forms the anterior boundary of the pelvis,[6] and consists of a *body* and descending *ramus* or *branch.*

The *body* articulates with its fellow by a vertical surface,[f] called the *symphysis.* The superior portion of the body at right angles with the symphysis is *horizontal*,[h] and limited externally by a projection[i] called the *spinous process;* from this process there diverge two ridges; the posterior[k] is sharp and called the *crista of the pubes,* or *linea pectinea;* to it is attached a portion of Poupart's and Hey's ligament. Between these ridges is included a triangular space,[o] the base being the ilio-pectineal eminence,[n] and the apex of the spinous process; from this space arises the pectineus muscle, and over it pass the femoral vessels. The anterior ridge terminates at the acetabulum.

The *ramus* descends to join that of the ischium, and forms a part of the pelvic arch; externally it is rough for the origin of the ab-

ductor muscles; internally it is smooth, and from it arises the crus of the penis.

The *acetabulum*,[9] is a deep hemispherical concavity upon the outer side of the bone for the articulation of the head of the femur. The brim of this cavity is notched on the lower edge. In the bottom of the cavity is a rough depression occupied by a mass of fat, commonly called a gland of Havers. Immediately beneath the acetabulum is a groove, in which plays the tendon of the external obturator muscle.

The *obturator* or *thyroid foramen*, is that large opening in the front and lower part of the bone, which is filled up by a membranous ligament, with the exception of a groove at its upper part, through which pass the obturator vessels and nerve. Its shape is oval in males, but triangular in females.

THORAX.

This cavity is formed by the dorsal vertebræ, ribs and sternum; its figure is conoidal, flattened in front, and concave behind; the apex presents a cordiform opening, and the opening at the base has a large notch in front.

Fig. 7.

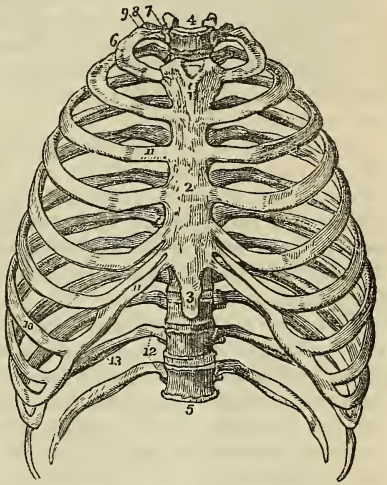

STERNUM.

Is an oblong, slightly-curved bone, placed in front of the thorax. Usually it consists of three pieces, but in advanced life of but one.

The *first* or superior bone,[1] is the thickest, and resembles in shape a triangle, with the corners cut off, the base being upwards; on the superior edge is a concavity for the benefit of the movements of the trachea; on each side is a large concavity for the articulation of the clavicle, and below are two smaller ones for the articulation of the first and part of the second rib.

Sometimes there are found upon the upper edge of the first bone two small spherical bones called *Episternal bones*.

The *second* bone[2] is longer and narrower than the first, increasing

in breadth in its lower extremity; its sides present pits for the articulation of part of the second, the third, fourth, fifth, sixth, and part of the seventh ribs.

The *third* bone,[3] is very frequently cartilaginous, and called xyphoid or ensiform; its shape varies, sometimes being pointed, and sometimes bifurcated; upon its side is a depression for a portion of the seventh rib.

RIBS.

These are twenty-four in number, twelve on either side; those that articulate with the sternum are called *true* ribs, and are seven in number; the five below them are called *false* ribs: in some rare instances there have been thirteen or eleven ribs on one side. They are parallel, and directed obliquely downwards and forwards; each having a parabolic curve, and gradually increasing in size until the eighth, afterwards gradually diminishing.

The *anterior* or *sternal* extremity is larger and flatter than the *posterior;* the *posterior* or *vertebral* extremity presents a spherical head, having two articular surfaces separated by a ridge. The *neck* of the rib is very narrow and its upper edge, which is sharp, has inserted into it the *internal costo-transverse* ligament; about one inch from the head is the tubercle, a prominence with an articular face, for articulation with the transverse process of the vertebra; just beyond this is a smaller tubercle, for the insertion of the *external costo-transverse* ligament.

Each rib is twisted and bent; this bend constitutes the *angle* of the rib; upon the external surface of the angle is a mark showing the insertion of the sacro-lumbalis muscle. The *lower* edge of the rib is thin and cutting, and just within it is a groove,[13] running two-thirds of its length, and containing the intercostal vessels and nerve. The *upper* edge is rounded, and upon it are inserted the intercostal muscles.

The *first* rib is small and semicircular, its surface looking superiorly and inferiorly; the superior surface has upon its middle a slight fossa, for the subclavian artery; in front of this is a roughness for the insertion of the scalenus anticus muscle, behind it another for the insertion of the scalenus medius; the head has a single articular surface, its angle is at the tubercle, and it has no intercostal groove.

The *eleventh and twelfth*,[12] are called *floating* ribs, because they are not connected with the others; they have no tubercles, and their heads have but a single articular surface. The twelfth is very short, but slightly curved, and has no intercostal groove.

BONES OF THE HEAD.

These are twenty-two in number, and are divided into those of the cranium, which are eight in number; and those of the face, which are fourteen.

CRANIUM.

FRONTAL BONE.

This forms the forehead. It is usually a single, symmetrical bone, though occasionally divided by a suture into two parts. Its shape resembles that of a shell.

Fig. 8.

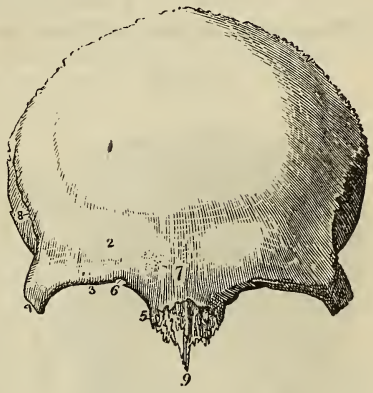

The *external surface* is convex, and about the middle upon each side there is the *frontal protuberance*,[1] being the original centre of ossification; below this and nearer the median line is an oblique ridge called the *nasal* or *superciliary protuberance*.[2] The inferior edge of the bone is formed on either side by the *orbitary ridge*,[3] forming the superior boundary of the orbit of the eye; this ridge is terminated outwardly by the external angular process,[4] just within which is a depression for the lachrymal gland, and inwardly by the internal angular[5] process; between the internal angular processes is a prominence called the *nasal spine*,[9] which serves as an abutment for the nasal bones. Upon this orbitary ridge, half an inch distant from the internal angular process, a small depression exists, upon which plays the tendon of the superior oblique muscle; to the outside of this depression is a notch or foramen, for the transmission of the supra-orbital artery and nerve.[6]

The *frontal sinus*[7] opens near the internal angular process, and is formed by the separation of the tables over the orbitary ridge; its capacity varies, and there are no means of determining it in the living being; it empties into the infundibulum of the ethmoid.

The *internal surface* is concave and has numerous depressions corresponding with the convolutions of the brain; in the middle is a fossa for the superior longitudinal sinus, and a ridge for the attachment of the dura mater; at the bottom of this ridge is the *foramen*

cæcum, transmitting a vein, which forms the commencement of the sinus.

The *orbitar processes* are two horizontal plates, forming the roofs of the orbits, separated by a large space, which is occupied by the ethmoid bone. The *internal* edges of these processes have two grooves, which are converted into foramina, called ethmoidal or orbitary, by the articulation of the ethmoid. Each transmits an artery and a vein to the nose. The *anterior ethmoidal foramen* also transmits the internal nasal nerve.

Laterally the bone articulates with the parietal and sphenoid, inferiorly with the bones of the face and with the ethmoid.

PARIETAL BONES.

These occur in pairs, and form the middle and lateral portions of the cranium; they are quadrangular.

Fig. 9.

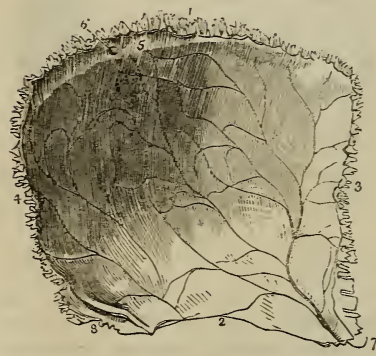

The *external surface* is convex, has in its middle the parietal protuberance, the centre of ossification; below this is the semicircular ridge indicating the attachments of the temporal fascia and muscle.

The *internal surface* is concave, with numerous depressions for the convolutions of the brain, and is also traversed by furrows showing the course of the middle artery of the dura mater. The *superior* edge[1] is the thickest and much dentated; when adjusted with its fellow, it forms a deep groove for the longitudinal sinus.[5] The parietal foramen,[6] transmitting a vein, opens in this groove. The *inferior* edge[2] is short, concave, and squamous, articulating with the temporal. The anterior inferior angle[7] is long and pointed, articulating with the great wing of the sphenoid; the posterior inferior[8] angle is very obtuse, and deeply grooved on its internal surface for the lateral sinus.

OCCIPITAL BONE.

This is placed at the posterior and inferior part of the head, and is of an oval or trapezoidal shape.

The *external surface* is convex, and in some parts rough; near its middle is a prominence called the *external occipital cross*,[2] from which there proceeds on each side a semicircular ridge,[1] to which is inserted the sterno-cleido-mastoideus muscle, and from which arise

the trapezius and occipital frontalis. About one inch below is another semicircular ridge[4] for the insertion of the superior oblique muscle. Between this ridge and the foramen magnum, the space is occupied by the recti postici muscles. Reaching from the external occipital cross is a vertical ridge[3] extending to the foramen magnum, to which is attached the ligamentum nuchæ. The space between the superior and inferior semicircular ridges is occupied by the insertion of the splenius and complexus muscles.

The *foramen magnum*[5] is oval, its antero-posterior diameter being the largest; it transmits the medulla oblongata, spinal accessory nerves, and vertebral artery. On either side of the foramen is the *condyloid process*,[6] an oblong convex surface converging towards its fellow, and articulating with the atlas. It is frequently divided by a ridge or groove, especially in the young African head. The *anterior condyloid foramen*[8] transmits the hypoglossal or ninth nerve, the *posterior condyloid foramen*[7] a vein to the lateral sinus.

In front of the foramen magnum is the *basilar process*,[11] the extremity of which articulates with the sphenoid; the inferior surface receives the insertion of the recti postici and superior constrictor muscle of the pharynx; the superior surface is concave and contains the medulla oblongata.

Fig. 10.

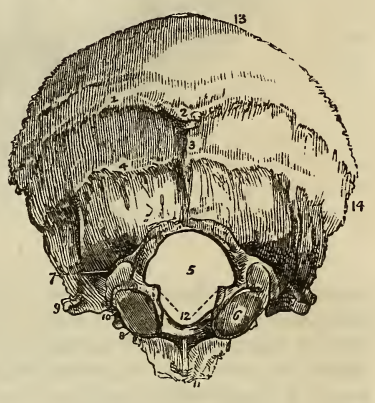

The *internal surface* is concave and about its middle has an *internal occipital* cross, which is more prominent than the external; from it there diverge three grooves, containing the two lateral and the superior longitudinal sinuses; inferiorly there proceeds a ridge to the foramen magnum to which is attached the falx cerebelli. The concavity is thus divided into four smaller ones; the two superior, containing the posterior lobes of the cerebrum, and the two inferior the hemispheres or lobes of the cerebellum.

The two superior edges are deeply dentated and articulate with the parietal; the two inferior articulate with the temporal. On each inferior edge is a prominence called the *jugular eminence*,[9] in front of which is a fossa converted into the *posterior foramen lacrum*[10] by articulation with the temporal, through which pass the internal jugular vein and the eighth pair of nerves. Upon the inferior surface of this eminence is inserted the rectus capitis lateralis.

SPHENOID.

Situated in the middle and anterior part of the base of the cranium. The shape resembles a bat; consists of a body and four wings; a large and small one being placed on each side, besides two vertical processes directed downwards.

The *body* is in the centre and cuboidal in its shape. On its *superior* surface is a deep pit called *sella turcica*,[16] which contains the pituitary gland. This depression is overhung posteriorly by the *posterior clinoid process*;[6] on either side are two grooves called *sulci carotici*, for the carotid arteries, and in front there is a prominence called *processus olivaris*, upon which is a transverse groove indicating the position of the chiasm of the optic nerves.

On the anterior view of the body are the orifices of the two sphenoidal cells, separated by a ridge, upon which articulates the nasal

Fig. 11.

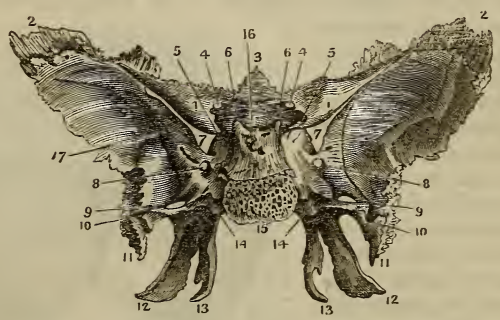

lamella of the ethmoid bone; they empty into the posterior ethmoidal cells, and do not exist in infancy. The inferior surface of the body has an elevation in the median line called the *processus azygos*, by which it articulates with the vomer. Posteriorly, the surface is rough for articulating with the cuneiform process of the occipital bone.

The *small wings*[1] are placed in front of the large. They are triangular, flat, and narrow. Their posterior extremities constitute the anterior clinoid processes, which are perforated by the *optic foramina*,[4] through which pass the optic nerves and ophthalmic artery. They articulate in front with the frontal bone.

The great wings are separated from the small by the *sphenoidal fissure* or *foramen*,[7] which transmits the third, fourth, first branch of the fifth, and the sixth nerves.

This wing has three surfaces. The *cerebral* is concave and has numerous depressions for the convolutions of the middle lobe of the

cerebrum which lodges in this concavity. It has three foramina. The foramen *rotundum*[8] transmits the second branch of the fifth pair. Behind it, is the *foramen ovale*,[9] through which passes the third branch of the fifth pair. The posterior angle of this surface is the spinous process, which is perforated by the *foramen spinale*,[10] by which the middle artery of the dura mater enters the cranium. Projecting from the inferior surface of this process is another called *styloid*,[11] which gives origin to muscles.

The external surface is the *temporal*, which is divided by a ridge, and has a process in front; it is covered by the temporal and external pterygoid muscles. The *anterior* surface is called the *orbital*, forming a large portion of the orbit of the eye. On the superior surface is a large, triangular, serrated surface, for articulating with the frontal bone; laterally it articulates with the temporal.

Pterygoid processes.—These project downwards on either side in a line parallel to the facial line, and articulate with the palate bones in front. Posteriorly, there is a fossa called pterygoid, which terminates in a notch, and divides the process into an *external* and *internal plate*. The *external*[12] is the broader, and gives origin to the external pterygoid muscle; the *internal*[13] is the longer, and terminates in a hook-like process, called the *hamulus*, over which plays the tendon of the circumflexus palati muscle. The internal plate gives origin to the internal pterygoid muscle, which occupies a portion of the fossa.

The internal surface of the base of the pterygoid process has a groove upon it, showing the course and connexion of the cartilaginous portion of the Eustachian tube. The *pterygoid foramen*[14] perforates the base of the process, and transmits the vidian or recurrent nerve.

TEMPORAL BONES.

These are placed on either side of the cranium below the parietal bone. They consist of three portions, squamous, petrous, and mastoid.

The *squamous*[1] is thin and shell-like. Its *external* surface is slightly convex, has grooves for the deep temporal artery, and is covered by the temporal muscle. Projecting anteriorly from the lower part of this surface is the *zygomatic process*,[6] which forms a part of the zygomatic arch. The base of this process is triangular, and has beneath it a cavity called glenoid for the articulation of the lower jaw. This cavity is separated by the Glaserian fissure from another behind it, containing a portion of the parotid gland. Through this fissure pass the chorda tympani nerve and the laxator tympani muscle, attached to the processus gracilis of the malleus. The *internal surface* has a distinct groove[4] for the middle artery of the dura mater. The edge is thin and cutting and has flat serrations[5] for the parietal bone.

The *mastoid*[2] portion is behind, and nipple-like. It is thick and cellular; the cells being lined by a thin membrane. Externally it is rough, and has a large *process* called *mastoid*, upon which are inserted the sterno-cleido-mastoid and trachelo-mastoid muscles. Beneath this process is the *digastric fossa*,[7] which gives origin to the digastric muscle. Internally is a deep sulcus[8] containing a part of the lateral sinus. The edges are thick and dentate. Near the upper edge is the mastoid foramen,[2] which transmits a vein.

Fig. 12.

The *petrous*[3] portion is pyramidal and directed obliquely forwards and inwards. Its structure is extremely dense.

The *base* has a large oval opening externally, between the zygomatic and mastoid, called the *external meatus*, which is surrounded by a rim called the *auditory* process, to which is attached the cartilaginous portion of the ear. In the fœtus it is a ring. The *apex* is obtuse and is perforated by the carotid canal. In the angle between the apex and the squamous portion, is the bony portion of the Eustachian tube, and above it a canal for the tensor tympani muscle.

The *inferior surface* presents a large process, *styloid*,[14] projecting from a ridge called *vaginal process*. Behind it, is the *stylo-mastoid foramen*,[15] the orifice of the Fallopian canal, which transmits the facial nerve and stylo-mastoid artery. Inwards from the styloid process is the *jugular* fossa, which is converted into the posterior foramen lacerum by the articulation of the occipital bone; this foramen transmits the internal jugular vein and the eighth pair of nerves. The *tympanic canal*, containing Jacobson's nerve, opens in this fossa; its other orifice is near that of the Eustachian tube. In front of the jugular fossa is the commencement of the *carotid canal*,[16] which contains the carotid artery and the ganglion of Laumonier. Upon the septum between the jugular fossa and carotid canal, is the entrance to the *aqueduct of the cochlea*.

The anterior surface presents a groove leading to a foramen called hiatus Fallopii, which transmits the superficial petrous nerve, a branch of the vidian; behind this is the *eminentia arcuata*, made by the prominence of the labyrinth. At the internal edge is a groove for the superior petrosal sinus, and near the apex a semilunar depression for the ganglion of Casser.

The *posterior* surface has a large opening near the middle, *internal meatus auditorius;* it is not deep, and the base is cribriform. Immediately above it is a foramen or fissure for the attachment of the dura mater and a small vessel; behind it is a ridge produced by the inferior semicircular canal, and half an inch behind it is the aqueduct of the vestibule, concealed by an osseous lamella.

ETHMOID.

Is so called from its resemblance to a sieve. It is placed in the median line, at the base of the skull, in front of the sphenoid bone, and between the orbitar processes of the frontal. Is cuboidal in shape and cellular in structure.

The *superior* surface is called the *cribriform plate,*[4] which is perforated with holes for the transmission of filaments of the olfactory nerve; the most anterior hole is the largest, and transmits the internal nasal nerve. From the median line is a narrow, triangular, hollow process called the *crista galli,*[3] and to it is attached the falx cerebri. In front of this is sometimes the foramen or groove called foramen cæcum, which admits of the passage of a small vein from the nose.

The bone is divided longitudinally into two halves by the vertical plate of bone called the *nasal lamella;*[1] this can best be seen by examining the inferior surface. It articulates below with the vomer, and behind with the crista sphenoidalis.

The *lateral surfaces* of the bone are called the *ossa plana.* The os planum is extremely thin and papyraceous, forming a large part of the orbit of the eye. On its upper edge are two grooves, which are converted into two *foramina,* called *internal orbitary* or *ethmoidal;* the anterior transmits an artery, vein, and the internal nasal nerve; and the posterior transmits an artery and vein. The inferior edge articulates with the superior maxillary bone. When the bone is viewed from behind there will be seen two scrolls or shells on either side of the nasal lamella, but attached to the internal face of the os planum. They are the *superior*[6] and *middle turbinated bones,*[7] placed one above the other, and separated by a fissure. This fissure is the *superior meatus*[5] of the nose. The middle meatus is a space observed in an articulated head between the middle and inferior turbinated bones. The anterior cells of the ethmoid bone empty into the middle meatus; the most anterior of these cells is funnel-shaped (*infundulum*), and receives the fluid from the frontal sinus; from the

Fig. 13.

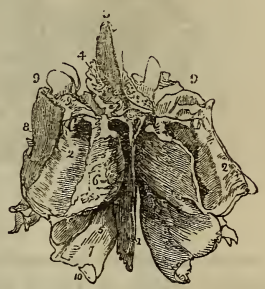

inferior part of these cells there proceeds a hook-like process. The posterior ethmoidal cells and the sphenoidal sinus empty in the superior meatus.

In children there is attached to the ethmoid bone, on each side, a hollow triangular process, called the pyramid of Wistar, or cornu Bertini. The base is connected with the superior turbinated bone, the posterior edge of the cribriform plate, and the posterior edge of nasal lamella. The apex lies under the body of the sphenoid bone, on each side of the processus azygos. These pyramids are detached from the ethmoid in after life, and become the sphenoidal sinuses.

The ethmoid articulates with the frontal, sphenoid, inferior turbinate, upper jaw, nasal, lachrymal, palate bones, and vomer.

BONES OF THE FACE.

These are fourteen in number, and exist in pairs with the exception of two, the lower jaw and the vomer.

SUPERIOR MAXILLARY BONE.

This with its fellow constitutes the upper jaw. It articulates with all the bones of the face with the exception of the lower jaw. It has an irregular cubical body and four processes. The *body* is hollow and has four surfaces.

Fig. 14.

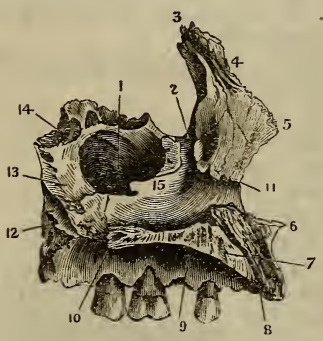

The anterior or *facial* surface is bounded above by the inferior margin of the orbit, beneath which is the *infra-orbital foramen*, transmitting the infra-orbital nerve, artery, and vein. Contiguous to this foramen is a depression, called the canine fossa, which gives origin to the levator anguli oris muscle. The posterior or *temporal* surface is rounded. The most prominent part is called the *tuber*,[12] which is rough and perforated by several small foramina which transmit the posterior dental nerve, artery, and vein, to the floor of the antrum.

The superior or *orbital surface* is triangular, and traversed by the infra-orbital groove leading to the foramen of that name. Upon the internal or *nasal surface* is the large opening of the *antrum Highmorianum*,[1] which is a pyramidal cavity with thin walls; the walls are grooved, indicating the passage of the anterior and pos-

terior dental nerves. The opening is diminished by the articulation of the palate, inferior turbinate, and unguiform bones, to a small orifice which opens into the middle meatus of the nose.

The *nasal process*[4] arises from the superior and anterior part of the bone. It is broad and thin below; externally it gives origin to the levator labii superioris alæque nasi muscle, internally it has a transverse ridge dividing the surface unequally for the inferior turbinated bone. The anterior edge articulates with the nasal bone, the superior with the frontal, and the posterior edge has a deep groove, which is converted into a bony canal for the lachrymal sac by the articulation of the os unguis.

The *malar process* is a rough process upon the external and superior part of the bone for articulation with the malar bone.

The *alveolar process* contains the sockets for eight teeth.

The *palate process*[7] is the horizontal roof of the mouth and floor of the nose; uniting behind with the horizontal part of the palate bone,[10] and on the side with its fellow, from which latter junction or suture there arises the *nasal crista*, for the articulation of the vomer. The anterior extremity[6] is the anterior nasal spine. Immediately behind this is the *foramen incisivum* for the naso-palatine nerve and ganglion of Cloquet.

PALATE BONE.

Situated on each side between the superior maxillary and the sphenoid bone; the figure is irregular and consists of three parts.

The *horizontal* part[1] is quadrilateral in its shape and assists in forming the floor of the nostril and roof of the mouth. The suture between it and its fellow forms a part of the nasal crista for the articulation of the vomer, and posteriorly is elongated into the posterior nasal spine; from which arises the azygos uvulæ muscle.

The ascending or *vertical portion*[2] is divided on its internal or nasal face by a ridge,[6] for the articulation of the inferior turbinated bone; externally it has a rough articular surface for the superior maxillary bone; upon this surface is a groove, converted into the posterior palatine foramen or canal by this articulation, which transmits the palatine nerve and artery. Posteriorly there is an elongated triangular process called *pterygoid;*[3] this process has three grooves, the middle of which forms a part of the pterygoid fossa, and those on each side receive the external[10] and internal[11] plates of the pterygoid process of the sphenoid.

Fig. 15.

The upper extremity of this vertical or nasal portion is formed by two processes separated by a notch which is converted into a

foramen, called spheno-palatine,[7] by articulation with the sphenoid bone, and transmits the spheno-palatine artery and nerve. The anterior process is called *orbital*,[8] forming a small part of the orbit between the ethmoid and superior maxillary. The posterior is the *pterygoid apophysis*;[9] it is extremely thin, inclines inwards and fits upon the base of the body of the sphenoid.

Fig. 16.

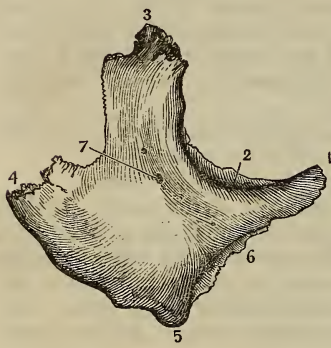

MALAR BONE.

Is quadrangular in shape, and forms the prominence of the cheek. It consists of a body and processes. The *body* has three surfaces, the external or facial of which, has numerous small perforations for arteries[7] and nerves; the internal or orbital is smooth and has a notch which limits the spheno-maxillary fissure or foramen lacerum inferius of the orbit; the posterior forms the anterior boundary of the temporal or zygomatic fossa.

The *superior process* is the *frontal*,[3] for articulating with the external angular process of the frontal bone. The *temporal process*[4] projects backwards to unite in forming the zygomatic arch. The *maxillary*[5] [6] is triangular and rough, for articulating with the malar process of the superior maxillary bone. The bone has four edges. The superior[2] is curved and continuous with the orbital ridge, the inferior gives origin to the zygomatic and masseter muscles, the anterior articulates with the superior maxillary, and the posterior has the temporal fascia connected with it.

The malar bone sometimes contains a cavity called the sinus jugalis, especially in Mongolians and Malays.

NASAL BONE.

These bones unite with each other[2] and are placed between the nasal processes of the superior maxillary bones. The shape is a long quadrangle, but in Africans it is frequently triangular. The superior extremity is narrow and thick, articulating with the frontal bone. The inferior is thinner and broader, having the cartilage of the nose attached; the internal edge articulates with its fellow, and the external has a spiral groove, whereby it is overlapped by the nasal process of the superior maxillary above, and overlaps the process below. The anterior surface has numerous foramina for nutritious vessels; the posterior contains a groove for the internal nasal nerve.

UNGUIFORM BONE.

This is so called from its resemblance to a finger nail (unguis): it is also called lachrymal. It is quadrangular, flat, and small, extremely thin and often cribriform. The external surface[1] forms a portion of the orbit of the eye, and has a groove in front,[2] which completes the canal for the lachrymal sac. From its inferior edge there projects a triangular process[7] which articulates with inferior turbinated bone. The edges[4 5 6] articulate with the frontal, ethmoid, and superior maxillary bones.

Fig. 17.

INFERIOR TURBINATED BONE.

This is a porous scroll, placed at the inferior part of the nasal cavity below the ethmoid. Its posterior end is the more pointed. Its *internal surface* is convex and looks towards the nose; the *external surface* has a broad hook, processus maxillaris,[3] which enters the antrum Highmorianum, and partly closes it. The superior edge has a triangular process called *lachrymal*, which articulates with the unguis. The portions of the edge in front of and behind this process rest upon ridges of the nasal process of the superior maxillary and palate bones; there is frequently a process upon this edge which unites it with the ethmoid bone.

VOMER.

A single bone, forming a large portion of the nasal septum, consisting of two plates of compact structure. It is a flat bone with four edges. The superior is the thickest, having a deep groove between two lips (alæ) for the reception of the processus azygos of the sphenoid. The inferior edge is the longest, articulating with the nasal crista of the palate suture. The anterior unites with the nasal lamella of the ethmoid, and the posterior is thin, sharp, and concave, separating the posterior openings of the nose.

INFERIOR MAXILLARY.

Is also single, having a parabolic curve; placed at the inferior portion of the face. It consists of a body and two rami. The body is convex in front and presents in its middle the *anterior mental tubercle* or spine, which in youthful life is a suture. On either side of this is a large hole, called the anterior mental[5] foramen, transmitting a part of the inferior alveolar artery and nerve. The portion of the bone between these two foramina is called the chin. The posterior surface of the chin is concave and has the posterior mental tubercle in its middle, upon which are two marks on each side, for the genio-hyoglossus and genio-hyoid muscles; on either side of

this tubercle or spine is a fossa for the insertion of the digastricus. Extending backwards from this tubercle, is a ridge[9] called mylo-hyoid, for the muscle of that name; above this ridge is a shallow fossa for the sublingual gland; below it and behind, is a larger one for the submaxillary gland. The *alveolar process*, contains sockets for sixteen teeth. The inferior edge is the *base*, which is thicker in front, and has two corners giving a squareness to the chin.

Fig. 18.

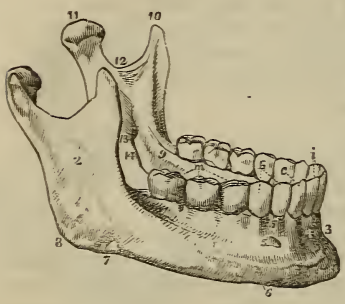

The ramus[2] is square, and at right angles to the body in manhood; in youth and old age it is oblique; externally it is rough for the masseter muscle, anterior to which is a groove for the facial artery.[7] The internal face has a posterior mental foramen,[13] for the entrance of the inferior alveolar artery and nerve. To the edge of this foramen is attached the internal lateral ligament; near it is a groove[14] transmitting the mylo-hyoidean nerve; below, is the surface for the insertion of the internal pterygoid muscle. The angle[8] is rough, and has attached to it the stylo-maxillary ligament. The anterior edge of the ramus is continued into the external oblique ridge.[6]

The superior part of the ramus has two processes separated by[12] the sigmoid notch. The *coronoid* process is in front,[10] and is triangular and thin; it has inserted into its apex the temporal muscle; in front there is a groove for the buccinator muscle. The posterior is the condyle[11] articulating in the glenoid cavity of the temporal bone. The neck is narrow, and on the inside of it is a fossa for the insertion of the external pterygoid muscle.

OF THE HEAD IN GENERAL.

Sutures.—The principal sutures of the head are the *coronal*, which unites the parietal and frontal bones; the *saggital*, which unites the two parietal bones in the adult, and in a child extends to the root of the nose; the *occipital*, which joins the parietal and occipital bones; and the *squamous*, uniting the squamous part of the temporal and the parietal bones. Besides these there are others uniting the bones of the face. That part of the suture between the mastoid and parietal bones, is called additamentum suturæ squamosæ; and that suture between the mastoid and occipital, is called additamentum suturæ occipitalis.

Fontanels.—These are the deficiencies in ossification in the bones

of the fœtal head. The *anterior* is large and quadrangular, situated at the junction of the coronal and saggital sutures. The anterior angle is the most elongated. The *posterior* is small and triangular, and situated at the junction of the lambdoidal and sagittal sutures. Besides these there are two smaller fontanels on either side; one is in the angle of the temporal, parietal, and occipital bones, and the other is at the junction of the temporal, parietal, and sphenoid bones.

Ossa Wormiana or *Triquetra*, are small bones, irregular in shape and number, sometimes found in the sutures, particularly about the middle of the lambdoidal. They have a distinct point of ossification.

The *diploe* is the cellular bony structure between the external and internal or vitreous tables; it is traversed by channels lined by a venous lining which empty partly into the sinuses of the dura mater and partly into the emissaries of Santorini.

The *cavity of the cranium* is about six and a half inches in length, five in breadth and five in height. When the calvaria or arch of the cranium is removed, three deep fossæ are observed at the base on each side. The anterior is formed by the frontal, sphenoid, and ethmoid bones, and contains the anterior lobes of the brain; the middle is formed by the sphenoid and temporal bones, and lodges the middle lobe; the posterior is formed by the occipital and temporal bones, and contains the cerebellum.

Orbital cavity.—Is formed on each side by seven bones.

The cavity is conical, the apex being formed by the optic foramen; the base looks outwards and is somewhat quadrangular. The sphenoidal foramen or fissure opens into the orbit, and is also called *foramen lacerum superius;* another slit or fissure between the sphenoid and maxillary bones being the *foramen lacerum inferius.* Besides these there are other openings into the orbit already mentioned in the description of each bone.

Nasal Cavity.—This is an irregular cavity, separated from its fellow by the nasal septum. It has three distinct passages or *meatuses.* The *superior* is between the superior and middle turbinated bones, and has opening into it the posterior ethmoidal cells, the sphenoidal cells, and the spheno-palatine foramen; the middle is between the middle and inferior turbinated bones, and has opening into it the frontal sinus, anterior ethmoidal cells, and the antrum, usually. The inferior is the largest, and between the inferior turbinated bone and the floor of the cavity; into it opens the nasal duct. The opening into the nasal cavity in front is called the *anterior nares;* the opening behind *posterior nares.*

Zygomatic fossa, also called temporal, is the large fossa on either side of the head, formed by the parietal, sphenoid, temporal, and frontal bones, and bounded externally by the zygoma. The temporal muscle occupies nearly the whole.

Pterygo-Maxillary Fossa or Fissure.—This is at the bottom of the zygomatic fossa, and formed by the sphenoid, palate, and superior maxillary bones. It is triangular, and the base is upwards. The ganglion of Meckel is contained in it, which gives off branches going through the foramina which open upon this fossa. It is continuous with the foramen lacerum inferius or spheno-maxillary slit.

Facial Angle.—This is formed by drawing a straight line from the lower part of the frontal bone to the anterior nasal spine, and intersecting it at this latter point by another drawn through the external meatus auditorius. It establishes a relation between the cranium and the face. The smaller the angle the more inferior is the conformation. By comparing the heads of the great races of the world, it is found to be 80° to 85° in Europeans, 75° in the copper-coloured or Mongolians, and 70° in Negroes.

In the African head these additional peculiarities will frequently be found. The temporal fossa is large, and the temporal ridges are nearly approximated.

The pterygoid processes of the sphenoid project in a line parallel with the facial line and thereby alter the shape of the posterior nares.

The condyloid processes of the occiput are often divided into two portions by a ridge or groove.

The lower boundary of the anterior nares is deficient in a sharp ridge which characterizes the Caucasian head. In these peculiar features the African adult head seems permanently to retain marks which are generally found to belong to the fœtal head.

HYOID BONE.

This bone is situated in the neck and connected with the root of the tongue and upper part of the larynx. It is shaped like the Greek *υ*, the convexity being in front. It does not articulate with any other bone. It consists of a body and four cornua. The *body*[1] is quadrilateral, convex in front, and concave behind. The front surface gives origin and insertion to muscles of the neck, and has a well-marked projection. The *greater cornua*[2] are about an inch in length, and in early life united to the body by means of cartilage and ligaments; they are flattened, project backwards, and terminate in a head or tubercle. They give origin and insertion to muscles of the neck. The *lesser cornua*,[3] are attached at the junction of the body and great cornua; they are cartilaginous usually, and of a few lines in length. To them are attached the stylo-hyoid ligaments.

Fig. 19.

UPPER EXTREMITY.

The upper extremity is divided into the shoulder, arm, forearm, and hand.

The shoulder consists of two bones, the scapula and the clavicle.

Scapula.—The shoulder blade of common language. Placed on the back part of the thorax between the second and seventh ribs. It is thin, flat, and triangular; has two surfaces, three edges, and three angles.

The *anterior face* is a concavity called *costa* or venter, divided by ridges, and giving origin to the subscapular muscle. The posterior face is the *dorsum*, divided by the spine into two fossæ; the fossa supra-spinata,[1] giving origin to the supra-spinatus muscle, and the fossa infra-spinata,[2] giving origin to the infra-spinatus muscle.

The spine[10] is a rough ridge running obliquely across the dorsum, and terminating in the acromion process. The edge of the spine gives origin to the deltoid, and insertion to the trapezius muscles; near the base of the scapula the spine has a small triangular surface,[11] over which plays the trapezius tendon. The acromion process is flat and triangular, has a small articular mark[12] in front for articulation with the clavicle.

Internal edge or base.—Is the longest, and nearly parallel[9] with the vertebral column; has an external lip for the insertion of the rhomboid muscles, and an internal one for the serratus anticus.

External edge.—Is thick,[5] and contains a *fossa* giving origin to the teres minor muscle. At the upper part of this fossa is a rough mark for the origin[8] of the long head of the triceps.

Fig. 20.

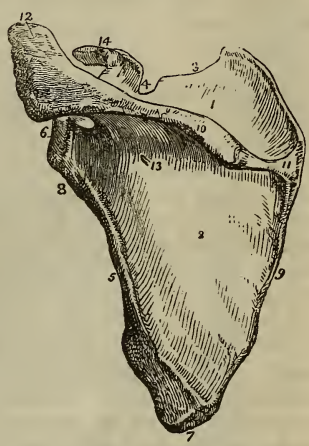

Superior edge. — Is thin and small,[3] and has a notch called coracoid,[4] which is converted into a foramen by a ligament, and transmits the supra-scapular artery and nerve. Near this notch arises the omo-hyoid muscle.

Superior angle.—Almost a right angle, and has the levator anguli muscle inserted into it.

Inferior angle.—Is the most pointed,[7] and gives origin by its posterior surface to the teres major muscle, and is connected with the latissimus dorsi.

External angle.—Presents a large articular cavity,[6] called *glenoid*, upon

a narrow neck. This cavity is oval and shallow; and at its summit is a mark showing the origin of the long head of the biceps muscle.

Coracoid process.—This projects forwards and outwards from the neck,[14] in a curved manner. Its tip has marks for the insertion of the pectoralis minor and also for the origin of short head of the biceps and coraco-brachialis. Its base has a tubercle to which is attached the conoid ligament.

CLAVICLE.

A long bone placed transversely at the upper and anterior part of the thorax, resembling in shape the italic *f*. It articulates with the sternum and scapula. The sternal two-thirds is convex anteriorly, and the humeral third concave anteriorly. The upper surface has a depression near the sternal extremity, showing the origin of the sterno-cleido-mastoid muscle. The inferior surface has a roughness near the sternal extremity for the rhomboid or costo-clavicular ligament, and near the humeral extremity a tubercle and ridge for the coraco-clavicular ligament; the space between these two marks is for the insertion of the subclavius muscle. The *anterior edge* gives origin by its sternal two-thirds to the pectoralis major, and by its humeral third to the deltoid. The *posterior* edge has a foramen for the nutritious artery.

The *sternal extremity* is thick and triangular, with a surface for articulation with the sternum; the posterior and inferior corner of it is elongated, which contributes to the strength of the articulation. The *humeral* extremity is flat and spongy, with an articular face for the acromion process of the scapula.

In the male the bone is shorter, thicker, and more curved than in the female.

HUMERUS.

The arm-bone is cylindrical, and reaches from the shoulder to the elbow. The superior extremity presents a hemispherical *head*[2] for articulation with the glenoid cavity of the scapula, separated by a deep groove, the *anatomical neck*,[3] from the shaft of the bone. Below this groove are two tuberosities; the greater,[4] is the external, and has three facets for the insertion of the supra and infra-spinatus, and teres minor muscles; the lesser, on the inner side,[5] is for the insertion of the subscapularis. These tuberosities are separated from each other by a groove,[6] called *bicipital*, in which plays the tendon of the long head of the biceps muscle. The anterior or *external edge*[7] of this groove has the pectoralis major muscle inserted into it, and the posterior[8] or internal edge, receives the latissimus and teres major muscles. The *surgical neck* is between the insertion of these muscles and the anatomical neck of the humerus. About the middle of the shaft, and upon its outer side, is a triangular roughness[9]

for the insertion of the deltoid; on the inner side and a little below is a ridge for the insertion of the coraco-brachialis:[10] below this ridge is the nutritious foramen, and above it is a shallow spiral groove for the musculo-spiral nerve and profunda major artery.

Fig. 21.

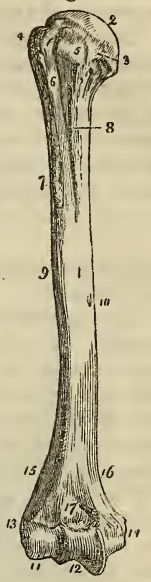

The inferior extremity is flat and broad; anteriorly it is covered by the brachialis anticus muscle, and posteriorly by the triceps. Externally, there is a ridge[15] leading to the *external condyle*,[13] from which arise the supinator and extensor muscles. Internally a ridge[16] leads to the *internal condyle*,[14] which is more prominent than the external, and from which arise the flexor muscles of the forearm and the pronator radii teres.

The articular surface at the elbow consists of a hemispherical head[11] for the radius, and an irregular cylinder[12] for the ulna. Above this articular surface, and in front, is a fossa,[17] called the *lesser sigmoid cavity*, which receives the coronoid process of the ulna in extreme flexion; behind is a larger fossa, the greater sigmoid, for the olecranon in extreme extension. Sometimes these fossæ are connected by an opening.

ULNA.

Fig. 22.

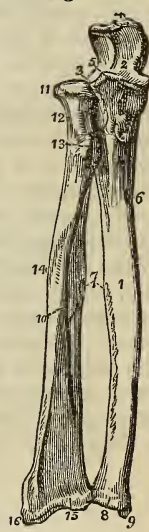

The forearm consists of two bones—Radius and Ulna.

The Ulna is the longer, and is placed on the inner side, reaching from the elbow to the wrist.

The upper extremity is the larger, and has a hook-like process behind,[4] called *olecranon*, to which is inserted the triceps extensor cubiti. In front, is the *coronoid process*,[5] the base of which has a roughness for the insertion of the brachialis anticus muscle. Between the olecranon and coronoid processes, is the greater sigmoid cavity,[2] for articulation with the humerus: continuous with this is the lesser sigmoid cavity,[3] upon the outside of the coronoid process, for the articulation of the head of the radius. Behind the lesser sigmoid cavity, is a triangular, uneven surface, for the insertion of the anconeus muscle. This surface is limited by a ridge giving origin to the supinator radii brevis muscle.

The *body* is prismatic; the anterior surface[1] is occupied in its upper three-fourths by the flexor profundus, and in the lowest fourth, by the pro-

nator quadratus muscle. The posterior surface is occupied by the extensors of the thumb and the indicator muscle.

The external edge[7] is the sharpest, and to it is attached the interosseous ligament.

The lower extremity has a small rounded head,[8] the outer side of which has a smooth articular surface for the radius. From the inner side, there projects[9] the *styloid process*, to which is attached the internal lateral ligament; behind this process is a groove, in which glides the tendon of the extensor carpi ulnaris muscle.

RADIUS.

It is placed on the outer side of the ulna, and is slightly curved and prismatic.

The *superior extremity* has a rounded *head*,[11] the rim of which is smooth. The internal part plays in the lesser sigmoid cavity. The upper surface of the head has a cup-like depression for articulation with the humerus. Beneath the head is the *neck*,[12] the narrowest part of the bone. Below the neck, and on the inner side, is the *tubercle*,[13] rough below and smooth above, for the insertion of the biceps muscle.

The body is prismatic; *anteriorly*, the surface gradually increases in breadth,[10] giving origin to the flexor longus pollicis, and receiving the insertion of the pronator quadratus muscle. The *posterior surface* is occupied by the extensor major of the thumb and the indicator muscles. The *external surface* is curved, and has a roughness about the middle for the insertion of the pronator radii teres muscle, above which and below the tubercle is the space occupied by the insertion of the supinator radii brevis muscle.

The *inferior extremity* is thick and triangular. The surface of the extremity[15] is concave and divided by a ridge. It articulates with the scaphoid and lunare. Continuous with this articular surface, is a smaller one on the internal aspect of the extremity for the articulation of the ulna. Externally there is a *styloid process*,[16] for the attachment of the external lateral ligament.

Near a ridge which terminates in the styloid process, is inserted the supinator radii longus. Upon the dorsal view of this extremity of the bone, are three large grooves, each divided into smaller ones. The groove near the supinator ridge transmits the tendons of the extensor ossis metacarpi pollicis and the extensor minor pollicis; the groove in the middle is the broadest and most shallow, transmitting the tendons of the radial extensors; and the groove nearest the ulna transmits the tendons of the extensor communis, indicator, and extensor major pollicis. The portion of the groove occupied by the latter is very deep.

HAND.

The hand consists of the carpus, metacarpus, and digiti.

The CARPUS or wrist is oblong, the greatest diameter being transverse. The dorsal surface is convex, and the palmar surface is concave, with four prominences. This concavity transmits the flexor tendons.

It consists of *eight* bones arrayed in two rows. The bones of the *superior* row are the *scaphoid, lunare, cuneiform,* and *pisiform.* Those of the inferior row are the *trapezium, trapezoides, magnum,* and *unciform.*

Scaphoid, is on the radial side, and resembles a boat; has a large convex surface superiorly for the radius, and inferiorly a deep concavity for the magnum. It articulates in front with the trapezium and trapezoides, and on the inside with the lunare.

Fig. 23.

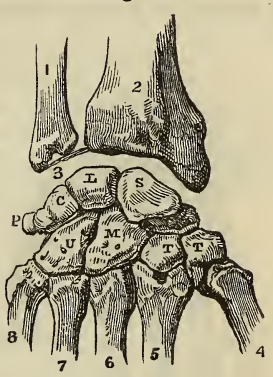

Lunare, of a crescentic figure, has a convex surface superiorly for the radius, and a concavity in front for the magnum, articulates on the inside with the cuneiform.

Cuneiform.—Wedge-shaped, or pyramidal. Inferiorly it articulates with the unciform. Distinguished by a circular facet on its palmar surface for the pisiform.

Pisiform.—Pea-like bone, forms one of the prominences in the palm of the hand, has the flexor carpi ulnaris muscle inserted into it, and has but one articular mark, which is for the cuneiform. It is the smallest bone of the carpus.

Trapezium, has the most numerous surfaces and angles. The largest articular surface is for the thumb; two others, joining each other, are for the scaphoid and trapezoides. On the palmar surface is a ridge and a deep groove for the flexor carpi radialis tendon.

Trapezoides, is the smallest bone of this row. It is a four-sided pyramid with its apex towards the palm; its dorsal surface is the base and inclines inwards.

Magnum.—The largest bone of the wrist. Has a rounded head looking backwards; the body is quadrilateral.

Unciform.—Distinguished by a hook-like process, resembling a nail, on its palmar surface, which gives origin to the flexor brevis minimi digiti.

METACARPUS.

Consists of five bones, each having a head, shaft, and base.

The *head* is rounded, articulating with the first phalanx; a roughness on each side indicates the attachment of the lateral ligament.

The *base* is the superior extremity, rough, and quadrilateral, having articular marks on the extremity and either side.

The *body* or *shaft* is prismoid, having impressions on its sides for the interossei muscles.

The *first* is short and thick, and belongs to the thumb. Its base has but one articular surface, and that is for the trapezium. Its head is not very spherical, and its palmar surface articulates with the sesamoid bones.

The *second* is the longest, and belongs to the index finger; it has a *notch* at its base for articulating with the trapezoid; and a lateral articular mark upon one side only: a mark upon its dorsal surface indicates the insertion of the extensor carpi radialis longior.

Fig. 24.

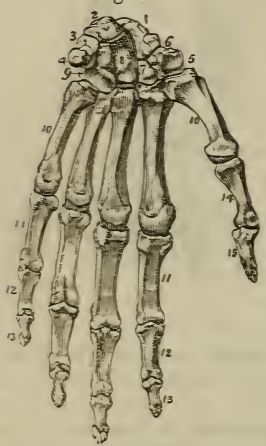

The *third* has a *triangular* base with an articular mark on each side, and on its dorsum one for the extensor carpi radialis brevior.

The *fourth* is much smaller. The external lateral surface of its base is double.

The *fifth* is the smallest. Its base has but one lateral surface, and that is external and single. Internally there is a tubercle at the base for the extensor carpi ulnaris.

FINGERS.

The fingers contain three bones called *phalanges:* the thumb has but two.

First row.—The *phalanges* of this row are the largest, convex on their dorsal, and flat on the palmar surface. The superior extremity has a single concavity for the head of the metacarpal bone. The inferior extremity has two convexities separated by a groove. A roughness on either side of this extremity, indicates the attachment of the lateral ligament. The ridges extending from one extremity to the other are for the theca of the flexor tendons.

Second row.—These are smaller. The superior extremity has two concavities, separated by a ridge; the inferior two convexities, separated by a groove. The ridge on either side of the body has the theca and tendon of the flexor sublimis attached to it.

Third row.—These are the smallest, and differ much from the

other rows, having but one articular extremity, which is the superior, having two concavities and a ridge. The inferior extremity is flattened, thin, and rough.

The middle finger (*impudicus*) is the longest. The ring finger (*annularis*) is the next in size. The forefinger (*indicator*) is thicker than the last. The little finger (*auricularis*) is the smallest.

Sesamoid bones.—These are four in number—two being placed upon the palmar side of the lower extremity of the metacarpal bone of each thumb, in connexion with the short flexor tendon.

LOWER EXTREMITY.

FEMUR.

The *femur* is the longest bone in the body, reaching from the acetabulum to the knee.

The superior extremity presents a spherical *head*,[2] which has a depression upon it for the ligamentum teres. The part between the head and shaft is the *neck*,[3] which is shorter and more horizontal in old persons and in females. Externally is the *trochanter major*, a large process having an oval mark in front for the gluteus minimus; and above a double mark for the gluteus medius; the tip has the pyriformis inserted into it, and behind the tip is the *digital fossa*, into which are inserted the gemelli and obturator muscles. Below and on the inner side is the *lesser trochanter*, into which is inserted the psoas magnus, and iliacus internus muscles. A ridge between the trochanters behind, indicates the insertion of the quadratus femoris, and a corresponding one in front[5], which is less distinct, serves for the connexion of the capsular ligament.

Fig. 25.

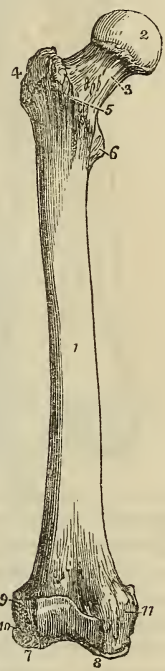

The *inferior extremity* is broader than the upper, and is divided by a fossa in front, and a notch behind, into two *condyles*. The *internal* condyle seems to be much the longer,[8] and is in reality somewhat so; its internal surface[11] gives origin to the internal lateral ligament and its posterior to the gastrocnemius muscle; its external surface assists in forming the notch, and has a roughness in front for the posterior crucial ligament.

The *external condyle* contributes by its internal surface to form the notch, and has a roughness behind for the anterior crucial ligament. Its posterior surface gives origin to the popliteus, plantaris, and gastrocnemius muscles, and its external to the external lateral ligament. The *fossa* in front, is unequally

divided between the condyles, the larger and flatter portion belonging to the external. In this fossa plays the patella.

The shaft of the bone is curved *anteriorly*, and is covered in front by the origin of cruræus muscle. Posteriorly there is a rough ridge called *linea aspera* (Fig. 26), which consists of two lips having a tendency to separate above and below. The inner lip shows the insertion of the pectineus muscle,[p] of the adductor brevis,[ab] and of the adductor magnus.[am] This last insertion occupies this inner lip in nearly its whole length; so also does the origin of the vastus internus. The outer lip has inserted into it the gluteus maximus,[gm] and also gives origin to the vastus externus, and the short head of the biceps flexor cruris.[b]

Fig. 26.

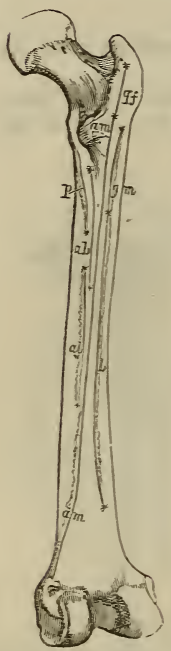

PATELLA.

The patella is the largest sesamoid bone in the body, and commonly called the knee-pan. It is flat and triangular; thick and broad above, and thin and pointed below. The *anterior surface* is covered by integument; the *posterior* is a smooth articular surface divided by a ridge unequally—the external portion is the larger and flatter, adapted to a corresponding surface of the femur.

The *superior edge* is thick, and has the tendon of the rectus inserted into it. The inferior is pointed, and to it is attached the ligament of the patella.

TIBIA.

The tibia is longer and thicker than the fibula. It is placed on the inside of the leg, and commonly called the shin-bone. The superior extremity, or *head*, is large and thick, presenting an oval articular surface for the femur. This surface is divided by a pyramidal eminence, the *spinous process*,[4] into two surfaces, both of which are oval, but the internal is longer and deeper; to the base of this spinous process are attached anteriorly and posteriorly the *crucial ligaments;* in a depression upon its summit is fastened the posterior end of the external semilunar cartilage. (Fig. 27.)

An enlargement upon either side of the head are called tuberosities or condyles; upon the posterior part of the *external condyle*[5] is a small articular face, looking downwards, for the head of the fibula; upon the posterior part of the *internal condyle*[2] is a depression for the insertion of the semi-membranosus tendon.

Below the head, and in front, is a prominent *tubercle*[5] for the insertion of the ligament of the patella, and above it a smoothness corresponding with its bursa; below the head, and behind, is a triangular surface,[4] occupied by the poplitæus muscle, limited by an oblique ridge[5] (Fig. 28), which gives origin to the soleus muscle.

The *body* is prismatic. Its internal surface[6] (Fig. 27) is smooth and covered by the skin; the external surface gives origin to the tibialis anticus and extensor communis digitorum; from the posterior surface arise the tibialis posticus and flexor communis digitorum.

The *anterior* edge[1] (Fig. 27) is sharp and superficial, generally curved with some resemblance to the italic *f;* the *external* has a ridge for the attachment of the interosseous ligament, and the *in-*

Fig. 27.

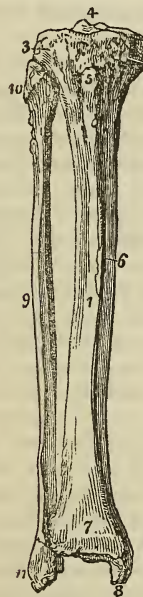

Fig. 28.

ternal is rounded, having the sartorius, gracilis, and semi-tendinosus inserted into it at its upper part.

The inferior extremity is smaller than the superior, and four-sided. Over the *anterior* surface pass the extensor tendons; on the *posterior* is a slight fossa[9] (Fig. 28) for the tendon of the flexor longus pollicis; *externally* there is a rough triangular fossa for the articulation of the fibula; and *internally* there is a large process, called the *internal malleolus*[8] (Fig. 28), behind which is an oblique

fossa, transmitting the tendons of the tibialis posticus and flexor longus digitorum pedis. The inferior extremity of the malleolus is notched for the attachment of the internal lateral ligament; its internal surface is superficial; its external surface is continuous with the quadrangular concavity at the extremity of the bone, for the articulation of the astragalus.

FIBULA.

The fibula is a long thin bone placed upon the outside of the leg, and somewhat posteriorly at the upper part (Fig. 27 [9], Fig. 28 [10]). It is slightly twisted in its appearance, and has a convexity backwards. The superior extremity or head is thick and large, and articulates with the external condyle of the tibia. External to this articular surface, is a mark for the attachment of the external lateral ligament of the knee-joint, terminated behind by a styloid process, for the insertion of the tendon of the biceps.

The body is prismatic, and has three surfaces; the external of which is the broadest, and commencing upon the anterior part of the bone above, winds around it, so as to terminate upon its posterior side below. The upper two-thirds of this surface give origin to the peroneus longus and brevis; the lower third terminates in a groove, which indicates the course of the tendons of these muscles. The internal face looks towards the tibia, and is divided longitudinally by a ridge, to which is attached the interosseous ligament; the space in front of which gives origin to the extensor proprius pollicis, and the extensor communis digitorum; and the space behind gives origin to the tibialis posticus. The posterior surface is also spiral, and gives origin to the soleus, and the flexor longus pollicis muscles.

Fig. 29.

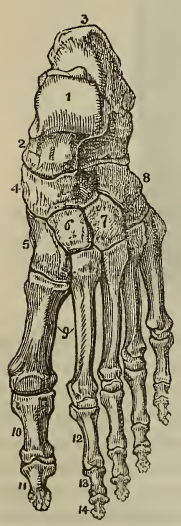

The inferior extremity terminates in the *external malleolus*, which is longer and flatter than the internal. Its external surface is superficial and triangular; its internal has a smooth articular surface for the astragalus. The extremity is pointed, and often called the coronoid process, immediately within which is a rough depression for the external lateral ligament.

FOOT.

It consists of the tarsus, metatarsus, and phalanges. The TARSUS consists of seven bones, viz.: os calcis, astragalus, cuboid, scaphoid, and three cuneiform.

Os Calcis.—This is the largest of the tarsal bones, and constitutes the *heel*. Its figure is longitudinal. *Supe-*

riorly it has two articular surfaces for the astragalus, separated by a deep groove, in which is fastened the interosseous ligament. The posterior portion is convex and the larger of the two. The anterior is narrow, concave, and divided by a small groove into two parts.

The *internal* surface has a deep concavity, called the sinuosity, for the passage of tendons, vessels, and nerves of the sole of the foot. The *external* surface is covered by the skin, and has two grooves for the tendons of the peroneus longus and brevis. The *inferior* surface has two tuberosities behind, of which the internal is the broader and larger; and also one in front. These tuberosities give origin to muscles and ligaments. The *posterior* extremity[3] is rough and prominent in its inferior half, into which is inserted the tendo-achillis; the superior half is smooth, corresponding with the bursa. The *anterior* extremity presents two processes, called the greater and lesser apophyses; the *greater* is external and below, and has a flat triangular articular surface for the cuboid bone, surmounted by a rough projection. The *lesser apophysis* (sustentaculum tali) is a blunt hook projecting forwards and upwards, having an articular concavity above, constituting that portion of the superior surface of the bone, which articulates with the astragalus; upon its inferior surface is a groove for the tendon of the flexor longus pollicis.

Astragalus.[1]—Is next in size to the os calcis. It consists of a body and a head. *Superiorly* the *body* presents a large articular convexity for the tibia; continuous with this, on either side, is an articular surface for the malleoli; that upon the external side is the larger; *inferiorly* is a concavity, divided by a deep rough groove for the interosseous ligament; *posteriorly*, is a slight groove for the flexor longus pollicis.

The *head*[2] is upon the anterior portion of the bone. It presents a large anterior convexity, the horizontal diameter of which is the greatest. On the internal side of the head is a small triangular surface, which rests upon the calcaneo-scaphoid ligament. The head is united to the body by a narrow portion called the neck, which has a depression superiorly and inferiorly.

Scaphoid.[4]—Is oval, thicker above than it is below; *posteriorly* it has a deep concavity for the head of the astragalus; *anteriorly*, an articular convexity, divided by ridges into three triangular facets for the cuneiform bones. *Internally*, is a tubercle for the insertion of the tibialis posticus tendon; and *externally*, there is sometimes a small articular face for the cuboid.

Cuboid.[8]—Placed at the outer portion of the foot, is somewhat cuboidal in shape; *superiorly*, it is rough and convex; *inferiorly*, is a prominent ridge for the calcaneo-cuboid ligament, and in front of this ridge is a groove, commencing at the external edge, and running obliquely forward, in which plays the tendon of the peroneus

longus; *internally*, it articulates with the external cuneiform; *anteriorly*, with the fourth and fifth metatarsal bones; *posteriorly*, is a semi-spiral surface for the greater apophysis of the os calcis.

Internal Cuneiform.[5]—Is the largest of the three cuneiform bones. It is wedge-shaped, and is placed upon the inner side of the foot. The small extremity of the wedge looks upwards. Its internal surface is convex, and immediately beneath the skin; its external surface is concave, and has articular marks for the second cuneiform and the second metatarsal bones; *anteriorly*, is the largest articular surface, for the metatarsal bone of the big toe; *posteriorly*, is a triangular articular cavity for the astragalus, with the base downwards. The *inferior* surface of the bone, or the base of the wedge, is rounded into a tuberosity; upon the inner side, is inserted the tendon of the tibialis anticus.

Middle Cuneiform.[6]—Is the *smallest* of the three, and placed with the base of the wedge upwards; *anteriorly*, it articulates with the second metatarsal bone; *posteriorly*, it is slightly concave, and articulates with the scaphoid; *internally*, it articulates with the internal cuneiform, and *externally*, with the external cuneiform bone.

External Cuneiform.[7]—Intermediate in size between the two last. It is wedge-shaped and base upwards. *Anteriorly* it articulates with the third metatarsal bone; *posteriorly* there is a quadrangular facet for the scaphoid; *internally* it has two articular surfaces, the posterior of which is the larger, and for the internal cuneiform bone; the anterior is for the second metatarsal. *Externally* is an angular projection, in front of which is a small facet for the fourth metatarsal bone, and behind which is an articular surface for the cuboid bone.

METATARSUS.

Consists of five parallel long bones,[9] whose heads are rounded and articulate with the toes, and whose bases articulate with each of the three cuneiform and cuboid bones. There is a roughness on each side of the head to which is attached the lateral ligament. The necks are narrow.

First. Is on the inside of the foot, and is easily recognised, being the shortest and thickest of the set. Its base is large and articulates with the internal cuneiform bone, and has a tubercle below for the insertion of the peroneus longus. The head is spherical, articulating with the first phalanx in front, and below with the sesamoid bones.

Second. Is the longest. Its base articulates with the middle cuneiform, on the inside with the internal cuneiform, and on the outside with the third metatarsal and external cuneiform.

Third. Is distinguished by the external surface of its base having two articular facets for the fourth metatarsal. The base articulates with the external cuneiform.

Fourth. Its base articulates with the cuboid, and on either side with the contiguous metatarsal bone. The internal lateral face of the bone is distinguished by having two articular marks.

Fifth. Is the smallest and readily recognised by the large tubercle projecting backwards and outwards from the base, into the superior part of which is inserted the peroneus tertius, and into the extremity the peroneus brevis. This process is a surgical guide in Hey's amputation of the foot. The base articulates with the cuboid and fourth metatarsal.

TOES.

There are five on each foot. Each consists of three *phalanges*, with the exception of the first or great toe, which, like the thumb, has but two.[10] [11]

The *first row*[12] of phalanges are smaller than those of the fingers, and readily distinguished by the narrowness of their bodies. The bases have a single concavity; the anterior extremities have two convexities, separated by a groove.

The *second row*.[13]—These phalanges have hardly any body; the posterior extremities have two concavities separated by a ridge; and the anterior, two convexities separated by a groove.

The *third row*.[14]—These phalanges are very small; their bases have two concavities and a ridge. The anterior extremity is flat and rough.

Sesamoid Bones.—These are four small sections of a sphere of bone; two being imbedded in the tendon of the flexor brevis pollicis of each foot. The flat surfaces play on the inferior part of the head of the metatarsal bone of the great toe.

SECTION II.

ARTICULATIONS.

LIGAMENTS.

An articulation or joint is the connexion of one bone with another. Where much motion is required, it is necessary that *cartilage, ligaments, and synovial* membranes should be employed in the mechanism.

Cartilage.—Is white, flexible, elastic, and hard. Its chemical composition is, gelatine 44·5; water 55; phosphate of lime 0·5. By boiling it becomes yellow, swells, and the gelatine is dissolved. It resists mortification and putrefaction longer than any tissue except bone. When dried it becomes hard and contracted, and semi-transparent, resembling common glue. Soaking in water restores its appearance. It contains no red blood-vessels, nor can nerves

or lymphatics be traced in it. Microscopically examined it exhibits oval cells. Old age disposes it to ossify, particularly in the ribs and larynx.

Perichondrium is the fibrous investing membrane of cartilage, corresponding to the periosteum of bone.

Articular cartilages.—These cover the extremities of bone and obviate or equalize pressure. Those lining the cavity are thicker on the edges; those covering a convexity are thicker in the middle. *Inter-articular* cartilages are free and moveable in the joint, not covering a bony surface, and held in their places by connexion with ligaments: they are called menisci, from their shape.

Fibro-cartilage.—Is stronger and tougher than cartilage; it is composed partly of ligament and partly of cartilage; it is found in the ear, at the symphysis pubis, and between the vertebræ.

Ligaments consist of *fibrous* tissue, of which there are two kinds, *white*, which is inelastic, and *yellow*, which is elastic; the white is found in tendons, fasciæ, and in most of the ligaments; the yellow is found in the ligamentum nuchæ, and in many vessels and ducts.

Ligaments are called *capsular* when they are bag-like, as at the shoulder and hip; *funicular*, when cord-like, and *membranous* when like a riband.

Synovial membranes are thin, transparent, closed serous sacs, lining capsular ligaments, and secreting an albuminous fluid called *synovia*, which resembles in appearance the white of an egg. It lubricates the joints, and prevents attrition. Masses of fat outside of the synovial membranes are usually called *glands of Havers*. They do not secrete, however, but serve a mechanical purpose in filling up spaces which would otherwise be formed in many articulations during the performance of certain movements. The synovial fringes are nothing but folds of the synovial membrane, including small portions of fat.

The principal kinds of articulations are termed:

Synarthrosis, implying immobility, and including

Sutura.—Bones of the skull.

Harmonia.—Superior maxillary bones.

Schindylesis.—Vomer with processus azygos.

Gomphosis.—Teeth with alveoli.

Amphiarthrosis implies partial motion, and is exemplified in the symphyses, and in the bodies of vertebræ.

Diarthrosis is a moveable articulation, and includes

Arthrodia.—Such connexions as exist between the tarsal and carpal bones.

Ginglymus.—Hinge-like joints, such as the elbow and ankle.

Enarthrodia.—Ball-and-socket joints, such as the hip and shoulder.

ARTICULATION OF THE LOWER JAW.

Capsular Ligament.—Extends from the border of the glenoid cavity of the temporal bone, and surrounds the neck of the condyloid process of the lower jaw.

Fig. 30.

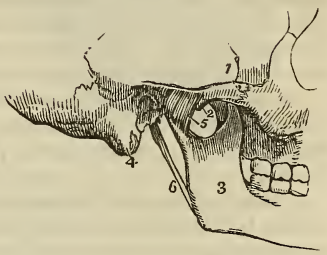

External Lateral Ligament.[5]—Is broad and triangular, covering the outside of the joint, extending from the tubercle at the root of the zygoma to the outside of the neck of the condyle. (Fig. 30.)

Internal Lateral Ligament.—Properly speaking, not a ligament but a fibrous band or sheath for the protection of vessels and nerves from the contraction of the pterygoid muscles. It passes from the spinous process of the sphenoid to the spine at the margin of the posterior mental foramen.[4] (Fig. 31.)

Stylo-Maxillary,[6] (Fig. 31,) is an extremely thin fibrous band, extending from the styloid process of the temporal bone to the angle of the lower jaw.

Fig. 31.

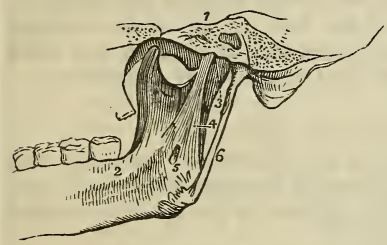

Fig. 32.

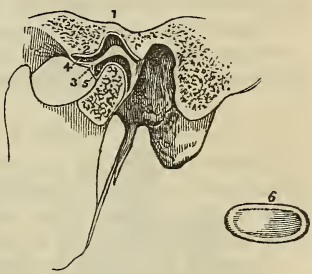

Internal Articular Cartilage[3] is a thin oval plate, dividing the joint into two cavities. It is partly concave above and below, thick at the edges. (Fig. 32.)

The Two Synovial Membranes.[4 5] (Fig. 32.) One is reflected between the glenoid cavity and the interarticular cartilage; the other between the cartilage and the condyle of the jaw. When the cartilage is perforate, the two cavities are lined by one synovial membrane.

LIGAMENTS OF THE VERTEBRÆ.

BODIES.

Intervertebral Substance.—The bodies of the vertebræ are united by fibro-cartilaginous disks, which are twenty-three in number, consisting of concentric rings; toward the centre there is a yellow jelly-like mass, in a state of compression; it is whiter and more abundant in infancy. On this account persons are stiffer in old age, and are shorter in the evening than they are in the morning.

Anterior Vertebral Ligament[1] is in front of the bodies of the vertebræ (Fig. 35[1]); extending from the second vertebræ of the neck to the first of the sacrum; it is thin and gradually increases in breadth.

Posterior Vertebral Ligament.—It lies upon the posterior surface of the bodies of the vertebræ, and extends from the occiput to the os coccygis; it is narrow and thick in the thorax, adheres closely to the intervertebral substance, and its edges present a serrated appearance.

Processes.—*Oblique.*—These are surrounded by capsular ligament, lined by a synovial membrane.

Spinous.—The spaces between the processes are filled by the *inter-spinal ligaments.* In the back they are triangular, in the loins quadrangular, and in the neck deficient. The free edge of the ligament is thick and cord-like.

Ligamentum Nuchæ.—Continuation of the last, reaching from the seventh cervical vertebra to the vertical ridge on the occiput.

Yellow Ligaments are between the bony bridges of the vertebræ —twenty-three pairs; the first is between the second and third vertebræ. They are remarkable for their elasticity and colour.

ATLAS AND OCCIPUT.

Anterior Ligament, is a strong, broad ligament, extending from the superior edge of the anterior arch of the atlas to the basilar process of the occiput. The middle portion is thick, and connected with the tubercle of the atlas.

Posterior Ligament, is thin, broad, and loose, extending from the posterior arch of the atlas to the corresponding edge of the foramen magnum occipitis. It is perforated by the vertebral artery.

Capsular Ligament, surrounds the superior oblique process of the atlas and the condyloid process of the occiput. Thicker and stronger in front.

ATLAS AND DENTATA.

Transverse Ligament, stretches across the atlas from one tubercle

to the other, dividing it into two rings[2] (Fig. 33), and has an appendix above,[3] connecting it with the occiput, and one below,[4] connecting it with the dentata.

Fig. 33.

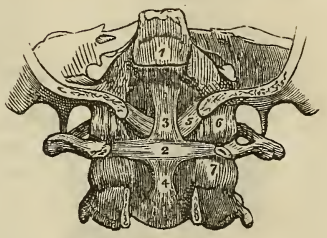

Moderator Ligaments are short and thick; extending from the sides of the apex of the processus dentatus[5] to a process on the inner side of each condyle. They limit rotation of the head.

Middle or *Straight Ligament*, reaches from the tip of the processus dentatus to the anterior edge of the foramen magnum.

Capsular Ligament of the oblique process of the atlas and dentata is very loose.

Lacerti Ligamentosi are ligamentous bands extending from the occiput to the posterior part of the body of the dentata.

LIGAMENTS OF THE PELVIS.

Sacro-Iliac Symphysis.—The articular surfaces are covered by cartilage and united by short, thick, strong fibres, which are with difficulty divided. A yellow fluid is sometimes interposed, and in children and pregnant women a synovial membrane.

Sacro-Iliac Ligament; short ligamentous fibres passing from bone to bone surrounding the joint, and thicker behind.

Fig. 34.

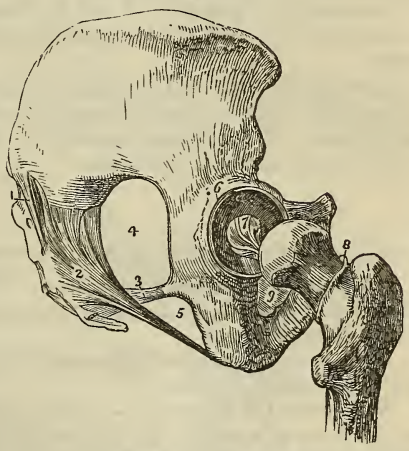

Sacro - Spinous Ligament; consists of two laminæ, composed of numerous strong fibres, passing from the posterior inferior spinous process to the transverse processes of the third and fourth sacral vertebræ.

Greater Sacro-Sciatic Ligament,[2] extends from the posterior inferior spinous process of the ilium, margin of the sacrum and of the first bone of the coccyx, to the inner margin of the tuberosity and ramus of the ischium.

Lesser Sacro-Sciatic Ligament; in front of last; arises from the

side of the sacrum[3] (Fig. 34), and coccyx; inserted into the spine of the ischium.

Fig. 35.

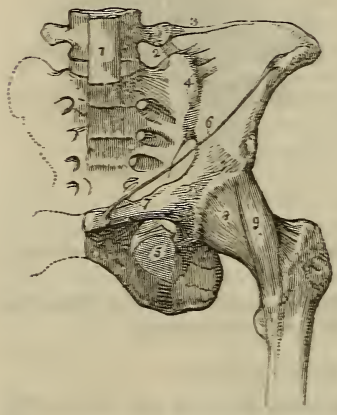

These two ligaments form the posterior and lateral boundaries of the pelvis, converting the sacro-sciatic notch into two foramina[4 5] (Fig. 34).

Ilio-Lumbar Ligament, passes from the transverse process of the last lumbar vertebra to the posterior part of the crest of the ilium.[3] (Fig. 35.)

Lumbo - Sacral Ligament, arises from the transverse process of last lumbar vertebra, and is inserted into the upper part of the sacrum.[2] (Fig. 35.)

Anterior Coccygeal Ligament.—Its fibres are indistinct, often wanting—runs in front of the whole length of coccyx from the last bone of the sacrum.

Posterior Coccygeal Ligament, arises from the inferior margin of the sacral canal, and terminates at the second bone of the coccyx.

Obturator Ligament[5] (Fig. 35).—Fills up the thyroid foramen; is membranous and thin, perforated at its upper part for the transmission of the obturator vessels.

Sub-Pubic Ligament.—A thick, triangular ligament, rounding the apex of the arch of the pubis; reaching from one bone to the other.

Symphysis Pubis.—The bones are connected by fibro-cartilage, resembling intervertebral substance; sometimes there is a synovial membrane. A few transverse fibres in front and behind are called anterior and posterior ligaments.

THORAX.

VERTEBRÆ WITH THE RIBS.

Anterior or Radiated Ligament.—Short fibres radiating from the head of the rib, to the two contiguous vertebræ and the substance between them.

Capsular Ligament.—Surrounds the head of the rib; thickest above and below.

Inter-articular Ligament.—A thin band passing from the ridge on the head of a rib to the intervertebral substance, dividing the cavity into two parts, each of which has a distinct synovial membrane. The first, eleventh, and twelfth are exceptions to this rule.

The tubercle of the rib is connected to the transverse processes by a *capsular* ligament, and also the *internal costo-transverse ligament*[3] passes from the inferior edge of the transverse process, and is inserted in the sharp edge of the neck of the rib below.

External costo-transverse Ligament.[4]—Is quadrangular, extending between the transverse process and the contiguous rib.

Middle costo-transverse Ligament.—A collection of short irregular fibres mixed with reddish adipose tissue, passing directly from the transverse process to the rib.

Fig. 36.

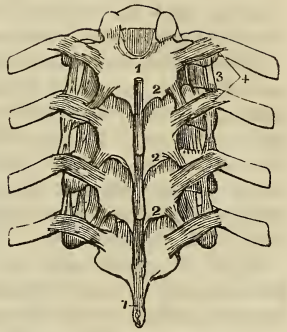

RIB WITH STERNUM.

Anterior extremity of ribs.

Anterior radiated Ligament[5] (Fig. 37).—Consists of a number of fibres, reaching from the cartilage of the true ribs to the sternum, and blending themselves with the periosteum.

Posterior radiated Ligament.—Not so distinct as the last, passing in the same direction upon the under surface.

Costo-xiphoid Ligament.—Reaches from the cartilages of the sixth and seventh ribs, to the ensiform cartilage.

A synovial membrane and ligamentous fibres are found between the sixth and seventh, and eighth and ninth, sometimes.

UPPER EXTREMITY.

SHOULDER.

The clavicle and sternum have interposed a wedge-shaped *inter-articular cartilage*, dividing the joint into cavities, and the whole is surrounded by a strong *capsular ligament*[1] (Fig. 37), which is fibrous and thick, looser before than it is behind.

Fig. 37.

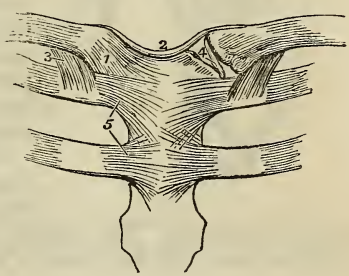

Inter-clavicular Ligament.[2]—A ligamentous cord stretching from the end of one clavicle to the other.

Rhomboid Ligament.[2]—A strong, thick ligament, proceeding from the upper surface of the cartilage of the first rib obliquely upwards and outwards to the inferior and sternal end of the clavicle.

CLAVICLE AND SCAPULA.

Capsular Ligament.[1]—Surrounds the acromion process of the scapula, and the external extremity of the clavicle. The fibres upon the upper and lower surface are very distinct and strong.

Coraco-clavicular Ligament[2] (Fig. 38).—Consists of two parts, one of which is called *conoid;* it is triangular and vertical; commencing at the root of the coracoid process, it expands as it ascends, and is fastened to the tubercle at the inferior extremity of the clavicle. The other is called *trapezoid;* it is in front of the last, arises at the internal edge of the coracoid process, and proceeds obliquely upwards to a ridge on the lower surface of the external end of the clavicle.

Bifid Ligament.—Is an aponeurotic expansion, commencing at the coracoid process, terminating upon the inferior surface of the clavicle, and also upon the cartilage of the first rib. It protects the inferior portion of the subclavius muscle.

Coraco-acromial Ligament[3] (Fig. 38).—Is thick and triangular; the base commences upon the outer edge of the coracoid process, and the apex is fastened to the acromion; it prevents a dislocation of the humerus upwards.

Coracoid Ligament[4] (Fig. 38).—Is a small transverse fasciculus, stretched across the coracoid notch, and converting it into a foramen for the supra-scapular artery and nerve.

HUMERUS AND SCAPULA.

Fig. 38.

Capsular Ligament[5] (Fig. 36).—Surrounds the glenoid cavity and the neck of the humerus; it is loose and perforated by the tendon of the long head of the biceps.[7] It is deficient behind; this deficiency is supplied by the tendons of the surrounding muscles, particularly the sub-scapularis.

Coraco-humeral Ligament.[6]—Is sometimes called adscititium; is a thick fasciculus of the capsular ligament, proceeding from the coracoid process. It holds the head of the bone on a level with the glenoid cavity.

Glenoid Ligament.—A prismatic ring of fibro-cartilage, attached to the edge of the glenoid cavity, and increasing its depth. The synovial membrane is very extensive, and communicates with the bursæ of tendons.

ELBOW JOINT.

Capsular Ligament.—It surrounds the extremities of the humerus, radius, and ulna. It is strengthened by the

Internal lateral Ligament[2] (Fig. 39), which, commencing at the internal condyle, has two insertions, one into the coronoid, and the other into the olecranon process of the ulna.

External lateral Ligament[4] (Fig. 40).—Is triangular, commencing at the external condyle, and terminating in the annular ligament.

Coronary or annular Ligament[5] (Fig. 41).—Is strong and dense, surrounding three-fourths of the head of the radius; its extremities are fastened on either side of the lesser sigmoid cavity.

Interosseous Ligament[5] (Fig. 39).—Is a ligamentous membrane, filling up the space between the radius and ulna throughout their length. It is perforated at its upper part, for the transmission of the posterior interosseal artery; this deficiency is compensated for by the *ligamentum teres*[4] (Fig. 39), whose fibres are oblique and in an opposite direction to those of the interosseous ligament. It commences at the coronoid process, and terminates below the tubercle of the radius.

Fig. 39.

Fig. 40.

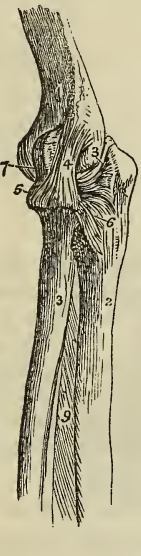

Fig. 41.

Sacciform Ligament.—Is a loose capsular ligament, surrounding the lower extremity of the ulna, and attached to the lesser sigmoid

cavity of the radius. This is strengthened by the *anterior radio-ulnar ligament*[2] (Fig. 42), which passes obliquely between the two bones, and the *posterior radio-ulnar ligament.*

WRIST JOINT.

This joint is formed by the greater sigmoid cavity of the radius and the scaphoid, semilunar, and cuneiform bones. It is surrounded by the capsular ligament, which is strengthened by an *anterior ligament*[3] (Fig. 42), a broad membranous layer; *an internal lateral ligament,*[5] reaching from the styloid process of the ulna to the cuneiform and pisiform bone; an *external lateral ligament,*[4] reaching from the styloid process of the radius to the scaphoid bone; and a *posterior ligament*, which is thin and loose, passing between the posterior surface of the radius, semilunar, and cuneiform bones.

Fig. 42.

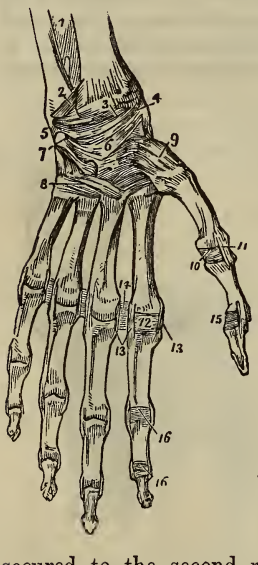

Fig. 43.

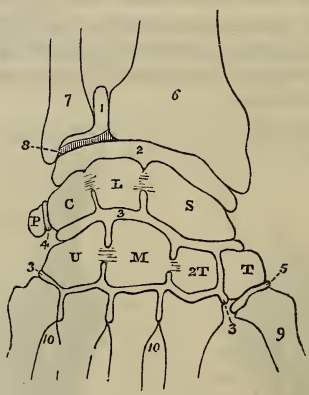

The *carpal* bones are held together by *dorsal* and *palmar* ligaments. The *pisiform bone* has a distinct *capsular ligament.* The arrangement of the synovial membrane is represented by Fig. 43.

The bases of the *metacarpal bones* are secured to the second row of the carpal bones by fibrous bands called *dorsal* and *palmar* ligaments. That of the thumb has a true *capsular ligament.*

FINGER JOINTS.

The joint between the metacarpal bones and the first row of phalanges, is a ball-and-socket joint. It is secured by an *internal* and *external* lateral ligament[13] (Fig. 42), which are very thick in pro-

portion to the size of the bone; the *anterior or palmar ligament*[12] is in front, and has the flexor tendons playing over it; the extensor tendon taking the place of a *posterior ligament.* The heads of the metacarpal bones are also connected by transverse ligaments.[14]

The second and third joints of the finger[16] are arranged upon the same principle as the first, with the exception of the transverse ligament.

LOWER EXTREMITY.

HIP JOINT.

Capsular Ligament[8] (Fig. 35).—Is the largest and strongest capsule in the body, and surrounds the acetabulum and the neck of the femur. It is thicker and longer in front than it is behind, and is strengthened by a bundle of fibres,[9] called *ilio-femoral.*

Cotyloid Ligament[6] (Fig. 34).—Is a thick prismatic ring of fibro-cartilage, surrounding and deepening the acetabulum.

Ligamentum teres[7] (Fig. 34).—Is attached to a pit upon the head of the femur, and divides into two fasciculi, which are inserted into the corners of the notch of the acetabulum and the cotyloid ligament. The synovial membrane is extensive, and the Haversian mass is large.

KNEE JOINT.

This joint is surrounded by an expansion of the fascia lata of the thigh, called the *involucrum generale.*

Anterior Ligament.—Is the *ligament of the patella*[3] (Fig. 44); it is the strongest ligament of the body. It is a continuation of the tendon of the quadriceps muscle,[1] in which the patella[2] is enclosed, previous to its insertion into the tubercle of the tibia.

Fig. 44.

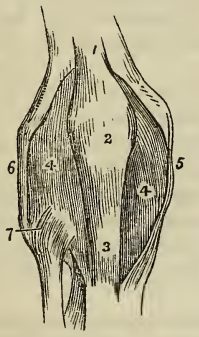

Fig. 45.

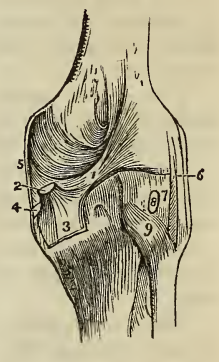

Posterior Ligament.—Is the *ligament of Winslow*[1] (Fig. 45). It is a broad ligament passing obliquely from the external condyle of the femur to the posterior part of the internal tuberosity of the tibia. Its strongest fasciculi are derived from the semi-membranosus tendon.[2] It has numerous openings for blood-vessels.

Internal Lateral Ligament.—Is broad, thin, and membranous,

extending from the internal condyle of the femur to the lower part of the internal tuberosity of the tibia.[5].

External lateral Ligament.—Is a strong cord-like ligament[6] reaching from the external condyle to the superior extremity of the fibula. Posterior to this, and parallel with it, is another shorter ligament also connecting the femur and fibula.

Semilunar Cartilages.—Are two prismatic rings of fibro-cartilage, deepening the articular surfaces of the tibia. The external[7] (Fig. 46) is the smaller and more circular. The internal[6] is the larger and a semicircle. The extremities are attached to the spinous process of the tibia. A small transverse ligament[4] connects them behind.

Crucial Ligaments.—These cross each other. The *anterior*[2] (Fig. 46), arises from a roughness in front of the spine of the tibia, and is inserted into the posterior part of the internal face of the external condyle. The *posterior*[3] commences at a roughness behind the spine of the tibia, and is inserted at the anterior part of the external face of the internal condyle of the femur.

Fig. 46.

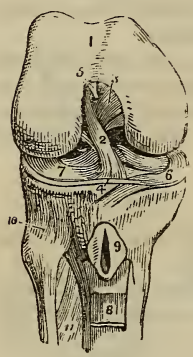

The synovial membrane is the most extensive in the skeleton; it forms folds in the interior of the joint, one of which is called the *ligamentum mucosum*,[5] which is triangular in shape, passing from the condyloid notch to a mass of fat in front of the tibia. The *alar ligamennts* are fringed folds of the synovial membrane, containing masses of fat on each side of the patella.

The tibia and fibula are connected above by the

Anterior Superior Ligament[7] (Fig. 44).—A short, strong ligament, extending obliquely between the heads of the two bones in front.

Posterior Superior Ligament[9] (Fig. 45).—Passes obliquely between the heads of the two bones behind. The synovial membrane of this articulation is generally distinct from that of the knee-joint.

Interosseous Ligament[11] (Fig. 46).—Is stretched between the tibia and fibula throughout their entire length, and an opening at its upper part transmits the anterior tibial artery.

Anterior Inferior Ligament (Fig. 48).—Is a broad band passing obliquely between the two bones in front, and at their lower extremity.

Posterior Inferior Ligament.—Is somewhat similar, passing obliquely between the lower extremities of the two bones. Besides these, the tibia and fibula are united by short strong fibres, passing from the contiguous surfaces of the two bones.

ANKLE JOINT.

It is the most perfect hinge in the body.

Internal Lateral or *Deltoid Ligament*[6] (Fig. 47).—Is triangular; its apex is attached to the internal malleolus, and its base to the os calcis, astragalus and calcaneo-scaphoid ligament. The tibialis posticis runs in a trochlea upon it.

External Lateral Ligament[6 7 8] (Fig. 48).—Consists of three parts, which arise from the external malleolus; the *anterior* passes forwards, and is inserted into the astragalus; the *middle* descends, and is inserted into the os calcis; the *posterior* passes backwards, and is fastened to the astragalus. The synovial membrane is large and loose, and is reflected upon some condensed cellular tissue in front, which is sometimes called the anterior ligament.

Fig. 47.

Fig. 48.

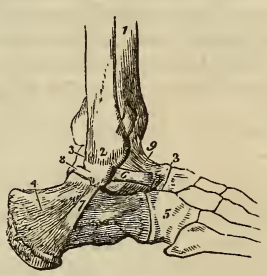

ARTICULATIONS OF THE FOOT.

The *astragalus* and *os calcis* are united by a strong, thick, interosseous ligament, passing from the groove on the upper surface of the os calcis to the corresponding one of the astragalus.—*Posteriorly* there is a short ligament, called the *posterior* ligament, upon which plays the tendon of the flexor longus pollicis muscle.

The *os calcis* and *scaphoid* are united by the *superior calcaneo-scaphoid* ligament, which passes from the inside of the greater apophysis of the os calcis to the outside of the scaphoid; and by the *inferior calcaneo-scaphoid*, which occupies the triangular interval between the lesser apophysis of the os calcis and the tubercle of the scaphoid. Upon this rests a portion of the head of the astragalus.

The *os calcis* and *cuboid* are united by the *superior* calcaneo-cuboid ligament, which is a very thin flat band of fibres extending directly forwards from the os calcis to the cuboid, and by the *inferior* calcaneo-cuboid, which consists of two planes of fibres, of which the superficial or inferior layer is a strong band of pearly-white fibres,

extending from all the under surface of the os calcis to the groove of the cuboid. The deeper-seated or superior layer, extends from the anterior tuberosity of the os calcis obliquely to the ridge of the cuboid.

The *astragalus* and *scaphoid* are united by a thin semicircular ligament, consisting of parallel fibres, extending from the neck of the astragalus to the margin of the concavity of the scaphoid.

Cuneiform Bones.—They are united to each other and the scaphoid, by dorsal, plantar, and interosseal ligaments.

The Bases of the Metatarsal Bones.—That of the first is united by a strong capsular ligament with the internal cuneiform bone, having a distinct synovial membrane. Those of the second and third are united with the middle and external cuneiform bone, by dorsal and plantar ligaments; those of the fourth and fifth by dorsal and planter ligaments with the cuboid.

The heads of the metatarsal bones are united to each other by a strong transverse ligament; and to the phalanges by two lateral, the plantar, and an expansion of the extensor tendon.

The phalanges.—Their ligaments are arranged similarly to those of the hand, and consist of two lateral and one plantar.

TEETH.

The teeth are placed in the alveolar processes of the upper and lower jaw, and are the hardest portion of the human body. The permanent teeth are thirty-two in number, sixteen in each jaw; they are divisible into four classes. On each side of each jaw there are two *incisors*, one *cuspid*, two *bi-cuspid*, and three *molars;* each tooth consists of a body or crown, which is the part exposed above the gum; the neck, a narrow portion surrounded by the gum; and a root or fang which is contained within the alveolus. The roots are surrounded by a periosteum, and perforated at their extremities by a foramen for the transmission of an artery and nerve.

Incisors.—Are next to the median line; their edge is bevelled, and in early life serrated; the root is single and conoidal; those of the upper jaw are larger than those of the lower jaw.

Cuspid, or Canine.—Is next to incisors. Its body is conoidal, and it has the longest root. Those of the upper jaw are sometimes called eye-teeth, those of the lower jaw stomach-teeth.

Bi-cuspid.—Are next in size to the molars. The body has two grinding points, of which the external is the larger. The root is sometimes bifid and grooved upon either side. The anterior is the smaller.

Molars.—They have large quadrilateral bodies, with four or five grinding points. In the upper jaw they have three divergent roots,

two of which are external, and one is internal. In the lower jaw they have but two roots, which are anterior and posterior. The third molar or wisdom-tooth is smaller, and less perfectly developed than the other two, and does not appear until manhood.

Fig. 49.

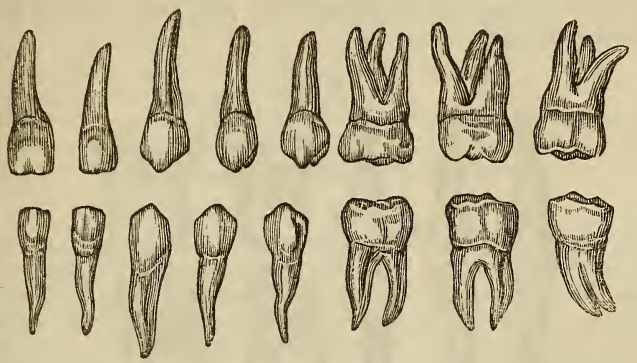

Structure.—Each tooth has three textures, the *ivory* or *dentine*, the *enamel*, and the *cementum*.

The *ivory* forms the largest portion of the body, neck, and root, and gives form to the tooth. It is of a dull white colour, and harder than bone. Although apparently very compact, nevertheless it consists of numerous fine tubes (*dental tubuli*), the average diameter of which is about $\frac{1}{4\,5\,0\,0}$ of an inch. These tubes are larger at their commencement, which opens upon the pulp-cavity. They radiate in nearly parallel lines, and their finest ramifications sometimes terminate in minute cells or in loops. The tubular character is proven by the passage of ink and other fluids along them. The intertubular substance is translucent, and finely granular.

Dentine consists of 28 parts of animal, and 72 parts of earthy matter. The principal components are gelatine and phosphate of lime. It contains neither blood vessels nor nerves.

The *enamel* is the hardest portion; it encrusts the body; it is white, brittle, and semi-transparent, thicker upon the grinding surface, and terminates by a thin edge at the neck. Its structure consists of radiating hexagonal prisms of about $\frac{1}{5\,0\,0}$ of an inch in diameter: it possesses neither vessels nor nerves. It is composed of earthy matter almost entirely; so that the action of an acid leaves but a trace of the animal matter.

The *cementum* or crusta petrosa forms a thin coating over the root of the tooth, from the apex to the enamel. It resembles bone

in structure, containing cells and canaliculi. It increases with the advance in age, making the teeth of old persons appear to project.

A *cavity* exists in the body and fangs of the teeth, which is filled by *a pulp*, principally composed of an artery, vein, and nerve, which enter at the small orifice at the point. The pulp-cavity diminishes in adult life by the formation of cementum in its upper part, which prevents the exposure of the pulp even when the body is much worn away.

Fig. 50.

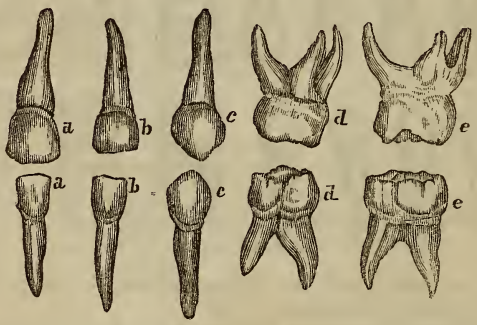

An infant gum contains the rudiments of fifty-two teeth, in separate cavities; twenty of them appear between the sixth month and third year of age, and fall out between the sixth and twelfth year; they are therefore called the *deciduous* or milk teeth, of which there are *two incisors, one cuspid,* and *two molars* on either side of each jaw. The order of the irruption is irregular, but the average is as follows: at the seventh month, two middle incisors; ninth month, two lateral; twelfth month, first molar; eighteenth month, canine; twenty-fourth, two last molars. The teeth of the lower jaw precede those of the upper by a short interval. The original state of the tooth is a soft pulp contained in a sac, which pulp gradually becomes converted into dentine. The enamel is formed in the outer wall of the sac. The cementum is formed by the periosteum of the tooth, which is the remains of the old sac.

INTEGUMENTS, ETC.

CELLULAR TISSUE.

The cellular or areolar tissue is that substance found so universally distributed throughout the body. It serves for the purpose of connecting muscles and organs, and forming a protection, being par-

ticularly abundant beneath the skin. When parts are torn in a subject it is very distinct, and its characters can then be best observed. It will be found to be white in colour usually, and to consist of a number of cells which freely communicate, as is manifested in anasarca, emphysema, and ecchymosis. It is elastic and tough when fresh; when dried it is opaque and crisp; long boiling converts most of it into gelatine. Its *toughness* is due to one set of fibres, which are white, inelastic, and straight; of such most ligaments are formed. Its *elasticity* is due to another set of fibres, which are yellow, elastic, and curling; of such the ligamentum nuchæ and middle coat of arteries are composed.

It is very vascular, though most of its vessels do not contain red blood in health, as may be seen in inflammation produced by the air or any other stimulus. Its moisture is due to serum.

FAT.

Fat is found in almost every part of the body, with the exception of the penis, ear, eyelid, and ball, interior of cranium, lungs, &c., &c., but in great abundance under the skin and around the serous membranes. It is of a yellowish colour, and in life is in a semi-fluid condition. It consists of three elements, stearine, margarine, and elaine, which are contained in vesicles aggregated in lobules, held together by areolar tissue. In women fat is more abundant; and in infants it is upon the surface of the body, rather than in the cavities.

It is of use in diminishing pressure upon the hands and feet; retains heat, being a bad conductor, and assists in nutrition, as is manifested in hibernating animals.

SKIN.

The skin is an external covering and protection, as well as an organ of touch and excretion. Its colour and thickness vary in different persons and in different parts of the same person. At the orifices of cavities it is converted into mucous membranes. The largest *wrinkles* are produced by the contractions of muscles, and by the flexion of joints; others of an angular variety, owing to the contractile character of the skin, are seen upon the back of the hand; the third variety is spiral.

The skin is perforated by hairs and perspiratory ducts, and contains sebaceous glands; these are considered as *appendages*. The skin consists of two layers, the true skin, also called cutis vera or chorion, and the cuticle or epidermis. The *cutis vera*[c] is the thicker and deeper of the two: it is white, and semi-transparent in all persons; its internal or inferior surface is much blended with the subjacent cellular tissue, and contains a number of pits or depressions; the external surface has a number of conical projections called *papillæ tactus*,[b] which are particularly numerous in those

parts where there is much motion. On the hands and feet they are arranged in spiral and semicircular rows, which occasion a similar wrinkle of the cuticle. They consist of an artery, vein and nerve; the sensibility of a part is in ratio to their number. The skin itself is formed of condensed cellular tissue, the yellow fibrous element predominating where great elasticity is required, as in the armpit; the white element, where resistance is demanded, as in the sole of the foot. Between the interstices of these fibres pass innumerable vessels, ducts, &c., &c. It is thickened by pressure; boiling reduces it to gelatine; and tannin converts it into leather.

Fig. 51.

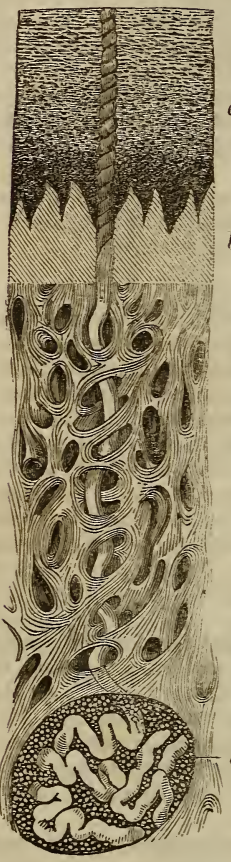

The *cuticle* or *epidermis*[a] affords protection to parts most exposed to pressure or friction; its thickness varies with the amount of pressure to which it is subjected, as is seen by the comparison of the hand of the artisan with that of a delicate female. It is not permeated by vessels or nerves, but consists of particles arranged in different laminæ; those that are deepest are granular, those of the next layer are more compressed, whilst those upon the surface are mere scales. These superficial scales, which are horny, are constantly being shed, and new particles constantly supplied by the moist granules, which are below. The laminated condition makes it easy to divide into different layers, and the inferior layer was formerly called by a distinct name, *rete mucosum;* but it is nothing more than the deepest or most recently-formed part of the cuticle, in which are cells containing the colouring matter: this is very abundant in moles, freckles, and in the skin of negroes.

NAILS.

The *nails* are modifications of the epidermis. Their appearance is too familiar to every one to demand description. That portion which is concealed is called the *root;* that which is free or projecting,

the *edge;* that attached to the surface of the cutis is the *body*. The *matrix* is that portion of the cutis under the root and body, which produces the nail. The *lunula* is that crescentic, white portion of the matrix near the root, and is due to a different arrangement of the capillaries in that part of the matrix. The nail firmly adheres to the matrix, and is moulded upon it like the epidermis in other situations. The epidermis or cuticle is *continuous* with the nail, and neither passes over or under it; being essentially of the same structure. By maceration the epidermis and nail[n n] can readily be removed from the *cutis vera*.[m m] The border of the root of the nail is jagged, thin, and soft, and consists of newly-formed substance; the deep surface of the body is also soft, and marked by longitudinal grooves corresponding to the papillary ridges on the surface of the matrix; but the edge and superficial portion of the nail is composed of scales more dense and fibrous.

Fig. 52.

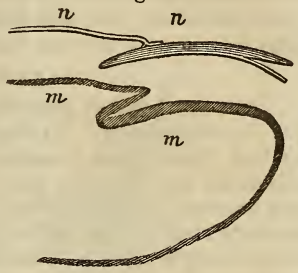

HAIRS.

Hairs are found on all parts of the surface, except the palms of the hands, and soles of the feet; and vary in length, thickness, shape, and colour, according to situation, age, sex, or race. The *shaft* is that portion projecting beyond the surface; the *bulb* is that extremity contained in a follicle of the skin. The cuticular lining of this follicle is continuous with the bulb itself, there being a gradual change in the scales, as they pass from the follicle into the hair-bulb; the hair itself grows from the bottom of the follicle, like the nail from the matrix, or the epidermis from the cutis. If the hair is to be coloured, pigment-granules are here also developed.

The *human* hair is a *rod*, and not as commonly supposed, a *tube*. The scales in the axis of the hair are softer, and not so closely condensed as those of the surface, and thus they contain a larger amount of pigment in the interstices, which produces that dark appearance which is mistaken for a tube; this loose, porous structure in the middle, is sometimes called the *medulla*, and the condensed, fibrous exterior is termed the *cortex;* the scales of which are imbricated, that is, they overlap each other like the shingles of a roof. Where the hairs are large, and especially where they serve as tactile organs, there may be a papilla in the bottom of the follicle furnished with nerves and vessels, which projects into the bulb, as in the whiskers of a cat, and the quills of a porcupine; an approach to this papillary projection may be seen in some of the hairs of man, but their size is much overrated.

The hairs maintain a vital, though not a vascular connexion with the body; the moisture is partly due to the sebaceous glands, whose secretion passes through them by capillary attraction. Mental emotion has occasioned the hair to become white in a single night; some account for this by a secretion of fluid acid which percolates the tissue of the hair, and chemically destroys the colour. Ordinary gray hair resembles other hair in every respect, save that of colour.

SWEAT GLANDS.

These are found in great number upon the inferior surface of the *cutis vera* generally. In the axilla they form a layer, an eighth of an inch thick, which is mammillated, and of a reddish colour. They are about the size of a pin's head, are soft, and often compressed and surrounded by a network of capillary blood-vessels. They are distinguishable from pellets of fat by their pink colour, and semi-transparent texture. When magnified, they are seen to consist of a solitary tube, intricately ravelled, one end of which is closed, and buried within the gland, and the other (Fig. 51), opens upon the skin. The duct consists of two portions: the *dermic* part winds tortuously through the true skin, and terminates in a funnel-shaped opening between the papillæ tactus; the *epidermic* portion commences at the lower part of the cuticle, at first very indistinctly and without any defined continuity of structure with the duct below, gradually assuming the spiral form, and having the scales of which its walls are composed arranged parallel with the axis of the passage.—The secretion varies in odour in different portions of the body, and in different races.

SEBACEOUS GLANDS.

Fig. 53.

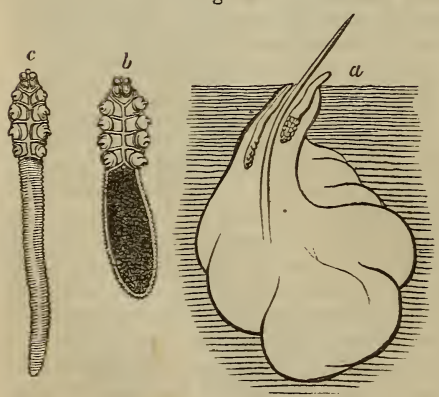

The *sebaceous glands* are found in most parts of the skin, except in the palms and soles; they are most abundant on the scalp and face, especially about the nose. The orifices open into hair follicles, or upon the general surface. They consist of a duct, terminating in a blind, pouch-like extremity, lined by an epithelium, in the particles of which are included granules of sebaceous matter. The secretion is subservient for the

lubrication of the hair and the skin. There are generally found in their ducts, parasites, of which two specimens are given in *b* and *c*,

Fig. 54.

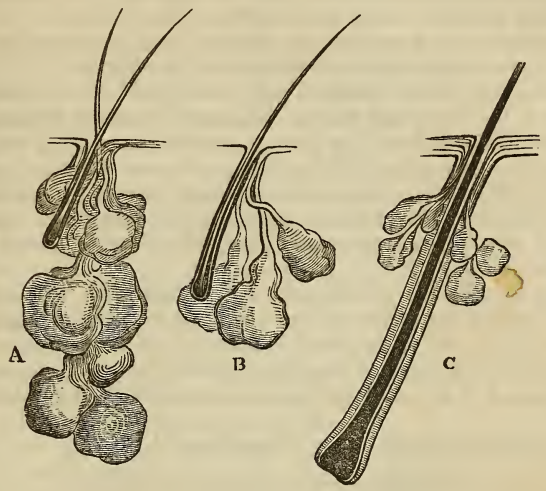

Fig. 53. These animals are found in almost every individual, especially in those possessing a torpid skin; and they multiply in sickness. The ceruminous glands of the ear resemble the sebaceous glands.

SECTION III.

MUSCLES.

Muscles are formed of that substance usually called *flesh*, which has a peculiar contractile power, producing motion; they consist, independently of the cellular tissue, vessels, and nerves, which enter into their formation, of a special tissue. Those muscles which are excited by the will, such as those of locomotion, are called *voluntary*. Those which act independently of the will, such as those of the intestines and uterus, are called *involuntary*. *Voluntary muscle* is composed of a number of bundles of fibres, called fasciculi or lacerti.

The fibres are about $\frac{1}{400}$ of an inch in diameter, and are crossed by regular transverse striæ, which give rise to the term "striped," as applied to the voluntary muscles; although there are some striped muscular fibres found in organs which are involuntary, as in the case of the heart, pharynx, and upper part of œsophagus.

Each fibre consists of a number of filaments or fibrillæ, included in a tubular sheath, formed of a tough, delicate, elastic membrane,

called the sarcolemma. Each fibrilla consists of a number of quadrangular particles, arranged in a linear series, and called *sarcous elements.*

The blood-vessels pass in between the fasciculi, and terminate in a capillary network, which passes between the fibrillæ.

The nerves also penetrate the fasciculi, and terminate in loops, which do not penetrate the sarcolemma of the fibres.

Involuntary muscles consist of pale "unstriped" fibres, with the exception of the heart and gullet. They are generally flattened, and it is doubtful whether they have a sarcolemma. They are much smaller than the striped fibres, being not more than $\frac{1}{2500}$ part of an inch in diameter. The chief constituent of muscle is fibrin.

The red colour of muscles is not altogether dependent upon the capillary vessels, but upon a peculiarity of colouring matter united with them.

Every muscle has a belly and two extremities; that which is fixed is called the *origin* or *head;* that which is moveable, the *insertion.* Those which surround orifices, are called *sphincters.*

A *tendon* is formed of condensed white fibrous tissue, reaching from the end of a muscle to some structure which it is intended to move.

For further description, see "Physiology."

MUSCLES OF THE HEAD AND NECK.

Occipito-frontalis.[1 2 3]—Has four bellies.

Origin, from the superior semicircular ridges of the occiput.

Insertion, into the superior margin of the orbicularis oculi, and corrugator supercilii, and into the internal angular process of the os frontis and os nasi. *Use;* it elevates the eyebrows, making transverse wrinkles.

Fig. 55.

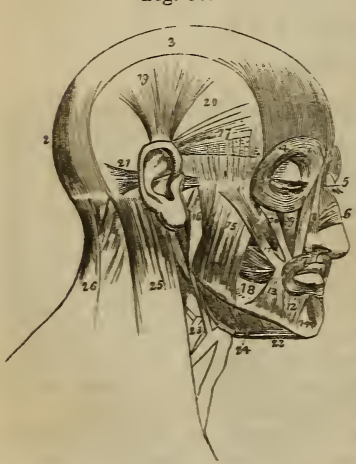

Compressor Naris.[6]—*Origin,* from the root of the ala nasi. *Insertion,* tendinously into its fellow on the dorsum of the nose, and into the lower part of the os nasi. *Use;* it either compresses or dilates the nostril.

Orbicularis palpebrarum.[4]—This is a sphincter surrounding the orbits of the eyes. *Origin,* from the nasal process of the superior maxillary, the os unguis, the internal angular process of the os frontis, and the

internal palpebral ligament. *Insertion*, into the orbitar and nasal processes of the superior maxillary, and into the palpebral ligament. *Use;* it closes the eyes.

That portion of the muscle immediately covering the eyelids is called *ciliaris*.

Corrugator supercilii.—A narrow, small, and pointed muscle, beneath the occipito-frontalis. *Origin:* internal angular process of the os frontis.—*Insertion*, into the occipito-frontalis and orbicularis. *Use;* it makes vertical wrinkles of the forehead.

Levator Labii superioris alæque Nasi.[8]—It lies on the side of the nose. *Origin*, from the nasal and orbitar processes of the superior maxillary bone. *Insertion*, into the upper lip and wing of the nose. *Use;* it elevates the wing and sides of the nose.

Levator anguli Oris.[9]—Small and concealed by the last. *Origin*, from the superior maxillary bone, below the infra orbitar foramen. *Insertion:* corner of the mouth. *Use;* elevates the angle of the mouth.

Zygomaticus minor.[10]—*Origin*, from the malar bone. *Insertion*, into the upper lip. *Use;* it raises the upper lip outwardly.

Zygomaticus major.[11]—*Origin*, from the malar bone, behind the last. *Insertion*, into the corner of the mouth. *Use;* it draws the mouth obliquely upwards and outwards.

Depressor Labii superioris alæque Nasi.—Very much concealed. *Origin*, from the alveolar processes of the incisor and canine teeth. *Insertion*, into the wing of the nose and upper lip. *Use;* depresses the upper lip and wing of the nose.

Depressor anguli oris.[13]—*Origin*, from the base of the lower jaw, on the side of the chin. *Insertion*, into the corner of the mouth. *Use;* it draws the mouth downwards.

Depressor Labii Inferioris.[12]—*Origin*, from the base of the lower jaw, beneath and in front of the last. *Insertion*, into the whole side of the lower lip. *Use;* it draws the lip downwards.

Levator Menti.[14]—Is much concealed, and best viewed from the inside of the lip. *Origin*, from the alveolar processes of the lateral incisor and canine teeth. *Insertion*, into the lower lip. *Use;* it elevates the lip.

Buccinator.[18]—*Origin*, from the coronoid process of the lower jaw, from the tuber of the upper jaw, and alveolar processes of both jaws. *Insertion*, corner of the mouth and lips. *Use;* it draws the mouth backwards, and presses the food between the teeth.

Orbicularis oris.[7]—Is a circular muscle surrounding the mouth, has neither bony origin nor insertion, but is much connected with other muscles of the mouth.

Masseter.[15 16]—*Origin*, from the superior maxillary and malar bones, and also from the zygoma of the temporal bone. *Insertion*, into the angle and external surface of the lower jaw. *Use;* it draws the jaw upwards and backwards. It is very strong, and consists of two planes of fibres.

Temporalis.—*Origin*, from the temporal fascia, and sides of the temporal, frontal, and parietal bones. A few fibres also arise from the zygoma. *Insertion*, into the coronoid process of the lower jaw. *Use;* it draws the jaw upwards.

Pterygoideus externus.[1]—*Origin*, from the pterygoid, spinous and temporal processes of the sphenoid, and from the tuber of the upper maxillary bone. *Insertion*, into the neck of the lower jaw. *Use;* it draws the jaw forwards.

Fig. 56.

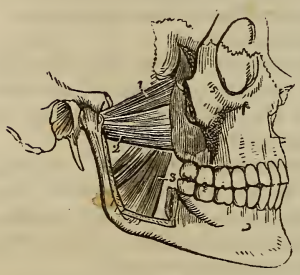

Pterygoideus internus.[2]— *Origin*, from the internal pterygoid process, and pterygoid fossa of the sphenoid; and from the Eustachian tube. *Insertion*, into the internal surface of the angle of the jaw. *Use;* it draws the jaw upwards and inwards.

MUSCLES OF THE NECK.

Fasciæ.—There are two fasciæ for the neck; the superficial and deep.

The *superficial fascia* is continuous with that which covers the whole body. It consists of two laminæ, between which are enclosed the platysma myoides muscle.

The *deep fascia* is formed of more condensed cellular tissue, and extends from the ligamentum nuchæ to the larynx in front, including between its laminæ vessels of the neck. Below it is fastened to the sternum, clavicles, and first ribs. A strong process of it exists between the styloid process of the temporal bone and the angle of the jaw, and is called the stylo-maxillary ligament. It forms a loop, which acts as a pulley to the omo-hyoid muscle, and thence is continued down behind the subclavius muscle into the ligamentum bicorne, forming a portion of the boundary of the thorax.

Fig. 57.

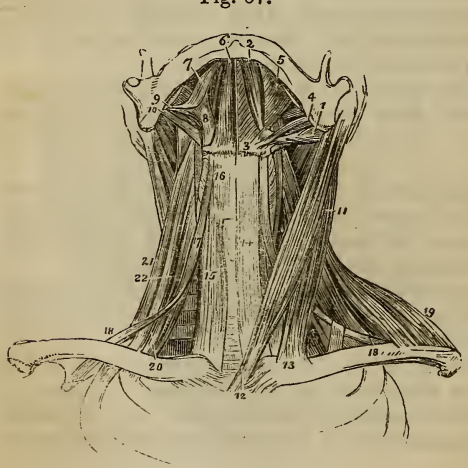

Platysma myoides.

This is included between two laminæ of the superficial fascia of the neck, is a broad, thin muscle, and not always well developed in man. *Origin*, from the condensed cellular tissue below the clavicle. *Insertion*, into the muscles and integuments upon the side of the face and lower jaw. *Use;* it draws the skin of the neck and lower jaw downwards.

Sterno-cleido-mastoideus,[11] forms the most prominent feature on the outside of the neck. *Origin*, from the upper part of the sternum, and sternal end of the clavicle. *Insertion*, into the mastoid process of the temporal and into the superior semicircular ridge of the occipital bone. *Use;* acting with its fellow, it draws the chin towards the breast.

Sterno-hyoideus.[14]—*Origin*, from the sternum, clavicle, and cartilage of the first rib. *Insertion*, into the inferior edge of the os hyoides. *Use;* it draws the hyoid bone towards the sternum.

Sterno-thyroideus.[15]—*Origin*, from the sternum and cartilage of the first rib. *Insertion*, into the side of the thyroid cartilage. *Use;* it draws the cartilage downwards.

Thyreo-hyoideus.[16]—*Origin*, from the side of the thyroid cartilage. *Insertion*, into the body and cornua of the os hyoides. *Use;* it approximates the hyoid bone and thyroid cartilage.

Omo-hyoideus.[17] [18]—*Origin*, from the superior edge of the scapula, near the coracoid notch. *Insertion*, into the base of the hyoid bone. *Use;* it draws the hyoid bone downwards. It is tendinous in its middle.

Digastricus.[1] [2]—*Origin*, from the fossa, behind the mastoid process of the temporal bone. *Insertion*, into the base of the lower jaw, at the side of the posterior mental tubercle; its middle is tendinous, and perforates the stylo-hyoid muscle near its insertion. *Use;* it elevates the hyoid bone, and opens the mouth, even when the lower jaw is fixed.

Stylo-hyoideus.[3] [4]—*Origin*, from the middle and inferior part of the styloid processes of the temporal bone: it is perforated by the digastricus. *Insertion*, into the junction of the body and cornua of the hyoid bone. *Use;* it draws the hyoid bone upwards and backwards.

Stylo-glossus.[9]—*Origin*, from the upper and internal part of the styloid process. *Insertion*, into the side of the root of the tongue. *Use;* it draws the tongue backwards.

Stylo-pharyngeus.[10]—*Origin*, from the inner side of the styloid process near its root. *Insertion*, into the side of the pharynx, between the superior and middle constrictor muscles. *Use;* it raises and widens the pharynx.

Mylo-hyoideus,[5] forms the floor of the mouth. *Origin*, from the mylo-hyoidean ridge of the inside of the lower jaw. *Insertion*, into a white tendinous line, between it and its fellow, and into the hyoid

bone. *Use;* it draws the hyoid bone upwards, and projects the tongue.

Genio-hyoideus.[6]—*Origin*, from the posterior tubercle, inside of the chin. *Insertion*, into the body of the hyoid bone. *Use;* it draws it upwards and forwards.

Longus-colli.[3 5 6]—*Origin*, from the bodies of the three superior dorsal vertebræ, and the transverse processes of the five lower cervical. *Insertion*, into the bodies of all the cervical vertebræ. *Use;* it bends the neck forwards and to one side.

Fig. 58.

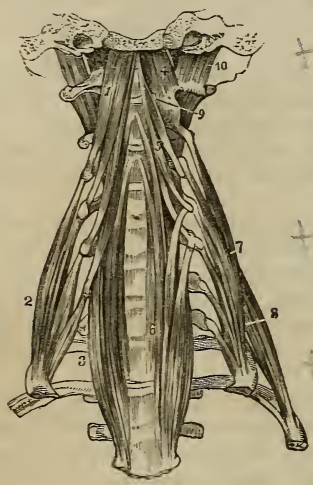

Rectus capitis anticus major.[1]—(See Fig. 58.) *Origin*, from the transverse processes of the third, fourth, and fifth cervical vertebræ. *Insertion*, into the basilar or cuneiform process of the occiput. *Use;* it bends the head forwards.

Rectus capitis anticus minor.[4]—*Origin*, from the atlas near its transverse process. *Insertion*, into the basilar process of the occiput. *Use;* it bends the head forwards.

Rectus capitis lateralis.[10]—*Origin*, from the transverse process of the atlas. *Insertion*, between the condyle and jugular eminence of the occipital bone. *Use;* it draws the head to one side.

Scalenus anticus.[2]—*Origin*, from the transverse processes of the fourth, fifth, and sixth cervical vertebræ, tendinously. *Insertion*, into the upper surface of the first rib in front of the groove for the subclavian artery. *Use;* it bends the neck forwards, or raises the first rib.

Scalenus medius.[7]—*Origin*, from the transverse processes of all the cervical vertebræ tendinously. *Insertion*, into the upper surface of the first rib, behind the groove for the artery. *Use;* same as last.

Scalenus posticus.[8]—*Origin*, from the transverse processes of the fifth and sixth cervical vertebræ. *Insertion*, into the upper face of the second rib beyond the tubercle. *Use;* it bends the neck and raises the second rib.

MUSCLES OF THE CHEST.

Pectoralis major.—Forms the cushion of the chest. *Origin*, from the two upper bones of the sternum, the sternal two-thirds of the

clavicle, the cartilages of the fifth and sixth ribs, and from the tendon of the external oblique muscle. *Insertion*, into the outer edge of the bicipital groove of the humerus. *Use;* it draws the arm inwards and forwards.

Pectoralis minor.[6]—*Origin*, from the third, fourth, and fifth ribs. *Insertion*, into the inner face of the extremity of the coracoid process of the scapula. *Use;* it draws the scapula inwards and downwards.

Fig. 59.

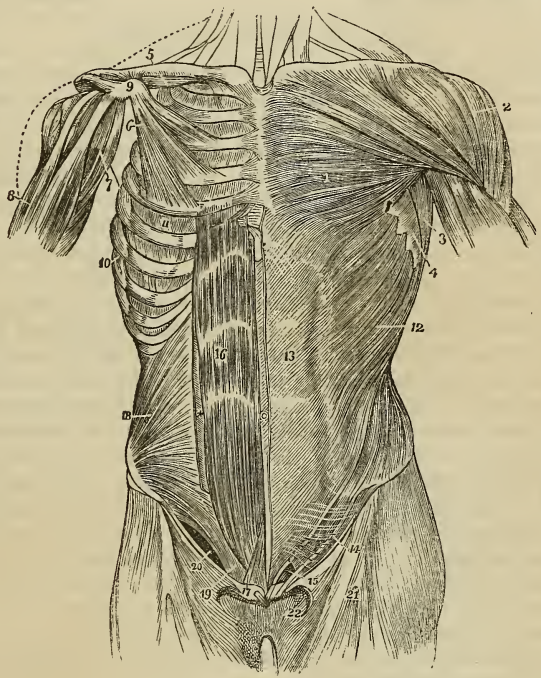

Subclavius.[5]—*Origin*, from the cartilage of the first rib. *Insertion*, into the inferior face of the clavicle. *Use.* It draws the clavicle downwards.

Serratus magnus, or anticus.[4]—*Origin*, from the nine upper ribs, five of its heads interdigitating with the external oblique muscle. *Insertion*, into the whole length of the base of the scapula. *Use.* It draws the scapula forwards.

Intercostales externi.[11]—There are eleven on each side. *Origin*, from the transverse process of the vertebra, and the inferior sharp

edge of the rib. *Insertion*, into the superior rounded edge of the rib below. The fibres pass obliquely downwards and forwards.

Intercostales interni.—Also eleven on each side. *Origin*, from the inferior edge of the rib, and costal cartilages. *Insertion*, into the superior rounded edge of the rib below, the fibres passing downwards and backwards. *Use.* To approximate the ribs.

Triangularis sterni.—Situated on the inner wall of the front of the chest. *Origin*, from the ensiform cartilage, and second bone of the sternum. *Insertion*, into the third, fourth, fifth, and sixth ribs. *Use.* To depress the ribs.

MUSCLES OF THE ABDOMEN.

Beneath the skin of the abdomen is the *fascia superficialis abdominis*, a layer of condensed cellular substance, varying in thickness in different individuals, and containing more or less fat. Its laminated character admits of its being dissected into several layers. In the groin it encloses the lymphatic glands, and is traversed at its lower part by the *arteria ad cutem abdominis;* it is thickened over the symphysis pubis, and constitutes the *mons veneris.*

Obliquus externus.[12]—*Origin*, from the eight inferior ribs, the first head being covered by the pectoralis major; the five superior heads interdigitate with those of the serratus anticus, and the three inferior, with those of the latissimus dorsi. The fibres pass obliquely downwards and forwards. *Insertion*, into the whole length of the linea alba, tendinously; into the anterior half or two-thirds of the crest of the ilium, by muscular and tendinous fibres; and into the body and crest of the pubes, forming thereby Poupart's ligament. As the tendinous fibres approach the pubes, they split, forming a triangular opening called the external abdominal ring;[13] through which passes in the male the spermatic cord, and in the female the round ligament of the uterus. The edges of this ring are called columns or pillars.—This ring is prevented from splitting still further, by some transverse tendinous fibres inserted into the crest of the pubis.[14] The external edge of that portion of the tendon is called Gimbernat's ligament. (Fig. 59.)

Use.—It compresses the viscera of the abdomen, and approximates the pelvis and thorax.

Obliquus internus.[15]—*Origin*, from the three inferior spinous processes of the lumbar vertebræ, and from all those of the sacrum, from the whole length of the middle lip of the crest of the ilium, and from the outer half of Poupart's ligament. *Insertion*, into the six inferior ribs, into the ensiform cartilage, into the whole length of the *linea alba*, and also tendinously into the pubes behind the external abdominal ring. At the linea semilunaris, the tendon splits into two laminæ, which thereby form a sheath for the rectus muscle; in the lower third or fourth of the muscle, both laminæ, however, pass in front, and include between them the pyramidalis.

Transversalis abdominis.—Is beneath the last. *Origin,* from the transverse processes of the last dorsal and four upper lumbar vertebræ, from the internal lip of the crest of the ilium, and from the external half of Poupart's ligament; it also arises from the cartilages of the six inferior ribs. *Insertion,* into the ensiform cartilage, linea alba, and pubes, in common with the internal oblique tendon. A portion of this common tendinous insertion is also into the crest of the pubes immediately behind the external abdominal ring, and thus the weakness at this part of the abdomen is in some measure protected.

Rectus abdominis.[16]—*Origin,* from the symphysis and body of the pubes. *Insertion,* into the ensiform cartilage, and into the cartilages of the fifth, sixth, and seventh ribs. This muscle gradually increases in breadth and has tendinous intersections called *lineæ transversæ,* which are three or four in number.

Pyramidalis.[17]—Is in front of the lower part of the rectus, and about three inches in length. *Origin,* from the body of the pubes. *Insertion,* into the linea alba. It is sometimes wanting.

Cremaster.—This muscle forms a muscular sheath for the cord and upper part of the testicle; before the descent of the testicle, it constitutes the inferior edge of the internal oblique and transversalis muscles, which are much blended at this part; hence its *origin* may be said to be the muscular portion of the lower edge of these muscles, and that its *insertion* is into the conjoined tendon of these muscles.

Fascia transversalis.—This fascia covers the abdomen, and lies under the muscles and in front of the peritoneum; it is continuous with the *iliac fascia,* which surrounds the posterior part of the peritoneum, and with the *pelvic fascia,* which surrounds that portion of peritoneum in the cavity of the pelvis. It is thin and tough, and near the groin possesses great density.

This fascia is an object of study, particularly on account of the *internal abdominal ring* being situated in it. This point is usually much misunderstood, partly from the use of the term *ring,* which gives rise to the idea that it is a hole or opening like the external ring, and partly from the variety and confusion of terms employed in its description. It may be said to be that portion of the fascia transversalis where it ceases to cover the abdomen and commences to cover the cord; here it is very thin, and an artificial or false dissection readily can form a ring or hole with a well-defined edge. But such does not exist in nature, for the fascia is continued from the abdomen upon the cord.

INGUINAL HERNIA.

Inguinal hernia is of two kinds; oblique or indirect, and direct or ventro-inguinal hernia. Oblique is by far the most common; and

in order to understand the anatomy of it, it will be necessary to bear in mind the arrangement of the parts previous to the descent of the testicle, the subsequent and natural condition, and also the alteration of the parts by the hernial protrusion.

Oblique inguinal hernia is a protrusion of intestine through a passage originally made by the escape of the testicle from the loins to the scrotum; and afterwards occupied by the spermatic cord. Until the seventh month of fœtal life the testicle reposes in the lumbar region beneath the kidney, but not within the cavity of the peritoneum. As yet there is no spermatic cord formed, the constituents, to wit, the artery, vein, duct, &c., each approaching the testicle separately. About this period the testicle ordinarily descends, by means of the *gubernaculum testis* a contractile structure attached to its inferior extremity, and is enveloped in the scrotum. In its passage it must come in contact with the various structures forming the parietes of the abdomen, viz., the peritoneum, fascia transversalis, the transversalis, internal and external oblique muscles, the superficial fascia, and the skin. Now each of these structures, with the exception of the external oblique muscle, will be found to form a covering for the testicle and cord, because it does not perforate them but pushes them before it; although these coverings may be modified in some degree, nevertheless there is a representation of every layer of the walls of the abdomen; and this is the case not only in the coverings of the testicle and cord, but also in the coverings of a hernia protrusion; hence, if a student understands the changes which take place in the descent of the testicle, he must necessarily understand the mode by which this kind of a hernial protrusion obtains its coverings.

Here we must caution students from attaching too much importance to words or terms used in description, for they vary with different writers; but let him keep constantly before his mind the thing itself, as if he were making a dissection; for by actual dissection he can understand it thoroughly, although he may not know the name of a single part.

Descent of the testicle —In the first place, by the contraction of the gubernaculum testis, the testicle is brought in contact with the peritoneum, and since it is not in the peritoneal cavity, it must necessarily push before it a doubled lamina of peritoneum. Thus the testicle gets a covering of serous membrane arranged as serous membranes always are; that is, one lamina covers the testicle, and the other lines the cavity in which it is contained, and it is called the *peritestis* or *tunica vaginalis testis.* The communication between the peritoneum and peritestis is afterwards obliterated, otherwise the bowel could readily pass down; and when this obliteration does not occur, and the bowel does pass down, it constitutes a variety of hernia, termed *congenital.* As the testicle descends, the spermatic artery,

vein, and vas deferens descend with it, and thus the cord is formed; the components are held together by means of cellular tissue, the remains of the canal of peritoneum, connecting the peritoneum and peritestis. Organs that have been of use in the system are never entirely absorbed, but converted into another, which serves a different purpose—as in the case of an artery when tied for aneurism, it becomes a cord; the umbilical vein becomes the ligamentum teres.

Now, the next structure with which the testicle comes in contact, is the fascia transversalis; let us follow this in its descent with the testicle, and observe the changes which it undergoes. It is not perforated as this (Fig. 60) and most pictures represent,[7] but pushed before the testicle, covering it and the cord. The point where this protrusion takes place, is midway between the anterior superior spinous process of the ilium and the pubes, and about an inch and a half above Poupart's ligament, and is called the *internal abdominal ring;* but there is no hole or opening unless made with a scalpel. The fascia is continuous from the abdomen upon the cord, although that portion covering the abdomen is tougher and thicker than that of the cord. If the cord is stretched, this portion of the fascia will resemble a funnel, and hence some call it the *infundibuliform fascia* or *internal spermatic fascia.* That portion which covers the testicle, assists in forming its cellular coat, which is termed by some *tunica vaginalis communis testis,* by others, the *fascia propria.*

Terms are matters of minor importance; the truth to be taught is, that the testicle, cord, and abdomen are invested by the same fasciæ, having different names and different thicknesses in different parts.

Fig. 60.

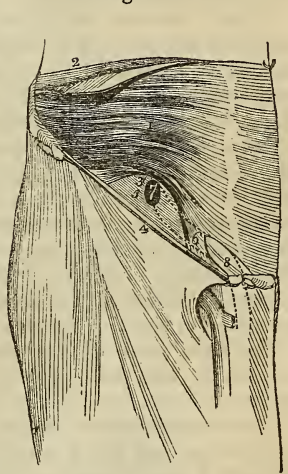

The next layer of the abdominal wall with which the testicle comes in contact is the *transversalis muscle.* At the lower part of the abdomen, the internal oblique is so much blended with the transversalis, that the two may be considered as having the same relation to the testicle in its deseent, and also to hernia. At the internal abdominal ring, the testicle, already covered by the peritoneum and fascia transversalis, comes in contact with these muscles; it does not perforate them, but pushes their conjoined lower edge before it, obtains for itself and cord a muscular covering,

which is the *cremaster* muscle; and this accounts for that looped appearance which the fibres of this muscle have upon the testicle; also, for the muscle being thicker upon the anterior part of the cord. These muscular fibres are very pale, and very scattered upon the lower part of the testicle, and form an imperfect covering for the testicle. When the cremaster is cut away from the transversalis and internal oblique, their inferior edge presents an arched appearance.

The tendon of the external oblique is the next structure opposing its descent, and since this is very tough, it is not pushed before the testicle; but the testicle passes obliquely downwards and inwards for an inch and a half, until it gets opposite the external abdominal ring, which is a hole, and at which it emerges between its columns or pillars. The fact, that in health these two rings are not opposite contributes much to the strength of the arrangement, and prevents the more frequent occurrence of hernia, which is much favoured by a deficiency in the fibrous character of the tendon of the external oblique.

The space between these two rings, is called the *inguinal*, *abdominal*, or *spermatic canal*. It is bounded anteriorly by the inferior edge of the internal oblique and transversalis muscles, the tendon of the external oblique, the superficial fascia, and skin; posteriorly by the transversalis fascia, and the conjoined tendon of the transversalis and internal oblique muscles; inferiorly, by Poupart's ligament.

When the hernia does not emerge from this canal, it is called a *concealed* inguinal hernia.

At the external abdominal ring, the testicle, with its covering, comes in contact with the superficial fascia, which has already been described as consisting of numerous laminæ, one of which can readily be shown to extend between the columns of the ring, and hence it is called the *intercolumnar fascia*, by some, by others, the *external spermatic*, &c. That portion of the fascia transversalis engaged in forming the cellular coat of the testicle, is actually blended with the superficial fascia of the testicle, on account of the intervening muscular structure, that of the cremaster being deficient in some parts, and very spare in others.

The skin is, of course, readily traced from the abdomen to the scrotum, although in the scrotum it is modified by the dartos, which, according to some, is an expansion of the gubernaculum testis.

We have seen the changes which take place in the descent of the testicle, and are now prepared to consider the escape of the intestine.

The convolution or knuckle of intestine first presses against the peritoneum, and being contained within the cavity, can only push before it a single lamina. This portion of the peritoneum always

forms the *hernial sac*, which gradually increases in size and thickness. In this variety of hernia (oblique inguinal), the protrusion takes place at the internal ring; the sac must then necessarily be covered by the transversalis fascia and cremaster muscle, and after passing obliquely down the inguinal canal, it emerges at the external abdominal ring, where it receives an investment of superficial fascia and skin.

That portion of the superficial fascia which fills up the external abdominal ring between its columns, and called intercolumnar, when pressed against by the protrusion is thickened and expanded.

When a hernia exists, the connexion between this fascia and the edges of the external abdominal ring is so close that the tendon of the external oblique seems to be continued into the fascia; and some have therefore considered it as derived from the tendon, and not from the superficial fascia, as we have described; and indeed we frequently find, even when no hernia exists, a thin layer extending from the tendon of the external oblique to the spermatic cord.

Hence, in the operation for hernia, the following layers are cut through :—

Skin, superficial fascia, intercolumnar fascia, cremaster muscle, transversalis fascia, and *the hernial sac.*

That portion of the fascia transversalis which covers the hernial sac is also thickened, and often called the *infundibuliform fascia,* or the *internal spermatic fascia.*

In the dissection of a hernial sac, we will find alterations in thickness and colour, the consideration of which properly belongs to the surgical part of this work.

Direct or *ventro-inguinal hernia* consists of a protrusion directly at the external abdominal ring, and of course it does not pass through the canal. The coverings are the *skin, superficial fascia, intercolumnar fascia,* the common *tendon* of the *internal oblique* and *transversalis* muscles, *transversalis fascia,* and hernial *sac.*

This variety is not of so frequent occurrence, on account of the insertion of the tendon of the internal oblique and transversalis into the pubes immediately behind the external abdominal ring, which protects this opening, and therefore it must be ruptured or expanded when a protrusion takes place at this ring; when it is ruptured, of course this covering of the sac does not exist.

MUSCLES OF THE UPPER AND POSTERIOR PART OF THE ABDOMEN.

Diaphragm.—This muscle forms the septum between the thorax and abdomen; it consists of two parts, a greater and lesser muscle.

Fig. 61.

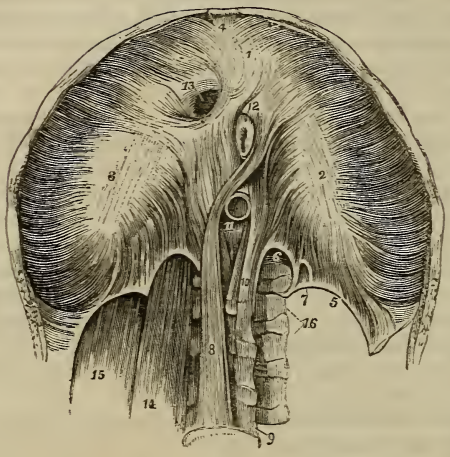

The *greater*[1 2 3] muscle arises from the ensiform cartilage, from the ligamentum arcuatum,[5] which is a tense ligament passing from the root of the transverse process of the first lumbar vertebra to the inferior part of the middle of the twelfth rib, and from six inferior ribs; the fibres converge to the cordiform tendon, which is in the centre. Between its costal and ensiform origin there is a small triangular fissure filled up with fat, which sometimes leaves an opening for hernia. The *lesser*[8 10] muscle consists of two bellies, which are called *crura*, the right of which is the larger. *Origin*, from the second, third, and fourth lumbar vertebræ. *Insertion*, into the cordiform tendon.

There are *three openings* in the diaphragm; one in the tendinous centre,[13] called *foramen quadratum*, which transmits the ascending *vena cava;* another, an elliptical muscular opening,[12] called *foramen œsophageum*, through which passes the œsophagus, and the par vagum nerves; and the third, the *hiatus aorticus*,[11] which is between the crura, and in front of the vertebra; through it pass the aorta, the thoracic duct, the azygos vein, and the great splanchnic nerve. *Use;* it widens the thoracic, and diminishes the abdominal cavity.

Quadratus lumborum.—*Origin*,[15] from the crest of the ilium. *Insertion*, into the transverse processes of the last dorsal and all the lumbar vertebræ, and also into the last rib beneath the ligamentum arcuatum. *Use;* it bends the loins to one side.

Psoas parvus.—Not always present. *Origin*, from the last dorsal and first lumbar vertebræ. *Insertion*, by a long tendon, into the *crest of the pubes* and *fascia iliaca*.

Psoas magnus.[14]—*Origin*, from the transverse processes of all the lumbar vertebræ, and from the bodies of the four upper lumbar and last dorsal vertebræ. *Insertion*, into the lesser trochanter of the femur, and into one inch below it.

Iliacus internus.—*Origin*, from the transverse process of the

last lumbar vertebra, from the costa and crest of the ilium, and from the capsule of the hip joint. *Insertion*, into the tendon of the psoas magnus. *Use;* the action of the last two muscles is the same, to bend the body forwards and draw the thigh upwards.

MUSCLES OF THE BACK.

Trapezius.[1]—*Origin*, from the superior semicircular ridge of the occiput, from all the spinous processes of the neck, by means of the ligamentum nuchæ, and from all those of the back. *Insertion*, into the external third of the clavicle, into the acromion process, and spine of the scapula. *Use;* it draws the scapula towards the spine.

Fig. 62.

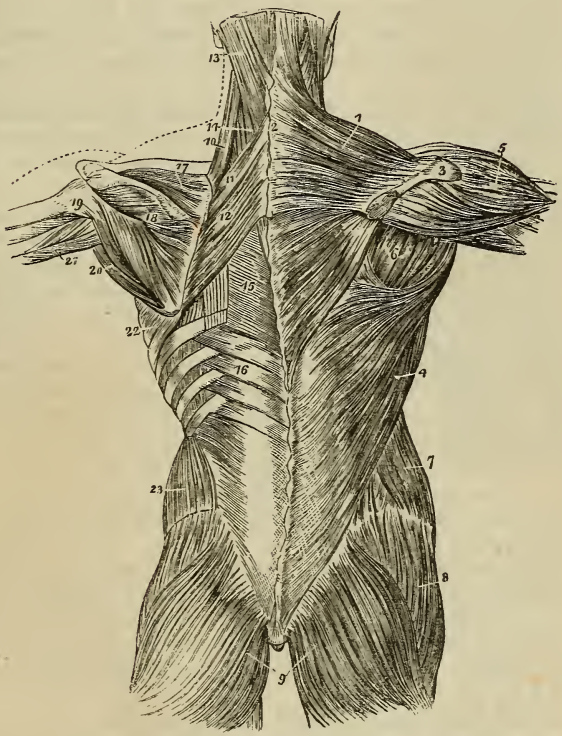

Latissimus dorsi.[2]—*Origin*, from the seven inferior spinous processes of the back, and from all those of the loins and sacrum, also

from four inferior ribs, by heads which interdigitate with those of the external oblique. *Insertion*, by a thick flat tendon, in common with the *teres major*, into the posterior ridge of the bicipital groove. *Use;* it draws the humerus downwards and backwards.

Serratus posticus inferior.[16]—*Origin*, from the two inferior spinous processes of the back, and the three superior of the loins. *Insertion*, into the last four ribs. *Use;* it draws the ribs downwards.

Rhomboideus minor.[11]—*Origin*, from the three inferior spinous processes of the neck. *Insertion*, into the base of the scapula opposite the spine.

Rhomboideus major.[12]—*Origin*, from the spinous processes of the last cervical, and of the four superior dorsal vertebræ. *Insertion*, into the base of the scapula below the spine. *Use;* the last two draw the scapula upwards and backwards.

Serratus posticus superior.—*Origin*, from the three inferior spinous processes of the neck, and the two superior of the back. *Insertion*, into the second, third, fourth, and fifth ribs. *Use;* it draws the ribs upwards.

Levator anguli scapulæ.[10]—*Origin*, from the transverse processes of the three, four, or five superior cervical vertebræ. *Insertion*, into the angle of the scapula, and its base above the spine. *Use;* it draws the scapula upwards.

Splenius.[13] [14]—It consists of two parts; splenius capitis and splenius colli. *Origin*, from the spinous processes of the five inferior cervical and the four superior dorsal vertebræ. *Insertion*, into the occipital bone, between the two semicircular ridges, and into the transverse processes of the two superior cervical vertebræ. *Use;* draws the head and neck backwards.

Sacro-lumbalis and *longissimus dorsi.*—These two muscles arise in common (Fig. 63.) *Origin*, from the spinous and transverse processes of the loins and sacrum, and from the crest of the ilium. The first[2] is on the outer side. *Insertion*, into the angles of the rib. The latter[3] is nearest the spine. *Insertion*, into all the transverse processes of the back except the first, and into all the ribs beyond their tubercles, except the last two. *Use;* to keep the spine erect, and draw down the ribs.

Accessorii ad sacro-lumbalem.—Are muscular slips arising from the eight lower ribs and continued into the sacro-lumbalis.

Spinalis dorsi.[4]—*Origin*, from the three inferior spinous processes of the back, and two superior of the loins. *Insertion*, into the nine superior spinous processes of the back, except the first. *Use;* to keep the spine erect.

Cervicalis descendens.[5]—*Origin*, from the four superior ribs. *Insertion*, into the fourth, fifth, and sixth transverse processes of the neck.

Transversalis cervicis.[6] [9]—*Origin*, from the five superior trans-

verse processes of the back. *Insertion,* into the five middle transverse processes of the neck. *Use;* the two last draw the neck backward.

Fig. 63.

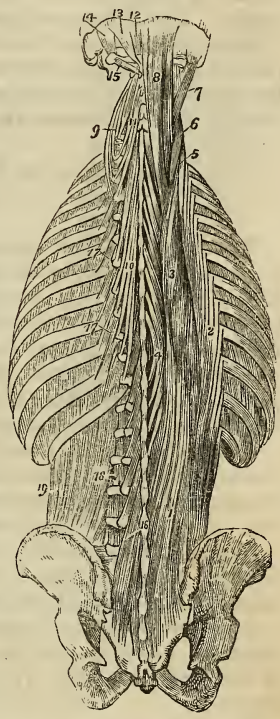

Trachelo-mastoid.[7] — *Origin,* from the three superior transverse processes of the back and from the five inferior transverse processes of the neck. *Insertion,* into the mastoid process.

Complexus.[8] — *Origin,* from the transverse processes of the four inferior cervical and seven superior dorsal, and from the spinous process of the first dorsal vertebra. *Insertion,* into the occiput between its semicircular ridges. *Use;* the two last draw the head backward.

Semi-spinalis cervicis.[11] — *Origin,* from the six superior transverse processes of the back. *Insertion,* into the spinous processes of the five middle cervical vertebræ.

Semi-spinalis dorsi.[10] — *Origin,* from the transverse processes of the seventh, eighth, ninth, and tenth dorsal vertebræ. *Insertion,* into the spinous processes of the two lower cervical, and five upper dorsal vertebræ.

Multifidus spinæ.[16] — *Origin,* from the posterior surface of the sacrum, and the back part of the ilium, and from the oblique and transverse processes of all the vertebræ of the loins and back, and of the four inferior of the neck. *Insertion,* into the spinous processes of all the vertebræ of the loins and back, and of the five inferior of the neck. *Use;* the three last twist the spine when acting without their fellows.

Rectus capitis posticus major. — *Origin,* from the spinous process of the dentata. *Insertion,* into the occiput at its superior semicircular ridge, and below it. *Use;* it turns the head.

Rectus capitis posticus minor. — *Origin,* from the tubercle of the atlas. *Insertion,* into the occiput, at the inferior semicircular ridge, and below it.

Obliquus superior. — *Origin,* from the transverse process of the atlas. *Insertion,* into the outer end of the inferior semicircular ridge of the occiput.

Obliquus inferior. — *Origin,* from the spinous process of the dentata. *Insertion,* into the transverse process of the atlas.

Interspinales.—Between the spinous processes of all the vertebræ. In the neck, they are double: in the back, tendinous; in the loins, single and well-marked.

Inter-transversarii.[18]—Between all the transverse processes. In the neck, double; in the back, tendinous; in the loins fleshy and single. *Use.* To approximate these processes.

Levatores costarum.[17]—*Origin*, from the transverse processes of the last cervical and eleven upper dorsal vertebræ. *Insertion*, into the upper edge of the rib below, and sometimes into the second rib below. *Use.* To elevate the ribs.

MUSCLES OF THE SHOULDER AND ARM.

FASCIA.

The brachial fascia covers the muscles of the upper extremity, commencing at the spine of the scapula and clavicle. Upon the deltoid it is thin. At the elbow it sends several processes to the bone, which serve for the origin of muscles, and in front it receives a portion of tendon from the biceps muscle, which renders it tense.

At the wrist it forms the anterior and posterior annular ligaments, which bind down the tendons of the hand, and in the hand it forms the palmar aponeurosis.

Deltoid.[5]—*Origin*, from the spine of the scapula, its acromion process, and the external third of the clavicle. *Insertion*, into a triangular roughness near the middle of the outer side of the humerus. *Use.* It raises the humerus. (Fig. 62.)

Supra-spinatus.[17]—*Origin*, from the whole of the fossa supra-spinata. *Insertion*, into the inner facet of the greater tuberosity of the humerus. *Use.* It raises the arm and turns it outwards.

Infra-spinatus.[18]—*Origin*, from the whole of the fossa infra-spinata. *Insertion*, into the middle facet of the greater tuberosity of the humerus. *Use.* It rotates the humerus outwards and backwards.

Teres minor.[19]—*Origin*, from the lesser costa of the scapula. *Insertion*, into the outer facet of the greater tuberosity of the humerus. *Use.* It rotates the humerus outwards, and draws it downwards and backwards.

Teres major.[20]—*Origin*, from the posterior surface of the inferior angle of the scapula, and a part of its lesser costa. *Insertion*, into the posterior edge of the bicipital groove of the humerus in common with the tendon of the latissimus dorsi. *Use.* It rotates the humerus inwards and draws it downwards and backwards.

Subscapularis.[4] (Fig. 64.) *Origin*, from the whole of the costa of the scapula. *Insertion*, into the lesser tuberosity of the humerus. *Use.* It rotates the humerus inwards, and draws it downwards.

Biceps flexor cubiti.[7]—*Origin*, from the superior extremity of the

glenoid cavity, by a long tendon which passes through the joint and bicipital groove, and by a short head from the coracoid process of the scapula. *Insertion*, into the posterior and inferior parts of the tubercle of the radius, and into the brachial fascia. *Use.* It flexes the fore-arm.

Fig. 64.

Coraco-brachialis.[6] — *Origin*, from the middle facet of the coracoid process of the scapula, in common with the short head of the biceps. *Insertion*, into the middle of the os humeri by a rough ridge on its internal side. *Use.* It draws the arm upwards and inwards.

Brachialis Internus.[9] — *Origin*, from the anterior and lower half of the os humeri. *Insertion*, in front of the base of the coronoid process of the ulna. *Use.* It flexes the fore-arm.

Triceps extensor cubiti.[10] — *Origin*, by three heads; the first or longus, is from the inferior part of the glenoid cavity. The second or external, is from a ridge from the back part of the os humeri, just below its head; and the third or brevis, is from the inner side of the os humeri, near the bicipital groove. *Insertion*, into the olecranon process of the ulna. *Use.* It extends the fore-arm.

Anconeus.[11] (Fig. 67.) — *Origin*, from the external condyle of the humerus. *Insertion*, into the outer side of the ulna below the olecranon. *Use.* It extends the fore-arm.

MUSCLES OF THE FORE-ARM.

These are eighteen in number, eight of which are on the front of the arm, and are flexors; for the most part they arise from the internal condyle. The remaining ten are extensors, and arise for the most part from the external condyle.

Pronator radii teres.[4] (Fig. 65.) — *Origin*, from the internal condyle of the humerus, and the coronoid process of the ulna. *Insertion*, into the middle and external side of the radius. *Use.* It rotates the hand inwards.

Flexor carpi radialis.[5] — *Origin*, from the internal condyle of the humerus, the brachial fascia, and the inter-muscular septa. *Insertion*, into the base of the metacarpal bone of the index finger. *Use;* it flexes the hand at the wrist. (Fig. 65.)

Palmaris longus.[6] — Is sometimes deficient. *Origin*, from the

internal condyle. *Insertion,* into the annular ligament and palmar aponeurosis. *Use ;* it bends the hand.

Fig. 65. Fig. 66.

Flexor carpi ulnaris.[8]—*Origin,* from the internal condyle, from the ridge at the inner side of the ulna and from the olecranon. *Insertion,* into the pisiform bone and into the base of the metacarpal bone of the little finger. *Use;* it flexes the hand.

Flexor sublimis digitorum perforatus.[7]—*Origin,* from the internal condyle of the humerus, the coronoid process of the ulna, and the tubercle of the radius. *Insertion,* by four split tendons into the second phalanges of the fingers. *Use;* it bends the hand and fingers.

Flexor profundus digitorum perforans.[4] (Fig. 66.)—*Origin,* from the ulna by its anterior flat surface, from its coronoid process, and from the interosseous ligament. *Insertion,* by four tendons, which, passing through the perforations in the tendons of the flexor sublimis, are inserted into the third phalanges of the fingers.

Flexor longus pollicis.[5]—*Origin,* from the internal condyle of the humerus, and the middle two-thirds of the radius, and a part of the interosseous ligament. *Insertion,* into the base of the second phalanx of the thumb. (Fig. 66.)

Pronator quadratus.[6]—*Origin,* from the inner border and anterior surface of the ulna, near its lower extremity. *Insertion,* into the corresponding surface of the radius. *Use;* it rotates the radius inwards.

Fig. 67.

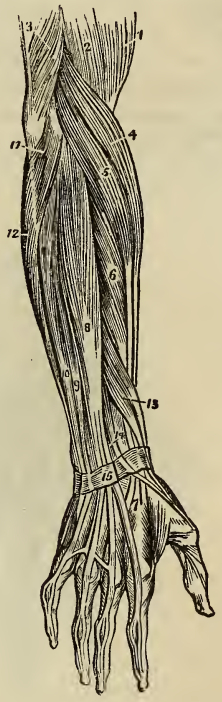

Supinator radii longus.[4] (Fig. 67.)—*Origin,* from the ridge leading to the external condyle of the humerus. *Insertion,* into the radius just above its styloid process. *Use;* it rotates the radius outwards.

Extensor carpi radialis longior.[5]—(Fig. 67.) *Origin,* from the ridge of the external condyle of the humerus. *Insertion,* into the posterior part of the base of the *metacarpal* bone of the forefinger.

Extensor carpi radialis brevior.[6]—*Origin,* from the external condyle of the humerus, and from the external lateral ligament. *Insertion,* into the posterior part of the base of the metacarpal bone of the middle finger.

Extensor carpi ulnaris.[10]—*Origin,* from the external condyle and the brachial fascia. *Insertion,* into the base of the metacarpal bone of the little finger. *Use;* the last three extend the hand.

Extensor digitorum communis.[8]—*Origin,* from the external condyle. *Insertion,* by four tendons which are connected by slips previous to their insertion into all the phalanges of the fingers. *Use;* it extends the joints of the fingers.

Supinator radii brevis.—*Origin,* from the external condyle, and from a ridge of the ulna on its posterior surface. *Insertion,* into the radius between its tubercle and the insertion of the pronator. *Use;* it rotates the radius outwards.

Extensor ossis metacarpi pollicis manus.—*Origin,* from the posterior surface of the ulna, from the interosseous ligament, and a part of the radius. *Insertion,* into the base of the metacarpal bone of the thumb, and into the trapezium.

Extensor minor pollicis manus.[13]—*Origin,* from the back of the ulna below its middle, and from the interosseous ligament. *Insertion,* into the first phalanx of the thumb.

Extensor major pollicis manus.[14]—*Origin*, from the back of the ulna above its middle, from the interosseous ligament, and from the back of the radius. *Insertion*, into the base of the second phalanx of the thumb. *Use;* these last three extend the thumb.

Indicator.—*Origin*, from the back of the ulna, and interosseous ligament. *Insertion*, into the base of the first phalanx of the index finger. *Use;* it extends the fore-finger.

MUSCLES OF THE HAND.

Palmaris brevis.—*Origin*, from the anterior ligament of the wrist, and palmar aponeurosis. *Insertion*, into the skin at the inner edge of the hand. *Use;* it contracts the skin.

Fig. 68.

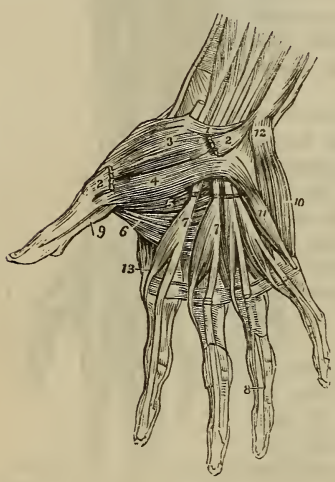

Lumbricales.[7] — These are four in number and resemble earth-worms. *Origin*, from the the tendons of the flexor profundus. *Insertion*, into the radial side of the base of the first phalanx of each finger. *Use;* they assist in bending the fingers. (Fig. 68.)

Abductor pollicis manus.[2]—*Origin*, from the annular ligament, trapezium, and scaphoid bones. *Insertion*, into the base of the first phalanx of the thumb. *Use;* it draws the thumb from the fingers.

Opponens pollicis.[5]—*Origin*, from the trapezium and annular ligament. *Insertion*, into the radial edge of the metacarpal bone, from its base to its head. *Use;* it draws the metacarpal bone inwards.

Flexor brevis pollicis manus.[4 5]—It consists of two bellies. The external *arises* from the trapezium and trapezoides, and the annular ligament; and it is inserted into the outer side of the first phalanx of the thumb. The internal head *arises* from the magnum and unciform, and the metacarpal bone of the little finger; and it is inserted into the inner side of the base of the first phalanx of the thumb. The sesamoid bones are included in these tendons.

Adductor pollicis manus.[6]—*Origin*, from the metacarpal bone of the middle finger between its base and its head. *Insertion*, into the base of the first phalanx of the thumb. *Use;* it draws the thumb towards the fingers.

Abductor minimi digiti manus.[10]—*Origin*, from the pisiform

bone, and annular ligament. *Insertion*, into the ulnar side of the base of the first phalanx of the little finger. *Use;* it draws the little finger from the rest.

Flexor parvus minimi digiti.[11]—*Origin*, from the unciform process of the unciform bone, and annular ligament. *Insertion* into the ulnar side of the base of the first phalanx of the little finger. *Use;* it bends the little finger.

Adductor metacarpi minimi digiti.—*Origin*, from the unciform process and annular ligament. *Insertion*, into the metacarpal bone of the little finger, from its base to its head. *Use;* it brings the metacarpal bone towards the wrist.

Interosseous muscles.—These are seven in number; three of which are on the *palmar* side, and four on the *dorsal* side. The palmar interossei are *adductors*, the dorsal are *abductors* with reference to the median line of the hand.

Fig. 69.

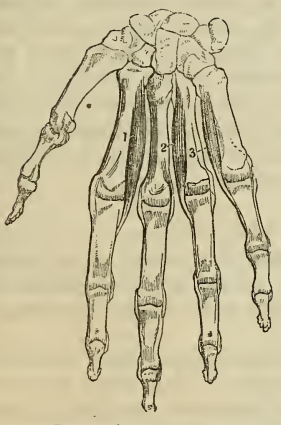

Fig. 70.

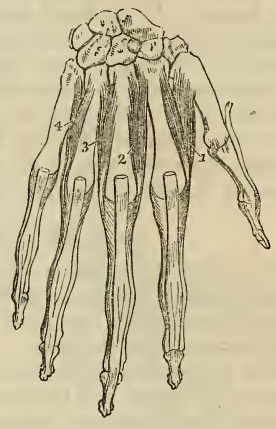

The *palmar interosseous muscles.* (Fig. 69.)—These arise from the base of the metacarpal bone of one finger, and are inserted into the base of the first phalanx of the same finger. The first belongs to the index finger,[1] the second to the ring finger,[2] and the third to the little finger.[3]

The *dorsal interosseous* are penniform, arising by two heads from adjoining sides of the metacarpal bones. (Fig. 70.) They are inserted into the bases of the first phalanges; the first into the index finger,[1] the second and third into the middle finger,[2 3] compensating its exclusion from the palmar group; the fourth into the ring finger.[4]

The diversified and confused description of these muscles by different authors, is owing to the use of terms that are not significant, a want of proper classification, and the dividing of one muscle in

two, and calling the different portions of it by different names; thus, some enumerate four *palmar* and three *dorsal* interossei, together with the muscle called *abductor indicis;* others, again, enumerate four palmar and four dorsal. The principle of classification should be with regard to their *action.* Whether they are abductors or adductors, with reference to an axis passing through the middle finger. If the first dorsal interosseous is split into two muscles, and that portion arising from the metacarpal bone of the thumb, is called the *abductor indicis,* and the remaining portion counted among the palmar interossei, the various modes of classifying these muscles, can easily be understood.

MUSCLES OF THE LOWER EXTREMITY.

The lower extremity is covered by a dense fascia called *fascia lata,* which commences at the crest of the ilium, and extending over the glutei muscles, reaches to the foot. In the front of the thigh it is termed *iliac* and *pubic,* with reference to its proximity to these bones. At the knee, it forms a general covering, called the *involucrum;* in the leg it is termed the *crural fascia;* in front of the ankle it constitutes the *annular ligament,* which binds down the extensor tendons; under the sinuosity of the os calcis, it binds down the flexor tendons in the form of the *ligamentum laciniatum,* or plaited ligament; finally, it terminates in the *plantar fascia,* that firm aponeurosis upon the sole of the foot. From it are formed numerous sheaths for muscles and tendons.

ANATOMY OF FEMORAL HERNIA.

This variety of hernia is a protrusion of intestine at an opening near the passage of the large vessels to and from the thigh. We shall at first describe the parts as they occur upon dissection, and then the descent of the gut.

Upon the removal of the skin from the upper portion of the thigh the *superficial fascia* is brought into view. This fascia is a continuation of the superficial fascia of the abdomen, and like it is capable of being dissected in laminæ. In the groin it contains numerous lymphatic glands. It is traversed by the *saphena vein,* which enters the femoral vein, through the *saphenous opening* of the fascia lata, about an inch below Poupart's ligament.

Having removed this fascia we bring into view the *fascia lata* of the thigh. This fascia is of a pearly white colour and very dense structure. It consists of two portions, the sartorial and pectineal. The *sartorial* portion[1] is upon the iliac side, and is connected at its upper part with Poupart's ligament. It passes in front of the sheath of the vessels, and has a crescentic edge on its inner side, called the *falciform* process. This process limits the saphenous opening on its outer side; and in order that this edge should be distinctly seen, a layer of superficial fascia with which it is continuous must be

carefully removed; this portion of superficial fascia which fills up the saphenous opening is often called *cribriform fascia.* (See Fig. 60.)

The superior horn of this crescentic falciform process is twisted and inserted in the crest of the pubes, external to, but continuous with, Gimbernat's ligament, and is called *Hey's* ligament.

The *pectineal* portion of the fascia lata is upon the pubic side; it is thinner than the sartorial and passes behind the sheath of the vessels.

The sheath of the vessels is formed of condensed cellular tissue, and may be considered a prolongation of the fascia transversalis and fascia iliaca. It is usually compared to the tubular portion of a funnel; the abdominal portions of these fasciæ constituting the larger and upper part of the funnel. Numerous perforations exist in the sheath of the vessels for the passage of veins and absorbents, which renders it cribriform. One of these perforations can be seen where the sheath is laid open, and also the saphena vein entering the femoral vein.[12] Since the artery[12] and vein[12] are cylinders, it must be evident that there must be some structure filling up the intervening spaces, and also the space[15] between the vein and Gimbernat's ligament,[16] or else there would be a deficiency of structure. Now this space is the *crural ring,*[15] and is filled up with loose cellular tissue and a lymphatic gland. This cellular tissue is called by some the *crural septum,* by others *fascia propria* and *cribriform fascia. A* weakness of this septum between the cavity and tube of the funnel predisposes to hernia. The crural or femoral ring is *bounded* in front by Poupart's ligament; behind, by the bone; on the inside by Hey's and Gimbernat's ligament; on the outside by the vein. The femoral vessels,[11 12] with their sheath,[13] together with the iliacus internus[7] and psoas magnus[9] muscle, pass out under Poupart's ligament, and thus fill the crural arch.

Fig. 71.

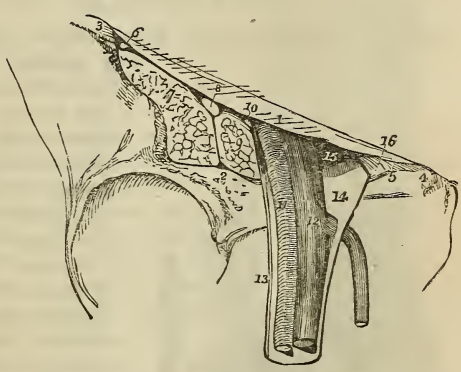

The intestine in femoral hernia pursues the following course. The peritoneum, as in all other instances, is at first distended and forms the hernial sac; this distension takes place at the crural ring,

this being the only spot where it can occur under the crural arch; the *crural septum* or fascia propria is now stretched and thickened; gradually yielding, it forms the next covering of the gut. With these it descends the sheath of the vessels, and when it gets below the falciform process, emerges at one of the foramina for veins or absorbents; then it comes in contact with the superficial fascia, which forms another covering, and the skin forms the last.

In reaching the intestine by an operation for hernia, the order of coverings would be first, the *skin*, second, the *superficial fascia*, including that portion of it which some call *cribriform fascia*, third, the *fascia propria*, which was originally the crural septum, which some call cribriform fascia, and fourth, the *hernial sac*, containing the protruding intestine. Much alteration of structure would of course exist by the parts becoming thicker and more laminated. In some instances the foramen of the sheath is not sufficiently large, and then the sheath is distended and consolidated with the other coverings. Many restrict the term *fascia propria* to this consolidated covering.

A femoral hernia may be concealed either above or below the saphenous opening; then of course the fascia lata will also form one of its coverings. (See SURGERY.)

MUSCLES OF THE HIP AND THIGH.

Gluteus maximus.[9] (Fig. 62)—*Origin.* From the crest and from a portion of the dorsum of the ilium, from the sides of the sacrum and coccyx, and from the greater sacro-sciatic ligament. *Insertion.* Into the upper third of the linea aspera, and into the fascia femoris. *Use.* It draws the thigh backwards and keeps the trunk erect.

Fig. 72.

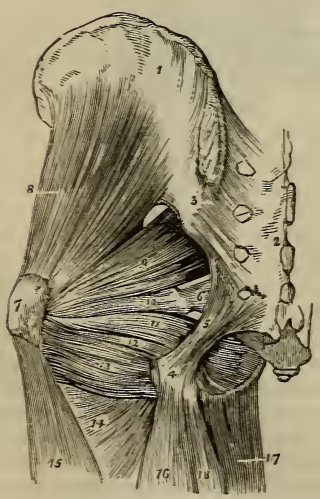

Gluteus medius.[8] (Fig. 62.)—*Origin.* From the dorsum of the ilium between the crest and semicircular ridge, from between the anterior spinous processes, and from the fascia femoris. *Insertion.* Into the upper and outer surface of the trochanter major. *Use;* it draws the thigh backwards and outwards.

Gluteus minimus.[8] (Fig. 72.)—*Origin.* From the dorsum of the ilium, between the semicircular ridge and the capsular ligament.

Insertion. Into the trochanter major in front and below that of the medius. *Use.* It abducts and rotates the thigh inwards.

Pyriformis.[9]—*Origin.* From the second, third, and fourth bones of the sacrum. *Insertion.* Into top of the trochanter major. *Use.* It rotates the limb outwards.

Gemini.[10] [12]—These are two in number; the superior arises from the spinous process of the ischium, and the inferior from the tuberosity of the ischium; both are inserted in common with the tendon of the obturator internus.

Obturator internus.[11]—*Origin.* From the margin of the thyroid foramen, the internal surface of the thyroid ligament, and from the fascia iliaca. *Insertion.* Into the digital fossa of the femur.

Fig. 73.

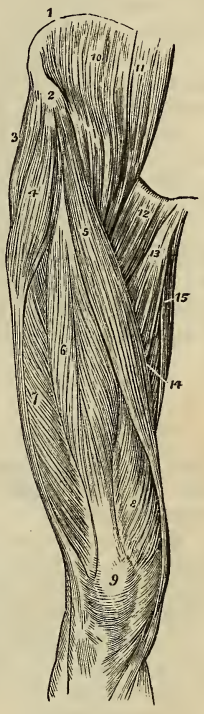

Quadratus femoris.[13]—*Origin.* From the tuberosity of the ischium. *Insertion.* Into the femur between the two trochanters.

Obturator externus.—*Origin.* From the anterior margin of the thyroid foramen, and ligament. *Insertion.* Into the digital fossa at the root of the trochanter major. *Use.* The last four rotate the thigh outwards.

Biceps flexor cruris.[16]—*Origin.* By a long head in common with the semi-tendinosus from the tuberosity of the ischium, and by a short fleshy one from the lower part of the linea aspera. *Insertion.* Into the head of the fibula.

Semi-tendinosus.[18]—*Origin.* From the tuberosity of the ischium. *Insertion.* Into the side of the head of the tibia just below its tubercle.

Semi-membranosus.—*Origin.* From the external part of the tuberosity of the ischium. *Insertion.* Into a groove at the posterior and internal side of the head of the tibia, and it is also connected with the ligament of Winslow and the external condyle of the femur.

Tensor vaginæ femoris.[4]—(Fig. 73.) *Origin.* From the anterior superior spinous process of the ilium. *Insertion.* Into the fascia or sheath of the thigh.

Sartorius.[5]—*Origin.* From the anterior superior spinous process of the ilium. *Insertion.* Into the inner side of the head of the tibia. *Use.* It bends the leg and draws it inwards. It is the longest muscle of the body.

Rectus femoris.[6]—*Origin.* By two tendons, one from the anterior inferior spinous process of the ilium, and the other from the edge

of the acetabulum. *Insertion.* Into the upper surface of the patella.

Vastus externus.[7]—*Origin.* From the linea aspera, and trochanter major. *Insertion.* Into the upper and external part of the patella.

Vastus internus.[8]—*Origin.* From the linea aspera in its whole length, covering the inside of the thigh. *Insertion.* Into the common tendon of the patella.

Cruræus.—*Origin.* From the anterior part of the femur as well as from the linea aspera. *Insertion.* Into the patella.

These four last muscles, often called the *quadriceps femoris,* form a common tendon in which is placed the patella, before it is inserted into the tubercle of the tibia. It extends the leg.

Gracilis.[15]—*Origin.* From the body and ramus of the pubes. *Insertion.* Into the inside of the head of the tibia.

Pectineus.[12]—*Origin.* From the crest of the pubes, and the triangular face in front of it. *Insertion.* Into the linea aspera below the trochanter minor.

Adductor longus.[13]—*Origin.* From the body of the pubes. *Insertion.* Into the middle third of the linea aspera.

Adductor brevis.—*Origin.* From the body and ramus of the pubes. *Insertion.* Into the upper third of the linea aspera.

Adductor magnus.[14]—*Origin.* From the body and ramus of the pubes, and from the ramus of the ischium. *Insertion.* Into the whole length of the linea aspera. At the junction of the middle and lower thirds of its insertion it is perforated by the femoral artery. *Use.* These four last draw the thigh forwards and inwards.

MUSCLES OF THE LEG.

Tibialis anticus[3] (Fig. 74.)—*Origin,* from the outer side and head of the tibia and from the interosseous ligament. *Insertion,* into the base of the internal cuneiform bone, and base of the first metatarsal bone.

Extensor Longus Digitorum Pedis.—*Origin,* from the head of the fibula, the head of the tibia, and from a portion of the interosseous ligament, and edge of the fibula. *Insertion,* by four tendons into the phalanges of the four lesser toes.

Peroneus Tertius.[6]—*Origin,* from the anterior angle of the fibula, below its middle. *Insertion,* into the upper surface of the base of the metatarsal bone of the little toe. It looks like a portion of the last-named muscle.

Extensor Proprius Pollicis Pedis.[5]—*Origin,* from the lower two-thirds of the fibula and interosseous ligament. *Insertion,* into the bases of the first and second phalanges of the great toe. *Use;* it extends the great toe.

Peroneous Longus.[7]—*Origin,* from the head and upper third of

the outer side of the fibula. *Insertion,* into the base of the metatarsal bone of the great toe. *Use;* it extends the foot and inclines the sole outwards.

Fig. 74.

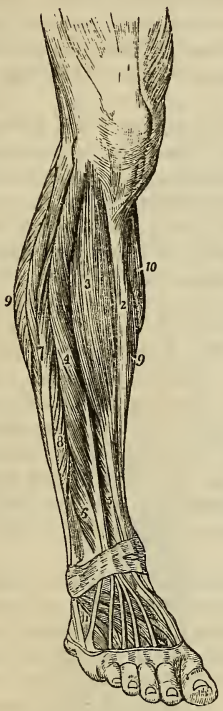

Fig. 75.

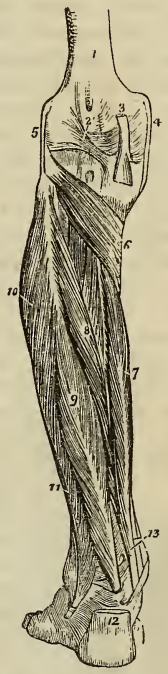

Peroneus Brevis.[8] — *Origin,* from the lower two-thirds of the outer surface of the fibula. *Insertion,* into the base of the metatarsal bone of the little toe. *Use;* it extends the foot.

Gastrocnemius.—*Origin,* by two heads from the condyles of the femur. *Insertion,* by the *tendo Achillis* into the tuberosity of the os calcis.

Soleus.—*Origin,* from the upper two thirds of the posterior part of the fibula, and the middle third of the tibia. *Insertion,* into the *tendo Achillis.*

These last two muscles form the calf of the leg, and are called the triceps suræ.

Plantaris.—This muscle has the longest tendon in the body.

Origin, just above the external condyle of the femur. *Insertion*, into the os calcis before the *tendo Achillis*.

Popliteus[6] (Fig. 75).—*Origin*, from behind the external condyle of the femur. *Insertion*, into an oblique ridge of the tibia, below its head. *Use;* it bends the leg and rolls it inwards.

Flexor Longus Digitorum Pedis Perforans.[7]—*Origin*, from the back of the tibia below its oblique ridge. *Insertion*, into the bases of the third phalanges of the four lesser toes, by four tendons, which perforate the split tendons of the flexor brevis. *Use;* it flexes the toes and extends the leg.

Flexor Longus Pollicis Pedis.[9]—*Origin*, from the lower two-thirds of the posterior face of the fibula. *Insertion*, into the second phalanx of the great toe. Its tendon is connected with the flexor longus digitorum pedis. *Use;* it flexes the great toe.

Tibialis Posticus.[8]—*Origin*, by two heads from the tibia and fibula, and from the interosseous ligament. *Insertion*, into the tuberosity of the cuphoid bone. *Use;* it extends the foot.

MUSCLES OF THE FOOT.

Extensor Brevis Digitorum Pedis[11] (Fig. 74).—*Origin*, from the greater apophysis of the os calcis. *Insertion*, by four tendons into the backs of the four greater toes. *Use;* it extends the toes.

Flexor Brevis Digitorum Pedis[5] (Fig. 76).—*Origin*, from the larger tuberosity of the os calcis and plantar fascia. *Insertion*, by four small tendons, which are perforated by those of the flexor longus, into the second phalanges of the four smaller toes.

Fig. 76.

Flexor Accessorius.—*Origin*, from the inside of the sinuosity of the os calcis in front of its tuberosities. *Insertion*, into the outside of the tendon of the flexor longus, at its division. *Use;* it assists in flexion.

Lumbricales Pedis.[7]—*Origin*, from the tendons of the flexor longus. *Insertion*, into the inside of the first phalanx of each toe. *Use;* they assist in flexion.

Abductor Pollicis Pedis.[3]—*Origin*, from the internal tuberosity of the os calcis, the plantar fascia, and internal cuneiform bone. *Insertion*, into the inner side of the base of the first phalanx of the great toe, including the internal sesamoid bone. *Use;* it draws this toe from the others.

Flexor Brevis Pollicis Pedis.—It consists of two bellies, which *arise* from the calcaneo-cuboid ligament and external cuneiform

bone. *Insertion*, by two tendons into the base of the first phalanx of the great toe, including the sesamoid bones. *Use;* it flexes this toe.

Adductor Pollicis Pedis.—*Origin*, from the calcaneo-cuboid ligament, from the bases of the third and fourth and fifth metatarsal bones. *Insertion*, into the tendon of the flexor brevis and external sesamoid bone. *Use;* to draw this toe towards the rest.

Abductor Minimi Digiti Pedis.—*Origin*, from the outer and lesser tuberosity of the os calcis and the metatarsal bone of the little toe. *Insertion*, into the base of the first phalanx of the little toe. *Use;* it draws this toe from the others.

Flexor Brevis Minimi Digiti Pedis.—*Origin*, from the calcaneo-cuboid ligament, and from the fifth metatarsal bone. *Insertion*, into the base of the first phalanx of the little toe. *Use;* it bends the little toe.

Transversalis Pedis.—*Origin*, from the capsular ligaments of the first joint of the fourth and fifth toes. *Insertion*, into the external sesamoid bone. *Use;* it approximates the heads of the metatarsal bones.

Fig. 77.

Fig. 78.

Interosseous Muscles.—These are seven in number, four of which are upon the dorsal, and three upon the plantar surface of the foot. The *dorsal interossei*, arise by double heads, and are inserted into

the bases of the phalanges. The first is inserted on the inner side of the second toe, and is therefore an adductor; the other three are inserted into the outer side of the second, third and fourth toes, and are abductors. The *plantar interossei* arise from the bases of the three outer metatarsal bones, and are inserted into the inner side of the bases of the first phalanges of the same toes. In their action they are adductors.

SECTION IV.

VISCERA.

ORGANS OF DIGESTION.

MOUTH.

The *Mouth* is separated from the nose by the hard and soft palate, and communicates behind with the fauces. It is bounded in front by the lips, while its floor is formed by the mylo-hyoid muscles, and its sides by the cheeks. The space between the lips and the teeth is called the *vestibule.* The mouth is lined by a mucous membrane, which has a variable degree of thickness, and is thrown into folds, which are called *frena;* there is one beneath the tongue, one in front of the epiglottis cartilage at the root of the tongue, and one at the middle of the inner surface of each of the lips. This membrane is covered with numerous glands, some of which are mucous and some salivary.

Internally the lips are composed of fibres,—which extend from the middle of the internal surface of each lip to the gum,—and fat, externally of skin. The *upper lip* is longer and thicker than the lower, and has a vertical depression on the middle of its front surface called *philtrum.*

The *Gums* are formed of the lining membrane of the mouth, much thickened; they have great hardness and vascularity, and but little sensibility in health. They include the neck of the tooth, and adhere firmly to the periosteum.

The gums and lips are covered by numerous papillæ, which consist of capillaries and nerves.

The cheeks are composed of muscle, fat, cellular tissue, glands, and blood-vessels, included between skin and mucous membrane.

TONGUE.

The *Tongue* is an oblong, flattened, muscular body, which varies

in size and shape; it is the organ of taste, and also of importance in speech and mastication. Its posterior extremity or root is attached to the hyoid bone by yellow fibrous tissue. Its anterior extremity is called its point or *tip;* its intervening portion its *body.*

Fig. 79.

The *mucous covering* of the tongue is very thick upon its upper surface, and very thin upon its under surface. Sometimes the term periglottis is applied to the epithelium of the upper surface. Upon its upper surface are a number of projections or *papillæ* of various sizes and shapes. The largest are eight or nine in number, called papillæ *maximæ,* and are situated at the posterior portion of the tongue, in two convergent lines; they are surrounded by fossæ, the largest of which is in the middle, and called the *foramen cæcum.* These larger papillæ will be found to be covered by smaller ones, which are called secondary papillæ. The smallest papillæ are fine and pointed, and are found near the middle of the tongue, and are termed *filiform.* The intermediate papillæ are most abundant, some of them are *conical,* others *fungiform.* Each papilla is formed of capillary vessels and a nerve. Different functions are attributed to these different papillæ.

Between the papillæ maximæ and the epiglottis are a number of large mucous follicles.

Muscles of the Tongue.—Hyo-glossus.[4]—*Origin,* from the cornu of the hyoid bone. *Insertion,* into the side of the tongue, some of the fibres reaching its tip.

Genio-hyo-glossus.[5]—*Origin,* by a tubercle behind the symphysis of the lower jaw. *Insertion,* into the hyoid bone, and into the whole length of the tongue.

Lingualis.[9]—*Origin,* from the yellow tissue at the root of the

tongue. *Insertion*, into the tip between the two last-mentioned muscles.

Fig. 80.

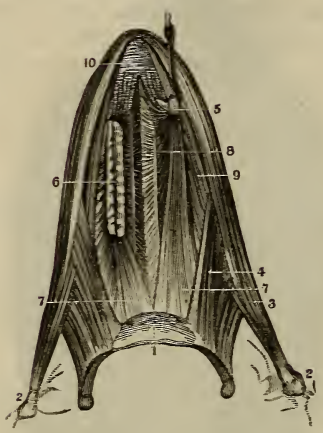

Superficialis linguæ.—An indistinct layer of muscular fibres on the dorsum of the tongue under the mucous membrane. It seems to curl the lip upwards.

Transversales linguæ.[10]—Are scattered fibres which pass from the middle line to the edge of the tongue; they extend from the tip to the root, and their contractions lengthen the tongue.

Verticales linguæ.—These are fibres which extend from the upper to the lower surface of the tongue.

The tongue is supplied by the lingual artery.

The nerves are the *hypoglossal* or 9th, which is distributed to its muscles; the lingual or *gustatory* branch of the 5th, which supplies the papillæ and mucous membrane at the forepart and sides of the tongue; and the lingual branch of the glosso-pharyngeal division of the 8th, which sends filaments to the papillæ maximæ, and to the mucous membrane near the base of the tongue.

THE PALATE.

The palate separates the back portion of the nose from the mouth, and is divided into two parts. The *hard palate* consists of the palate processes of the superior maxillary and palate bones, covered by mucous membrane, which is continuous with that of the mouth, but is not so vascular or sensitive as that of other parts. It very frequently presents transverse ridges, as well as a ridge in the median line. The *soft palate* is the membranous separation between the back portion of the mouth and nose, and consists of a fold of mucous membrane stretched transversely, enclosing muscles and glands. From its middle there projects the *uvula*, about three quarters of an inch in length; from each side of the uvula there are two divergent crescentic folds of mucous membrane, which are called *lateral half-arches;* the space between which constitutes the *fauces.*

Between the anterior and posterior arches of each side is the *tonsil gland.* The *tonsil* is about the size of an almond, and consists of a collection of large mucous follicles.

Muscles of the palate.—*Constrictor isthmi faucium.*—A small muscle placed in each anterior half-arch, *arising* from the middle of the soft palate, and *inserted* into the side of the root of the tongue. It diminishes the opening into the pharynx.

Palato-pharyngeus.—Another small muscle, included in the posterior half-arch, arising from the soft palate, and *inserted* into the side of the pharynx. It draws the palate down and the pharynx up.

Circumflexus or *Tensor palati.*—*Origin*, from the spinous process of the sphenoid bone, and the contiguous portion of the Eustachian tube. *Insertion*, by a tendon, which winds around the hamulus or hook of the internal pterygoid process, into the posterior and crescentic edge of the palate. *Use;* to extend the soft palate transversely.

Levator palati.—*Origin*, from the petrous portion of temporal bone and Eustachian tube. *Insertion*, into the soft palate. *Use;* it draws the palate upwards.

Azygos uvulæ.—Is in the middle of the uvula and soft palate. It arises from the posterior nasal spine. Its contractions shorten the uvula.

SALIVARY GLANDS OF THE MOUTH.

The salivary glands are of a light pink colour, and their secretion is of great service in mastication and digestion. They are three in number—the parotid, submaxillary, and sublingual.

Fig. 81.

The *parotid* is the largest of the three: its shape is irregular; it has no capsule, and is merely covered by the superficial fascia of the

neck. It lies on the side of the face in front of the ear, and beneath the skin. It extends in front, so as to cover a portion of the masseter muscle; in depth in reaches towards the styloid process, and posteriorly it is bounded by the external meatus, the mastoid process, and the sterno-cleido-mastoid muscle. Its structure is lobulated, and its duct, called the *duct of Steno*,[2] traverses the outer face of the masseter muscle in a line drawn from the lobe of the ear to the end of the nose. It is white and hard, about the size of a crow-quill, and perforates the cheek through a pad of fat by a very small orifice opposite the second molar tooth of the upper jaw. The external carotid artery passes through the deeper portion of the gland, and it is also traversed by the portio dura nerve. There is sometimes found in front of the gland an accessory portion, called *socius*, or *accessorius parotidis*, whose duct empties into that of Steno.

The *submaxillary* gland[3] is much smaller than the parotid, is irregularly oblong in figure and lobulated in structure. It is situated in a depression on the internal face of the inferior maxillary bone, and covered externally by the skin, superficial fascia, and platysma muscle. Its duct[4] is called the *duct of Wharton*, which empties at the side of the frænum under the tongue by a very small orifice on the summit of a papilla; the coats of this duct are very thin; the gland is traversed by the facial artery as it mounts the lower jaw. Sometimes there is an additional gland and duct, called after Bartolin.

The *sublingual gland*[5] is the smallest of the three; its shape is also oblong, and its structure lobulated; it is situated under the tongue, between the mucous membrane of the mouth and the mylo-hyoid muscle. Its duct or ducts (for they are frequently numerous) are called after Rivinus, and empty into or near the duct of Wharton.

THE PHARYNX AND ŒSOPHAGUS.

The *pharynx* is a muscular and membranous sac, communicating with the mouth, nose, œsophagus, larynx, and Eustachian tube. It is situated in front of the vertebral column, and extends from the basilar process of the occiput to the fourth or fifth cervical vertebra. It is funnel-shaped, being larger above than it is below. Its length is about five inches, although this varies by contraction and distension; it is never collapsed, for its walls are always kept distended by its muscular origins. It consists of three coats, *muscular*, *cellular*, and *mucous*. Its external or muscular coat is formed by the following muscles.

The *inferior constrictor muscle*[9] arises from the cricoid and thyroid cartilages. (Fig. 82.) The fibres terminate in those of its fellow along the posterior median line; those of the upper part are oblique, those of the lower horizontal.

The *middle constrictor muscle*[10] arises from the cornu of the os hyoides, and the lateral thyreo-hyoid ligament, and is inserted into its fellow in the posterior median line. Its upper fibres ascend obliquely to the basilar process of the occiput, and overlap the superior constrictor, while its lower fibres are horizontal or descending, and are overlapped by the inferior constrictor.

The *superior constrictor muscle* is quadrilateral, and arises from the pterygoid process of the sphenoid bone, from the upper and lower jaw, the buccinator muscles, and the root of the tongue : it is inserted into its fellow behind, and also into the basilar process of the occiput.

The *stylo-pharyngeus muscle*[12] has been described before.

The *cellular* coat is thin, and merely serves for the transmission of vessels and nerves, and the connexion of the external and internal coats.

The *internal or mucous coat* is a continuation of that of the mouth, nose, and Eustachian tube, and it is covered by a thin epithelium, and studded with mucous follicles and glands. It is supplied by the pharyngeal and palatine arteries, and by the sympathetic and eighth pair of nerves. Its uses are for deglutition, respiration, and modulation of the voice.

Fig. 82.

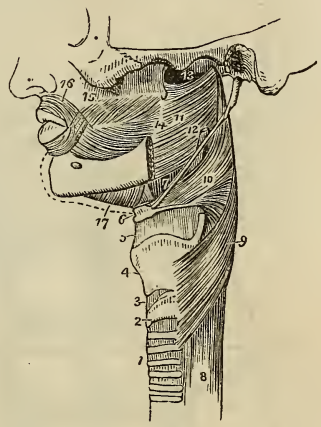

The *œsophagus* is a canal which conveys the food from the pharynx to the stomach. It is situated in the median line, in front of the vertebral column, and passing through the posterior mediastinum inclines somewhat to the left side at its lower part, where it passes through the diaphragm.

Its length is about nine or ten inches, and its diameter is not uniform, gradually increasing as it descends. Its upper portion is the narrowest part of the alimentary canal, and hence foreign bodies which are too large to pass through the alimentary canal, are generally arrested in the neck; its shape is cylindrical, although its walls when at rest are in contact. It never contains air.

It has three coats, the external of which is muscular, and thicker than any other portion of the canal. The muscular coat consists of two layers; the fibres of the external are longitudinal, and those of the external are circular. The *cellular* coat attaches the muscular and mucous, and serves for the passage of vessels and nerves. The *internal* or *mucous* coat is continuous with that of the pharynx, and

has a number of longitudinal folds when in a state of quiet. It has a thick epithelium, and numerous mucous glands and follicles. It is supplied by the œsophageal arteries, proceeding from the inferior thyroid, aorta, coronary, and phrenic arteries; its nerves are derived from the eighth pair, and from the sympathetic.

Deglutition is performed by the contraction of its longitudinal fibres, which shorten the passage, and by the contraction of its circular fibres successively from above downwards.

VISCERA OF THE ABDOMEN.

The cavity of the abdomen is divided into nine different regions, by the drawing of parallel lines vertically[2 3] through the anterior inferior spinous processes, and intersecting them with two other parallel lines drawn transversely[1 4] over the crests of the ilia, and over the most prominent part of the costal cartilages. We thus have three regions above, three in the middle, and three below.

Fig. 83.

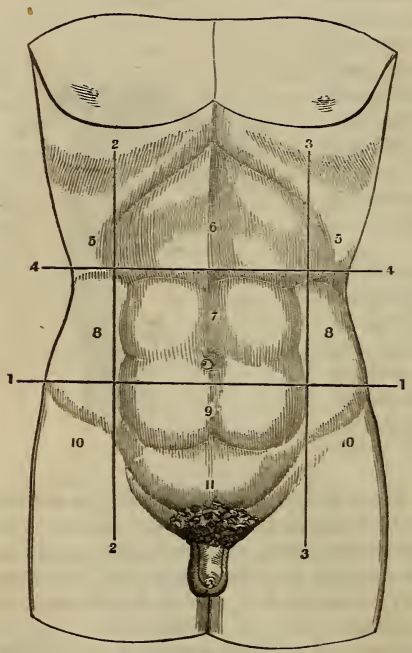

They are the *epigastric*,[6] in which are the left lobe of the liver, and a portion of the stomach; the *right hypochondriac*,[5] containing within it the right lobe of the liver, the *left hypochondriac*, containing the spleen, a portion of the stomach, and the liver; the *umbilical*,[7] in which are the small intestines, and on either side the *lumbar* regions;[8] the *right lumbar* region contains the right kidney, and ascending colon; while the *left* contains the left kidney and descending colon; the *hypogastric* region,[9 11] in which is a portion of the small intestines and bladder;

and the *iliac fossæ*;[10] the *right* of which contains the cœcum or caput coli, and the *left* contains the sigmoid flexure.

PERITONEUM.

The peritoneum is a thin, transparent membrane, lining the cavity of the abdomen, and covering most of the viscera that are contained therein. It is a serous membrane, and therefore a shut sac, following the general rule of lining the cavity, and covering the organs contained within. It secretes a small quantity of fluid in health, which lubricates the surfaces of the viscera, so that they readily move upon each other and the walls of the cavity. It also forms ligaments and connexions whereby the viscera are held in their places. That portion of the peritoneum which passes between one viscus and another, or from a viscus and the wall of the cavity, usually consists of two laminæ, and is called an *omentum*. There are four principal omenta, viz., the *gastro-hepatic*, or *lesser omentum*, which reaches from the lesser curvature of the stomach to the liver; the *gastro-splenic*, reaching from the left extremity of the stomach to the spleen; the *colic-omentum* or *meso-colon*, which holds the large intestine to the posterior wall of the abdomen; and lastly, the *gastro-colic* or *great omentum* or *caul*, which passes between the stomach and colon; the last is the largest, and covers the intestines like an apron; it appears to consist of four layers, whereas, like the rest, it consists but of two. Owing to its great size and the proximity of the colon to the stomach, it must necessarily be folded or doubled, and thus presents a quadruple appearance.

Fig. 84.

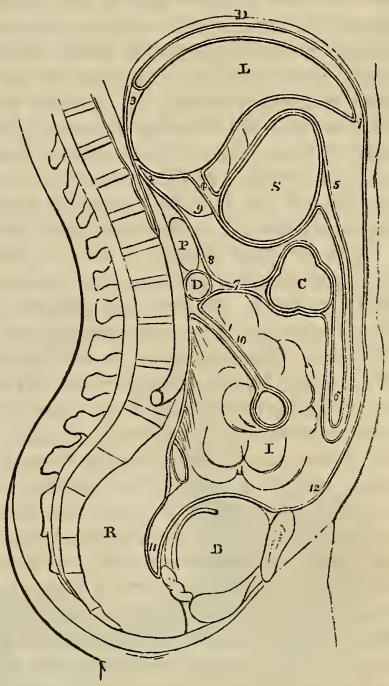

Since the peritoneum is a continuous membrane, its whole surface can be traced in a male subject with the point of a finger, other-

wise it would not be a single sac. In the female there is a deficiency at the extremity of the Fallopian tube.

Commencing at the umbilicus to trace the peritoneum, it will be found to line the anterior wall of the abdomen and under surface of the diaphragm, thence to cover the upper and a part of the lower surface of the liver,[L] thence to pass to the stomach,[S] forming thus[4] the upper lamina of the gastro-hepatic or lesser omentum; having covered the anterior face of the stomach,[S 5] it passes down to form one of the laminæ of the apparently quadruple omentum—the gastro-colic; ascending again it forms another lamina, and surrounding the inferior semi-circumference of the colon,[C] it passes to the vertebral column, forming the inferior lamina of the colic omentum,[7] then we find it including the small intestine forming at the mesentery;[10] from the vertebral column it can be traced over the upper and anterior part of the rectum,[R] and over the posterior and superior portion of the bladder,[B] forming at the vesico-rectal pouch,[11] and again we trace it to the umbilicus, the point whence we started.

But in thus tracing it will be found, by the diagram, that we have not traced the peritoneum covering some portions of the viscera and abdomen. In the dead subject it is very easy to introduce the finger through a narrow passage which is called the *foramen of Winslow*, although there is no hole or tearing of the peritoneum. By looking for the posterior end of the gall-bladder and passing the finger under the vessels of the liver, it will be easy to touch the peritoneum covering the posterior surface of the stomach. This cannot be demonstrated very clearly from a drawing alone, which represents merely a longitudinal section of the abdominal cavity; and without explanation it gives the false idea of there being two sacs instead of one. In the subject, however, by placing the finger upon the under surface of the liver, we trace the peritoneum through the foramen of Winslow; there it forms the inferior lamina of the lesser omentum,[4] thence it covers the inferior surface of the stomach; descending it forms the third and ascending at [6], it forms the fourth lamina of the great omentum; then it covers the superior convexity of the colon, and forming the superior lamina of the colic omentum at [7], it ascends in front of the duodenum and pancreas,[P D] and passing out at the foramen of Winslow, we can trace upon the posterior and inferior portion of the liver, the point of starting.

The *mesentery* is formed of two laminæ of peritoneum, and serves to connect the small intestine to the parietes of the abdomen. Its root is about six inches wide, and its inferior edge equals in breadth the whole length of the small intestine. Between these two laminæ of peritoneum are the superior mesenteric artery and vein, lymphatic glands and vessels, and branches of the sympathetic nerve, together with a portion of fat and cellular tissue.

The *meso-colon* is also formed of two laminæ of peritoneum, and

holds the large intestine in its place. The transverse portion is long and loose, but on each side in the iliac regions it is short, and binds the intestine down very tightly; it also contains between its laminæ, vessels and nerves, together with some fat and cellular tissue; that portion which is attached to the rectum is called the *meso-rectum*.

THE STOMACH.

The stomach is a conoidal sac, somewhat bent or curved, and is situated in the left hypochondriac and epigastric regions. It is somewhat flattened anteriorly and posteriorly, and thus presents an anterior and posterior face; its direction is oblique from above downwards, and from left to right. The left[3] extremity is much the larger, and terminates in a rounded cul-de-sac; at the superior portions of this extremity is the *cardiac* orifice, where the œsophagus is continued into the stomach immediately below the diaphragm. The right extremity gradually diminishes in size, and its orifice is called *pyloric*,[9] which is continuous with the small intestine. The structure of the pylorus is much thicker than that of any other portion.

The stomach is held in its position by the œsophagus and the duodenum, as well as by peritoneal reflexions. The right end is lower and more anterior than the left.

The upper and lower curvatures of the stomach are called the greater and lesser curvatures.[5] [6] Near the pyloric extremity of the stomach, is a slight dilatation[7] called *antrum pylori*. The dimensions of the stomach are variable, depending upon the mode of life. It consists of four coats; peritoneal, muscular, cellular, and mucous.

Fig. 85.

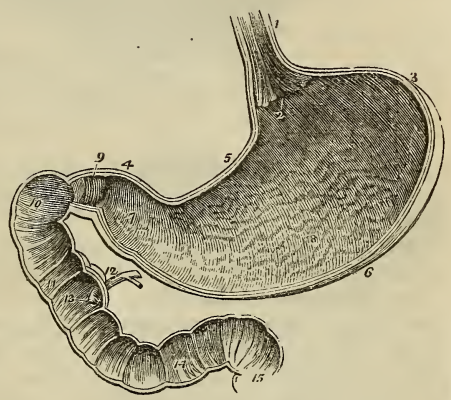

The walls of the stomach consist of four distinct coats.

The *Serous or Peritoneal coat* completely covers the stomach, except at the curvatures, where are attached the omenta; the looseness of the omental connections at these points admits of the distension of the remaining coats.

The *Muscular coat* is not so thick as that of the œsophagus, and

its fibres pass both in a circular,[7] longitudinal,[8] and oblique direction (see Fig. 86). The muscular fibres which pass obliquely round the left extremity, constitute the muscle of Gavard. The circular fibres are most numerous near the pyloric orifice, and the longitudinal fibres are most distinct upon the lesser curvature. The latter are the most external, and are a continuation of those of the œsophagus.

The *Cellular* or *nervous coat* connects the muscular and mucous; it serves for the transmission of vessels and nerves, and can readily be inflated; when dried, it resembles cotton.

The *Mucous* or *Villous coat*, is a continuation of that of the œsophagus; it is soft and thick, of a light pink colour, and is thrown

Fig. 86.

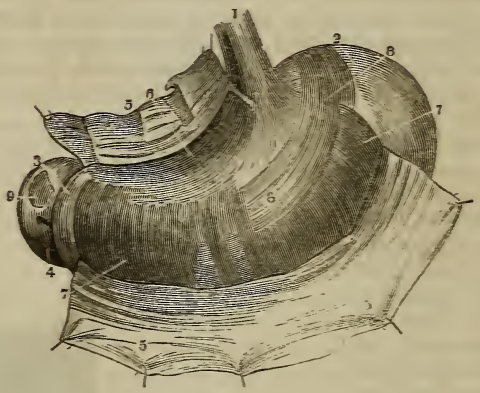

into a number of longitudinal *rugæ* or folds, which are particularly numerous at the greater curvature, and nearer the pyloric orifice.[5] (See Fig. 86.)

At the pyloric orifice, the mucous membrane is thrown into a circular or semicircular fold, which is called the *pyloric valve*.

The *epithelium* of the mucous membrane of the stomach is thinner than that of the œsophagus, and is of the conoidal variety.

The surface of the mucous membrane of the stomach presents different appearances in different portions. These will be best seen by minutely injecting the stomach of a child and washing off the epithelium.

The left extremity and the great body of the stomach will exhibit polygonal *cells* or *alveoli*, which give it a honeycomb appearance.

The walls of these cells or pockets, as well as the ridges between them, are composed of capillaries united by basement membrane.

These cells are larger in the cardiac extremity, and very regular in their appearance. The bottom of each cell is subdivided into smaller cells by the arrangement of the capillaries, and these smaller cells are the orifices of the *gastric glands* or tubuli which secrete the gastric juice. Near the antrum pylori the cells or alveoli are less numerous and smaller; and the ridges separating them are larger. Towards the pyloric valve there exist conical projections, which may be termed *gastric villi;* these villi are smaller than those of the intestine.

The lesser curvature is supplied by the gastric artery, the greater by the right and left gastro-epiploics, and the greater extremity by the vasa brevia. The nerves are derived from the par vagum and solar plexus of the sympathetic.

INTESTINES.

The intestinal canal is from thirty to thirty-five feet in length, and is divided into large and small intestine.

SMALL INTESTINE.

The small intestine is four-fifths of the length of the whole canal, reaching from the pylorus to the large intestine; it is cylindrical, and about one inch in diameter, although there is a gradual diminution in diameter as it descends. It consists of four coats.

The *Peritoneal coat*[1] is the external coat, and is continuous with that portion of the peritoneum forming the mesentery.

The *Muscular coat* is thin, and consists of pale fibres; the superficial are longitudinal;[2] the remainder are circular,[3 4] and more distinct.

Fig. 87.

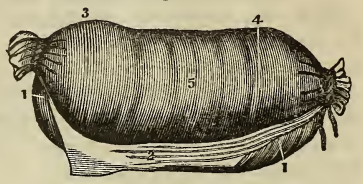

The *Cellular coat* connects the muscular and mucous, and contains the vessels and nerves; when inflated with air and dried, it appears like cotton, as is the case in the stomach.

The *Mucous coat* is continuous with that of the stomach, and covered with a conoidal epithelium. It is longer than any other, and hence must be thrown into numerous folds, which are called *Valvulæ Conniventes;* these are circular and overlapping, and more numerous[2] and larger[1] in the upper portion of the intestine than in the lower. They differ from other folds of mucous membrane in being permanent; distention does not remove them.

The surface of the mucous membrane is covered with a number

of papillary projections, called *Villi*, which render it soft and velvety.

Their shape varies in different parts of the intestine; in the upper part of the intestine they are more numerous, and resemble triangular convolutions; in the lower they are more conical and cylindrical. Their length varies from $\frac{1}{4}$th to $\frac{1}{3}$d of a line. Each consists

Fig. 88.

Fig. 89.

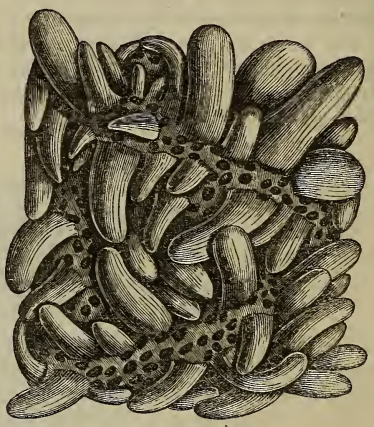

of a capillary network united by simple membrane, and communicating with a small artery and vein. They contain also lymphatics (Fig. 88), or lacteals, and a number of granular corpuscles and fat cells. The exterior is covered with a conoidal epithelium.

The *glands* of the small intestine are the crypts or follicles of Lieberkühn, the glands of Peyer, the Solitary Glands, and Brunner's Glands.

The *crypts* are the smallest of the glandular structures, and consist of nothing more than pockets or tubes opening by small orifices in every part of the intestine. Their diameter is $\frac{1}{50}$th of a line. They are lined by epithelium.

The Glands or Patches of Peyer.—These are all called *agminate.* They are oval clusters of small, round, flattened vesicles or capsules, often filled with a white semifluid matter, and situated beneath the mucous membrane. When empty of fluid they are difficult of detection. Their size varies from half an inch to four inches in length. Occasionally they are nine inches long.

They are more numerous in the lower part of the ileum, opposite the mesenteric attachment. There may be twenty or thirty in each individual.

Fig. 90.

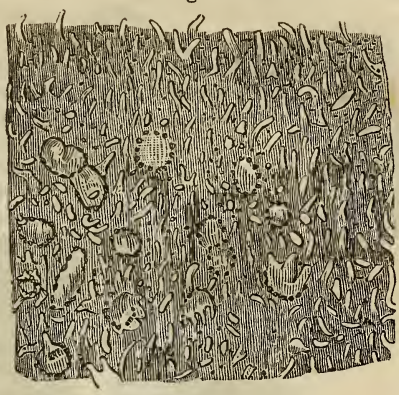

The *solitary* glands differ from the Agminate or Peyerian only in being separate. They are soft, white, rounded elevations, scattered over the whole surface of the mucous membrane of the small intestine. They frequently contain a white fluid, but like the vesicles of the Peyerian patch, have no orifice of discharge.

Brunner's glands are small round bodies in the upper part of the duodenum. They are compound glands, containing lobules and branched ducts, which open upon the intestine.

The mucous membrane of the small intestine is extremely vascular, and its absorbents are very numerous.

The arteries are derived from the superior mesenteric, and the nerves from the solar plexus.

The small intestine is divided into Duodenum, Jejunum, and Ileum.

The *Duodenum* commences at the pylorus, and is about twelve inches in length. It is curved in its direction, and partially deficient in its peritoneal coat, on account of its being received between the two laminæ of the colic omentum. Its mucous coat is characterized by its colour, being tinged with bile, and by the great abundance of valvulæ conniventes in its lower part; the upper part contains the glands of Brunner. The *ductus communis choledochus* opens into the duodenum four or five inches from the pylorus, through a small elevation or tubercle.

The *Jejunum* (from jejunus, *empty*), constitutes two-fifths of the small intestine, and the ileum the remaining three-fifths. Although there is no anatomical reason for this division, it being impossible, from appearances, to say where the jejunum terminates or the ileum begins, yet if a portion of the upper extremity of the jejunum be compared with a portion of the lower extremity of the ileum, it could be recognised by its diameter, abundance of valvulæ conniventes, and the small number of *Peyer's Glands*. There are frequently *blind pouches*, varying in size from one to two inches, along the course of this small intestine.

LARGE INTESTINE.

The large intestine reaches from the ileum to the anus, and is

Fig. 91.

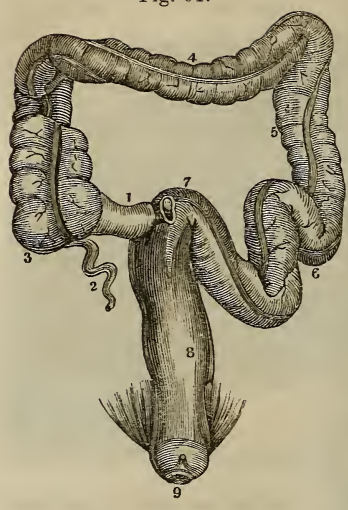

one-fifth in length of the whole intestinal canal; it differs much from the small intestine in its diameter, and has a sacculated appearance. Like the small intestine, it consists of four coats.

The *peritoneal coat* is continuous with the meso-colon, and has numerous folds filled with fat, which are called *appendices epiploicæ*.

The *muscular coat* consists of two sets of fibres; the longitudinal fibres are collected into three bands, each about half an inch in breadth, which extend to the rectum; the circular fibres are also thicker than those of the small intestine.

The *cellular coat* connects the mucous and muscular, and contains the blood-vessels and nerves.

The *mucous coat* has no *valvulæ conniventes* nor *villi;* it is whiter, thicker, and coarser, than that of the small intestine. Its *follicles* or crypts are extremely numerous, and more readily discerned than in the small intestine. They are very regular and uniform in their appearance, and consist of a capillary network, forming a pouch or tube lined by conoidal epithelium. There are also some glands scattered over the mucous coat of the large intestine, which are about half a line in diameter. They consist of a dilated cavity with a narrow orifice.

The epithelium of the large intestine is columnar, and lines the crypts and glands.

The large intestine is divided into the cœcum, colon, and rectum.

The *Cœcum* is a cul-de-sac[3] (Fig. 91), and the commencement of the large intestine, and hence is often called *caput coli*. It is bound down into the right iliac fossa, by the meso-colon; its length varies from one and a half to three inches, and its diameter is greater than that of any other portion of the alimentary canal, except the stomach.

The *appendix vermiformis*, is a worm-like process, of the thickness of a quill, varying in length from three to six inches, and attached to the inferior portion of the cœcum.[5] Its coats are the same as those of the intestine, and it usually contains flatus. Its follicles or crypts are not so numerous or regular in their arrangement and size as those of the other portions of the large intestine and when injected, show a different arrangement of capillaries.

The *ileo-cæcal* valve[3] is an elliptical opening on the side of the cœcum, between its circular fibres, whereby the small intestine empties into the large. It is composed of two crescentic folds, the upper of which is the larger. Its action is such that the distention of the cœcum will prevent the passage of air or fluids backwards into the small intestine. (Fig. 93.) It is also called the *valve of Bauhin* or *Morgagni*.

The *Colon* is the longest portion of the large intestine; it gra-

Fig. 92.

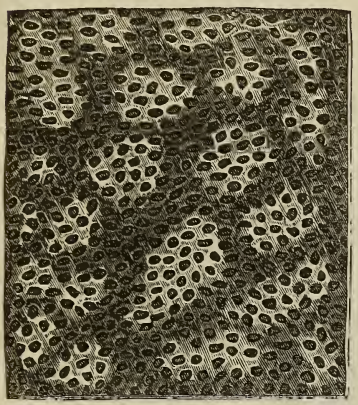

Fig. 93.

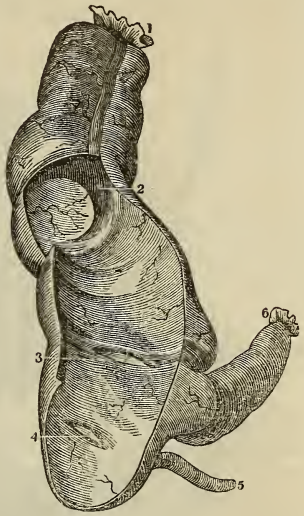

dually diminishes in diameter until it terminates in the sigmoid flexure on the left side.[6] (Fig. 92.) It ascends upon the right side, and forming an arch transversely, descends upon the left. The right side receives its arteries from the superior mesenteric, and the left side receives branches from the inferior mesenteric. The nerves are derived from the inferior and superior mesenteric plexuses of the sympathetic.

The *Rectum* is the terminating portion of the large intestine, and reaches from the sigmoid flexure to the *anus*, occupying a position in front of the sacrum. It is somewhat barrel-shaped, being larger in the middle than at either end. The *peritoneal* covering is deficient below and behind. The *muscular* coat has a very great *thickness* and redness. The external fibres are *longitudinal*, and the internal *circular*. The fibres of the external muscular coat wind around the inferior edge of the circular coat, and terminate in the

mucous coat, which, in some measure, accounts for hæmorrhoids and prolapsus ani. The mucous coat is thicker and redder than in the upper part of the intestine, and at the lower extremity, just above the anus, is thrown into a *number of pouches* between the longitudinal muscular fibres. (Fig. 94.) About five or six inches above the anus, is a *semicircular fold* of the mucous membrane on each side of the rectum; these two are about half an inch distant

Fig. 94.

from each other; they resemble the valvulæ conniventes, and in some measure prevent the involuntary discharges of fæces.—The arteries of the rectum are the superior, middle, and inferior hæmorrhoidal. The veins form a plexus around the bowel, which communicates with the internal iliac and portal veins. The nerves are supplied from the sacral plexus, and from the hypogastric plexus of the sympathetic.

THE LIVER.

The *liver* is the largest glandular organ in the body, and secretes bile. It is oblong and oval in its shape, and occupies the right hy-

pochondriac, a portion of the epigastric, and left hypochondriac regions. It *weighs* from four to five pounds; it *measures* from ten to twelve inches transversely, and from six to seven antero-posteriorly; its greatest thickness is from four to five inches. It is convex upon its upper surface, and concave upon its lower. Its *colour* is of a reddish brown, with occasional spots of black. It is covered almost entirely by peritoneum, which, upon its upper surface, forms a broad *suspensory ligament*,[5] by means of which it is held in contact with the diaphragm. In the anterior edge of this ligament, is another, of a cordlike character, called *ligamentum teres*,[6] which was originally the umbilical vein. It passes through the anterior notch of the liver

Fig. 95.

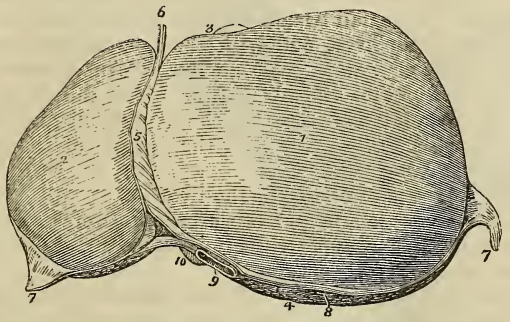

and umbilical fissure. Posteriorly, the two laminæ of the suspensory ligament diverge, forming the *coronary ligament*, under which the liver is destitute of peritoneum. The *lateral ligaments*[8 8] are also peritoneal, being, in fact, a continuation of the coronary; they are horizontal, and attach the right and left sides of the liver to the posterior walls of the abdomen. There is a deep depression upon the posterior edge of the liver, called the *posterior notch*, whereby the liver is adjusted to the vertebral column. The anterior and posterior notch divide the liver into *two lobes*, the right of which is much the larger and thicker, and the left terminates in a thin cutting edge.

Fig. 96.

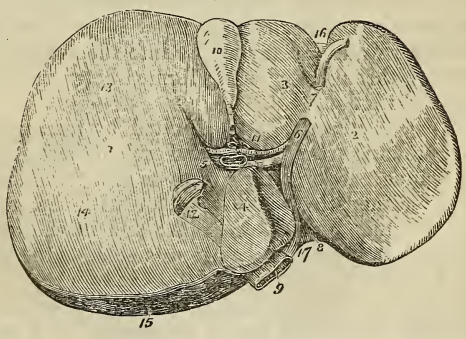

The under sur-

face of the liver presents a deep *fissure*, called *umbilical* or longitudinal, which reaches from the anterior[16] to the posterior[17] notch, and contains the remains of the umbilical vein, now the ligamentum teres, and the remains of the ductus venosus. Sometimes this fissure is converted into a foramen,[7] the right and left lobes being connected. At right angles to this fissure is another, called the *transverse fissure*,[11] which contains the portal vein, hepatic artery, and hepatic duct, bound together by cellular tissue, which is called the *capsule of Glisson*. A deep depression upon the under surface of the right lobe of the liver, parallel with the longitudinal fissure, contains the gall-bladder;[10] that portion of the liver included between this depression and the longitudinal and transverse fissures is called the *lobulus quadratus*,[3] or quartus, from its shape. The *lobulus Spigelii*[4] is a small triangular lobe, at the posterior and inferior portion of the liver, and with the lobulus quadratus, constitutes the *porta* or gateway of the liver. An elongated ridge, running from the lobulus Spigelii outwardly,[5] is called the *lobulus caudatus;* in the angle between the lobulus Spigelii and the right lobe of the liver, is a *deep fissure*, for the passage of the ascending vena cava.[2]

There are *four* sets of *vessels* for the liver.

The *hepatic artery* is a branch of the cœliac, approaches the liver at the transverse fissure, and divides into two or three large branches previous to entering it.

The *portal vein* collects the blood from all the chylopoietic viscera, and upon reaching the transverse fissure, divides into two large branches, called the *right* and *left sinuses*.

The *hepatic duct*, commencing by fine branches in the interior of the liver, is about the size of a small quill, and is also included with the two last vessels by the capsule of Glisson in the transverse fissure.

The *hepatic veins* commence also by capillaries in the liver. The branches collect and form three large trunks, whose course is backwards towards the posterior notch of the liver. These trunks appear more like channels lined by a thin venous coat, than the ordinary veins. They empty into the ascending vena cava, as it is passing through the fissure formed between the lobulus Spigelii and the right lobe.

The *structure* is best exhibited by tearing the liver; this shows a granulated arrangement, and each of these granules is usually called an acinus. Each acinus consists of a terminal branch of the portal vein and hepatic artery, together with the incipient radicles of the hepatic duct and hepatic vein; and in the capillary rete thus constituted are numerous cells, which secrete the bile. (See Physiology.)

A diversity of opinion exists as to whether these cells are inside or outside of the primitive biliary vessels. It is also doubtful whether the biliary vessels commence by a rete in each acinus, or

whether they commence by straight tubes, running between the acini, which, coalescing, form the hepatic duct. The aggregation of these acini is by means of cellular tissue, called the *parenchyma*, which may be considered as a continuation of Glisson's capsule.

GALL-BLADDER.

It is placed on the under surface of the right lobe of the liver, and inclines somewhat to the right side. It is a pyriform sac, of about three inches in length; its anterior extremity is globular, and called the *fundus;* its posterior end, or *neck,* is narrow, and twisted like a screw. It consists of *three coats.* The external is formed of the peritoneum,[1] and is only a partial covering for its inferior surface; the middle[2] consists of a strong layer of fibrous tissue; and the internal is mucous,[3] with short, irregular folds, giving it a fine net-like appearance; its colour is usually that of the bile; in the *neck* it is spirally twisted, and thus acts as a valve. Its duct, called the *cystic* duct, is shorter and thinner than the hepatic duct, which it joins at a very acute angle; this junction forms the *ductus communis choledochus,* which is about the size of a goose-quill, and three inches in length. It passses through the right extremity of the pancreas at its posterior portion, and perforates the duodenum obliquely and with a very small orifice, through an elevated tubercle. Its artery, called *cystic,* is a branch of the hepatic.

Fig. 97.

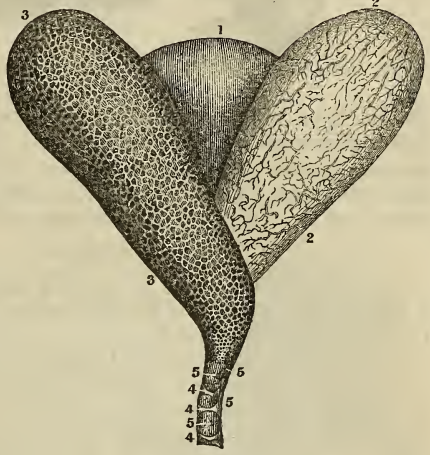

PANCREAS.

This is a long and flat gland, and of a light pink *colour.* It is *placed* transversely behind the stomach, and in front of the last dorsal and first lumbar vertebræ. It has no peritoneal covering, but is included between the two laminæ of the meso-colon, and extends from the curvature of the duodenum[7] across to the spleen.[1] It is about seven inches long. Its right extremity,[6] or *head,* is much the thickest part, is traversed by the ductus choledochus, and often called the *lesser pancreas.* Its left extremity gradually diminishes in breadth until it touches the spleen.

The superior edge of the pancreas has a *groove* for the passage of the splenic artery.[8 9 10] Its *structure*, like that of salivary glands, is conglomerate. Its excretory *duct*, called after *Wirsungius*, is

Fig. 98.

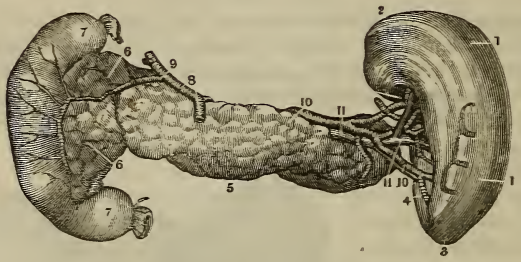

formed by a collection of small branches, which come from the lobules of the gland. The walls of the duct are thin, white, and smooth, gradually increasing in size; it *opens* into the duodenum near the orifice of the ductus communis choledochus, and sometimes into it. Its arteries are branches of the splenic.

SPLEEN.

The spleen is contained in the left hypochondriac region. It is a soft vascular organ of a purplish colour. It has no duct, and it is therefore not a true gland.

The shape of the spleen is irregular and variable, but it is generally a section of an ovoid, with a convex surface resting against the diaphragm, opposite the ninth, tenth, and eleventh ribs, and a concave surface directed towards the stomach; this surface is divided longitudinally by a fissure or hilum, which transmits the blood-vessels.

It is covered by the peritoneum, which appears wrinkled when the spleen is bent. Reflections of the peritoneum from the stomach and diaphragm, called gastro-splenic and splenico-phrenic omenta, hold the spleen in its position. The edges of the spleen are frequently notched, and occasionally small additional spleens are found connected with it.

It varies in size more than any other organ in the body. It is generally five inches long and three wide, and weighs from five to seven ounces. Besides its peritoneal coat, it is covered by an internal elastic tunic, which is of a white colour, and composed of cellular tissue. In some animals muscular fibres are found in this coat. From this tunic are prolonged numerous bands, which traverse the organ in all directions. In the interstices of these bands or trabeculæ the vessels ramify.

The proper substance of the spleen is a soft pulpy mass, of a reddish brown colour, resembling grumous blood, contained between the trabeculæ and outside of the venous plexus. It consists of rounded granules, about the size of the blood corpuscles. Beside these, there are the corpuscles of Malpighi, which are white capsules, varying in diameter from the $\frac{1}{25}$th to $\frac{1}{60}$th of an inch. They contain a soft, white, semifluid matter, which is composed of granules, resembling in size the red corpuscles of the spleen. The lymphatics of the spleen are very numerous.

The *splenic artery* is the largest branch of the cœliac, and divides into four or five branches before it enters the spleen. The splenic vein empties into the portal vein.

KIDNEYS.

The kidneys are two hard glands for the secretion of urine, placed in each lumbar region, and reaching from the first to the third lumbar vertebræ; they are outside of the peritoneal cavity, and surrounded with an abundance of fat and loose cellular tissue. The *right kidney* is rather lower than the left, on account of superposition of the liver. The *length* is four inches, and the breadth two inches. The *shape* is oval, resembling a bean; the position is upright, and the *fissure* or *hilum* is directed inwards towards the vertebral column. The upper end of the kidney is rather larger than the lower. It is covered by a strong *fibrous capsule*. The *colour* is of a reddish brown. Upon making a longitudinal section of the kidney, *two* different *structures* are presented. The *internal* is of the darker colour, and consists of about fifteen cones of Malpighi, which are arranged in three rows, their apices converging towards the hilum. These constitute the *medullary* portion. The *external* structure is of a lighter colour usually, is extremely vascular, and of a granulated arrangement; it constitutes the *cortical* portion.

Fig. 99.

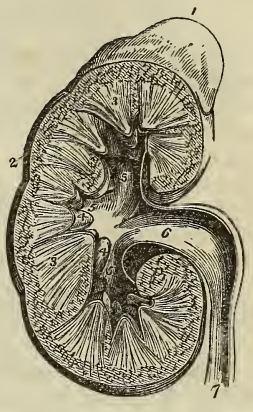

The *cortical* substance[2] consists of a number of *tortuous tubes of Ferrein*, in which the urine is first formed, and between whose walls are a number of small bodies, called the *corpuscles of Malpighi*.

Mr. Bowman says that the end of each tube is dilated and receives the Malpighian bodies. These bodies are a tuft of capillaries, of about $\frac{1}{120}$th of an inch in diameter. They are supplied by a small

artery, and from them emerges a vein, which afterwards forms a rete upon the uriniferous tubes.

The *medullary* cone of Malpighi[3] is capable of subdivision into small *pyramids of Ferrein*, and each pyramid of Ferrein will be found to consist of a number of straight *tubes of Bellini*, which are the continuations of the tortuous tubes of Ferrein.

The apex of each cone is called *papilla renalis*, and in the centre of each papilla is a slight depression, called *foveola*.

Each papilla is surrounded by a small membranous cup, called *infundibulum*,[4] into which the urine is first received as it oozes from the orifices of the papillæ. Four or five of these infundibula join to form a common trunk, called *calyx*,[5] and the junction of about three calyces form a common cavity, called the *pelvis*,[6] which is of a conoidal shape, and from which proceeds the *ureter*,[7] the excretory tube of the kidney, which conveys the urine to the bladder.

The *ureter*[3] is a cylindrical tube of the size of a quill, with thin, white, extensible walls. Crossing in its descent the iliac artery, it enters the inferior fundus of the bladder very obliquely, and opens by a very small orifice. It consists of two coats, the external of which is fibrous, and the internal is mucous. The structure of the calyces and infundibula is the same.

SUPRA-RENAL CAPSULES.

The *capsulæ renales*[1] (Fig. 99), are two small bodies, varying much in size, placed one on each side, just above the kidney, and reposing on its upper extremity. They are of a light brown colour, and surrounded by condensed cellular tissue. In fœtal and youthful life they are much larger than in adult life, and hence it is supposed that the use is confined to that period of life, as in the case of the thymus gland. They are of a triangular or semicircular shape, the base being excavated where it is adjusted to the kidney. Having no secretion, they of course have no duct.

They are supplied by the *capsular* artery, a branch of the renal artery or the aorta.

WOLFFIAN BODIES.

These structures exist only until the sixth month of fœtal life. Before this period they conceal the kidney and renal capsule. They consist of tubes which empty into the sinus uro-genitalis, a duct peculiar to fœtal life.

BLADDER.

The bladder is a musculo-membranous sac for the reception of urine. It is situated in the cavity of the pelvis, behind the symphysis pubis, and in front of the rectum, in the male; but in the female, the uterus and vagina are between the bladder and rectum. It is connected with the umbilicus by means of a kind of ligament, called the *urachus*.[1] (Fig. 101.)

Its *shape* is oval, the larger end being downwards; in women it is more spheroidal; in children it is pyriform. It is divided into a superior and inferior *fundus*, a *body*, and *neck*.

Its *dimensions* vary with health and disease. An ordinary healthy bladder will hold nearly a pint. The *round ligaments* of the bladder were formerly the umbilical arteries, and are contained in folds of peritoneum on each side of the superior fundus; besides which, the bladder is held in its place by the *anterior* and *lateral* ligaments, which are processes of the pelvic fascia.

The bladder has four coats, viz., the *peritoneal*, which only covers the posterior part of the body and superior fundus. The *muscular* coat is thicker than that of the intestine; the fibres are pale and unstriped. The external fibres are more longitudinal, and the internal more transverse or circular in their course, and pass in various directions. The *cellular* coat is thick and dense, very distensible and impervious to water. It connects the muscular and mucous coats and transmits the vessels and nerves. The *mucous* coat is soft, smooth, and of a light pink colour. It is covered by an epithelium. It has numerous follicles, which are exceedingly small. The *vesical triangle* is a space within the cavity of the bladder, and included between the two orifices of the ureters[2] and the orifice of the urethra. In the anterior angle there projects in the bladder the *uvula vesicæ*, a prominence of the third lobe of the prostate, covered by the mucous membrane. Under the mucous membrane of the vesical triangle is a plane of fibres,[3] connected with the orifice of the ureters,[2] and that of the ductus ejaculatorius. Surrounding the neck of the bladder is the *sphincter vesicæ*, which consists of a semicircular[4] and a transverse[5] set of fibres.[1] The latter are partly composed of yellow elastic fibres. (Fig. 100.)

Fig. 100.

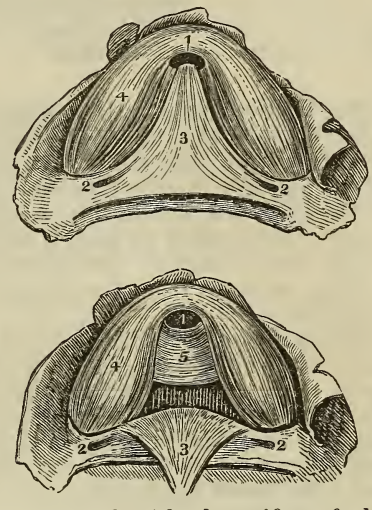

PENIS.

The penis conveys the urine from the bladder, and the semen into the female. The anterior extremity or head is the *glans*,[17] the

posterior extremity is the *root*, and the intervening part is the *body*, which consists of two structures, the *corpus cavernosum* and *corpus spongiosum*.

Fig. 101.

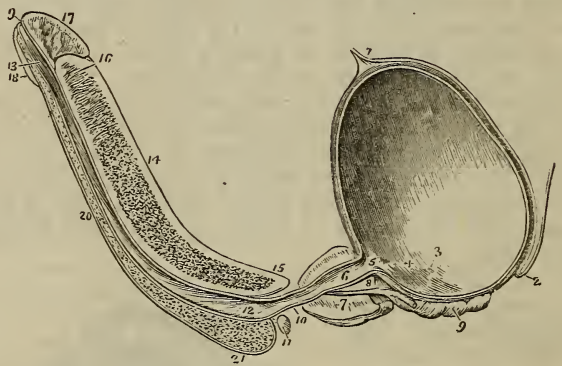

The skin of the penis is thin and delicate, and has numerous hairs and sebaceous follicles. Surrounding the glans is a loose doubling of skin called the *prepuce*, which is connected to the orifice of the urethra by a vertical process called the *frœnum*.

The glans has a thick rim or edge around its base, the *corona glandis*, behind which the penis is narrow, and this portion is known as the *neck* or *collum*. The *glands of Tyson* are the sebaceous follicles, numerous about the *neck* and *crown*, and whose secretion is called *smegma*.

Beneath the skin is the *fascia* of the penis, which is formed of condensed cellular tissue, and is in fact a continuation and modification of the superficial fascia of the abdomen. That portion of the fascia which passes from the pubes to the penis is the *ligamentum suspensorium*, which is triangular in shape and vertical in position, and antero-posterior in direction. The fascia of the penis may be said to be formed by the penis being included between two laminæ of this ligament.

The *corpus cavernosum* forms the largest part of the penis, and is in shape a double cylinder. At the root these cylinders are separate and pointed, and called the *crura*[15] of the penis—each crus is firmly attached to the ramus of the pubes and ischium, constituting the origin of the penis. *Externally* the corpus cavernosum is covered by a dense, thick, fibrous, and elastic coat. *Internally* it consists of a spongy structure made up of cells, which readily communicate with the arteries and veins. There are some arteries

which do not terminate, however, in these cells, but in blind tufts, called *helicine arteries*. The two cylinders are partially separated from each other by the *septum pectiniforme*, a partition which is more complete behind than before, and whose fibres being vertical, somewhat resemble the teeth of a comb, whence the name.

The *corpus spongiosum*[20] occupies the same position with relation to the corpus cavernosum, as a ramrod does to a double-barrelled gun; being contained in a longitudinal groove on its inferior surface, the nutritious vessels occupying a corresponding position above. It is covered by a dense fibrous covering also, but it is thinner than that of the corpus cavernosum. *Internally* it is composed of cells, which are larger than those of the corpus cavernosum.

Posteriorly it touches the triangular ligament; this extremity is enlarged into what is called the *bulb*,[21] which lies between the divergent crura of the penis; anteriorly it forms the glans penis.[17]

The *urethra* is the urinary canal or tube from the bladder, and perforates the corpus spongiosum. It consists of two coats; the external is formed of yellow elastic tissue, and a few involuntary muscular fibres; the internal is mucous, and continuous with that of the bladder. The course of the urethra is curved and its diameter varies.

The first part perforates the upper part of the prostate gland, and is termed the *prostatic portion*;[6] this is an inch in length, and in it we find the *uvula vesica* behind and looking into the bladder; and a triangular elevation of mucous membrane in front, called the *caput gallinaginis* or *verumontanum*. In front of the caput gallinaginis is the utriculus, a small pocket into which empty the ejaculatory ducts. On each side there is a groove perforated with the orifices of the *prostatic ducts*.

The next portion is the *membranous*;[10] this is eight or ten lines in length, and is very narrow; it perforates the triangular ligament, and it is surrounded by loose tissue, and a few muscular fibres called the muscle of Guthrie or compressor urethræ.

The urethra now perforates the bulb of the corpus spongiosum, not directly at its pendulous tip, but through its superior convexity just in advance of its extremity. This portion is the longest, and commences with an enlargement called bulbous;[12] gradually it diminishes in diameter until it reaches the glans, in which it again enlarges and constitutes the *fossa navicularis*.[13] When the urethra is relaxed, longitudinal folds exist in this portion. Numerous mucous follicles are also readily seen, of which the largest is in the *fossa*. The orifices of Cowper's glands open obliquely upon the mucous membrane also, about an inch in front of the glands.

The penis is supplied by the internal pudic arteries and pudendal nerves.

VESICULÆ SEMINALES.

The seminal vesicles consist of two convoluted tubes placed at the posterior and inferior portion of the bladder. They are oblong in shape, and converge downwards and forwards. Each appears to be about two inches in length, but when cleanly dissected and unravelled, it is a tube five inches in length, with numerous pouches or cæca.

The duct of the vesicle is joined by the vas deferens on either side in the prostate gland; the junction forms the *ductus ejaculatorius*, which, passing through the prostate, opens into the urethra in front of the caput gallinaginis. They contain a mixture of mucus and semen.

PROSTATE GLAND.

This is a dense hard structure, about the size of a horse-chestnut, which surrounds the neck of the bladder and the commencement of the urethra. It is of a light colour, and somewhat triangular in shape, the point being in front. It is placed between the rectum which is behind, and the triangular ligament in front.

It is enveloped in a fascia, which is continuous with the posterior lamina of the triangular ligament; it may be divided into two lateral and a middle lobe. The urethra perforates the middle lobe,[8] and the projection of the uvula vesicæ and verumontanum are partially formed by it.

Its structure is composed of tubes united by condensed and hard cellular tissue. The secretion is thick and white, and is discharged by orifices into the urethra on each side of the verumontanum.

Cowper's glands.[11]—These are two in number; placed in front of the prostate, and included between the two laminæ of the triangular ligament. They are about the size of a pea, and of a yellow colour; secreting a mucous fluid which is discharged into the urethra about an inch in front of the gland.

SCROTUM AND TESTICLES.

The scrotum is a bag-like covering for the testicles, formed externally of skin, which is of a dark colour, and thickly covered by hairs and studded with sebaceous follicles. The skin is loose and thin; on its middle is a ridge still darker in colour, which reaches from the anus to the prepuce, called the *raphe*. The transverse wrinkles of the scrotum which cold produces, are due to a structure immediately beneath and intimately connected with the skin, called the dartos.

The *dartos* is a dense, reddish, contractile covering, divided by a partition into two bags. It was once considered muscular, and the remains of the gubernaculum testis; it is principally composed of

the yellow fibrous elastic tissue, with a few unstriped or involuntary muscular fibres. Its contractions are involuntary.

The position of the testicle in fœtal life, and its descent, have been noticed under the head of inguinal hernia. Beneath the dartos is a covering of intercolumnar or external spermatic fascia, and the superficial fascia.

The *cremaster* muscle sends a few fibres and loops upon the anterior and upper part of the testicle, and is sometimes called the tunica erythroides.

The next covering is that derived from the fascia transversalis and infundibuliform fascia. It is sometimes called the internal spermatic fascia, and also tunica vaginalis communis testis; by Cooper it is called the fascia propria.

The *tunica vaginalis* or *peritestis*, is the next covering. It is a serous membrane lining the cavity and reflected over the testicle within; it was originally peritoneum, and is the seat of hydrocele.

The *testicles* are the glands for the secretion of semen. They are two in number, oval in shape, and flattened laterally. They hang obliquely by the spermatic cord, being attached above the middle of the posterior edge; the right is higher than the left.

The *tunica albuginea*,[2] is the dense, white, thick, fibrous coat of the testicle, which gives it shape. In structure it resembles the

Fig. 102.

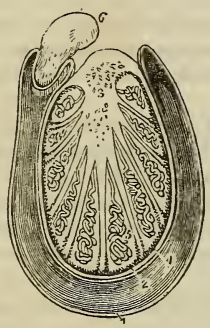

Fig. 103.

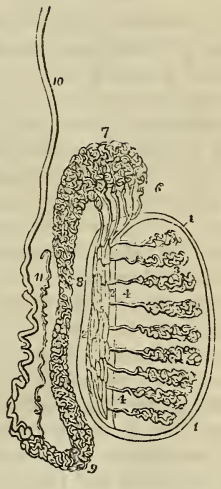

dura mater or sclerotica; externally it is covered by a portion of the peritestis, which is transparent and very closely adherent; from its internal face are given off numerous partitions called *sep-*

tulæ testes, and which, uniting at the posterior edge of the testicle, form that prismatic ridge termed *corpus Highmorianum*.[3]

The testicle is formed by *lobules*, each placed within the spaces between the septulæ. Each lobule[3] consists of a very fine tube, very finely convoluted. Upon its exterior is a capillary network of bloodvessels; interiorly it is lined by epithelium. This tube (*tubulus seminiferus*), becoming straight forms the *vas rectum*;[4] the union of the vasa recta makes the *rete testis*,[5] which is in the corpus Highmorianum; from the upper part of this rete proceed 15 or 20 tubes through the tunica albuginea; they are called *vasa efferentia*;[6] each vas efferens is convoluted in a conical form, and termed *conus vasculosus*; the union of the coni vasculosi forms the commencement of the epididymis.

The *epididymis*[8] is that vermiform appendage encircling the posterior edge, as a crest upon a helmet. It is soft and formed of a single convoluted tube, originating by the junction of the bases of the coni vasculosi. The upper extremity is the larger, and called *globus major*,[7] and the lower is *globus minor*.[9] From the globus minor this tube ascends in a less convoluted form, under the name of the *vas deferens*,[10] which forms one of the constituents of the cord. Connected with the epididymis is the *vasculum aberrans*,[11] a small, blind, convoluted duct.

SPERMATIC CORD.

Each spermatic cord consists of an artery and vein, and nerves, together with the duct, vas deferens. These constituents are united by cellular tissue, which may be the remains of that canal of peritoneum peculiar to fœtal life.

It is covered by the fascia transversalis prolonged from the abdomen, by the cremaster muscle, which has been previously described; and by the external spermatic or infundibuliform fascia.

The *spermatic artery* comes from the aorta, and sometimes from the renal. It is tortuous, and after passing through the rings divides into two or three branches; the termination of the artery is larger than its origin.

The *spermatic* veins are very tortuous and numerous, and on account of their vine-like appearance are termed *vasa pampiniformia*. They are the seat of circocele.

The *external spermatic nerves*, and also branches of the abdomino-crural, supply the muscular structure; filaments of the sympathetic run also to the testicle.

The *vas deferens* is a continuation of the epididymis. Passing through the cord and rings, it descends behind the bladder and joins the duct of the vesiculæ seminales. It is very hard, and readily recognised by touch; its walls are extremely thick, and its bore almost capillary. It is nearly white, and thicker than a knitting-needle.

THE PERINEUM.

The perineum is that space included between the anus, arch of the pubes, and the tuberosities of the ischia.

Fig. 104.

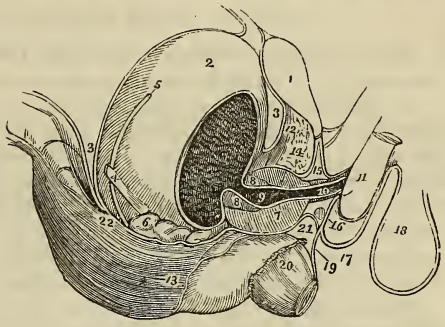

In a proper dissection the removal of the skin reveals the *superficial fascia*, which is continuous with the superficial fascia of other parts of the body. When this is removed, the *perineal fascia* is exhibited, which is a dense, thin, and tough fascia,[17] adhering to the rami of the pubes and ischium on each side; in front it is continued into the scrotum; behind it is continuous with the base of the triangular ligament by its anterior lamina,[16] and also with the *anal fascia*,[19] a portion of the pelvic fascia. It covers the muscles of the perineum and sends processes between them. Posteriorly it winds around the transversus muscle to join the triangular ligament. Its connections laterally and behind account for the course taken by extravasated urine from rupture of the urethra.

The *triangular ligament*[18] called also deep perineal fascia, lies under the muscles of the perineum, fills up the arch of the pubes, and is shaped as its name implies. It is a fibrous membrane, separating the pelvis from the perineum. The base, which is not so dense and fibrous as its apex, joins the perineal and anal fascia.[21] It is perforated by the membranous portion of the urethra, about one inch below the symphysis.

It consists of two laminæ,[16 21] between which are situated Cowper's and the prostate gland;[7] thus the fascia of the prostate, as it is usually called, is merely the posterior lamina of the triangular ligament.

PELVIC FASCIA.

This fascia is continuous with the transversalis and iliac fascia surrounding that portion of the peritoneum which lines the pelvis. Like all fasciæ, it is easily divided into laminæ; different portions receiving different names.

It may be said to commence at the brim of the pelvis, and by its intervention the different viscera are united with each other, and held in their proper positions. Thus, two processes of it on the sides of the

bladder form the *anterior ligaments of the bladder*. A layer covering the obturator muscle is called the *obturator fascia*. The levator ani muscle is included between two layers of this fascia; that portion between the rectum and bladder is called the *recto-vesical fascia;* and that which covers the lower part of the rectum is the anal fascia.

MUSCLES OF THE PERINEUM AND ANUS.

Erector penis.[3]—*Origin*, from the tuberosity of the ischium. *Insertion*, by a broad flat tendon into corpus cavernosum.

Accelerator urinæ,[1] *or ejaculator seminis.*—It lies on the bulb of the corpus spongiosum. *Origin*, from the crus of the penis, and the ramus of the pubes; and also by a tendinous membrane which is between the corpus spongiosum and corpus cavernosum, and is continuous with the fascia of the penis. The fibres are semi-pennate, and with those of its fellow surround the bulb. *Insertion*, by a white tendinous line into its fellow, and into the *perineal centre*, which is formed by the junction of several muscles.

Transversus perinei.[4]—*Arises* from the tuberosity of the ischium, and is *inserted* into the perineal centre. Sometimes there is an additional portion in front, called *transversus perinei alter.*

Sphincter ani.[6]—A thick muscular ring surrounding the anus. Its superficial fibres are elliptical. It is connected with the coccyx and perineal centre.

Fig. 105.

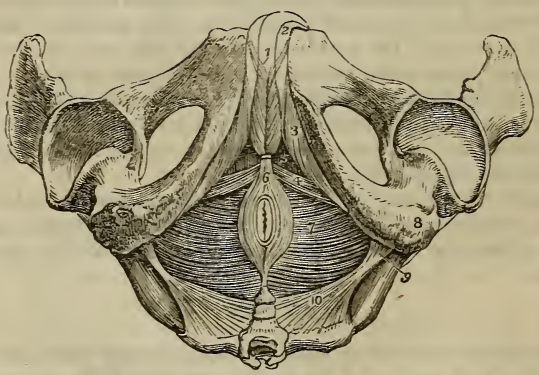

Coccygeus.[10]—*Origin*, from the spine of the ischium. *Insertion*, into the side of the coccyx and last bone of the sacrum.

Sacro-coccygeus.—A few fibres passing from the sacrum to the coccyx in front.

Levator ani.[7]—Is a plane of muscular fibres. *Origin*, from the interior of the body of the pubes, the superior edge of the thyroid foramen, the upper edge of the obturator fascia, and the spine of the ischium. *Insertion*, by converging and descending fibres into the lateral semi-circumference of the rectum; also in the coccyx and perineal centre.

ORGANS OF RESPIRATION AND CIRCULATION.

LARYNX.

The *larynx* is a canal formed of cartilages, which move in such a manner as to regulate the voice.

It is situated in the upper and anterior part of the neck, in the median line, below the hyoid bone.

It forms the commencement of the windpipe; is cylindrical below but prismatic above; it is larger in males than in females.

The cartilages of the larynx are five in number; thyroid, cricoid, two arytenoid, and epiglottis.

The *thyroid* is the largest; it occupies the upper and anterior portion of the larynx. It consists of two quadrilateral plates, which are united in an acute angle in the median line in front; this angle is usually called the *pomum Adami*,[5] which is much larger in men; it has a deep notch at its upper part.[4] The upper edge[3] is curved, and has the middle thyreo-hyoid ligament attached to it; the lower edge[6] is also curved, and to it is attached the middle crico-thyroid ligament. The posterior edge terminates in two processes called cornua, of which the superior[8] is the longer, and is attached to the lateral thyreo-hyoid ligament. The *inferior cornu*[9] is short and curved, and receives the lateral crico-thyroid ligament. Upon the external surface[1] is an oblique ridge, passing between two tubercles, from which arise the thyreo-hyoid and inferior constrictor muscles.

Fig. 106.

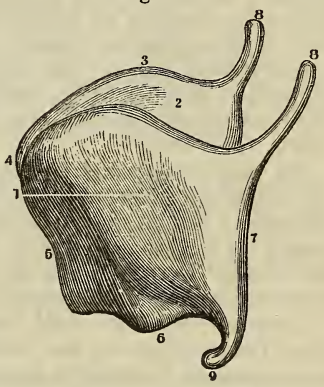

The *cricoid cartilage* is next in size (Fig. 107), and situated at the base of the larynx; its form is that of a thick ring compressed laterally; its lower edge[3] is circular, and attached to the trachea; its upper edge is oval and oblique, on account of the cartilage being three times as thick behind as it is in front; the posterior portion of the superior edge has two heads[4] of a peculiar convexity, for articulating with the arytenoid cartilages; the external surface poste-

riorly is flattened, giving origin to the posterior crico-arytenoid muscle.

Fig. 107. Fig. 108. Fig. 109.

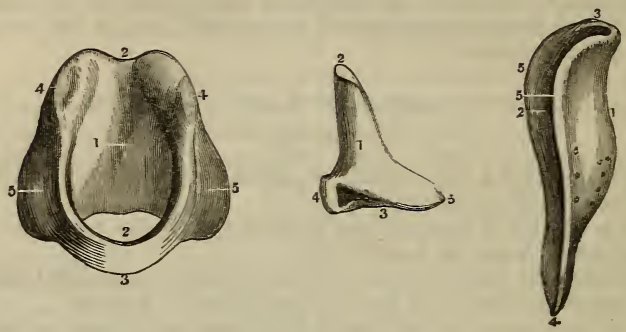

The *arytenoid cartilages* are situated at the upper and back portion of the larynx. They are two in number, and are of a pyramidal shape. The base[3] is concave, and articulates with the heads of the cricoids; the apices[2] have attached to them a small cartilage called *corniculum laryngis*, or *tubercle of Santorini*. The posterior surface[1] is triangular and concave, for the insertion of the posterior crico-arytenoid muscle; the internal surface is flat, and can be adjusted to its fellow; the anterior or external surface is uneven, to which are attached the superior and inferior thyreo-arytenoid ligaments. (Fig. 108.)

The *epiglottis cartilage* is a thin, oval, cartilaginous plate, behind the root of the tongue, and attached to the angle of the larynx; it resembles a leaf in shape; its direction is vertical; its inferior extremity[4] is narrow and pointed; its superior edge is thin, its anterior surface[1] is slightly convex, and its posterior[2] concave. It is perforated by numerous foramina. (Fig. 109.)

These cartilages are held together by numerous ligaments, of which the principal are, the *middle thyreo-hyoid;* a thin membranous expansion between the inferior circumference of the hyoid bone and the superior edge of the thyroid cartilage: the *lateral thyreo-hyoid;* which is funicular, extending from the great cornu of the thyroid cartilage to the tubercle of the cornu of the hyoid bone; in it is found a small oval cartilage or bone, called *cartilago triticea;* the *middle crico-thyroid*, a thick membrane, filling up the space between the superior edge of the cricoid and inferior edge of the thyroid cartilages; this is usually divided in the operation of laryngotomy; and the *lateral crico-thyroid*, reaching from the inferior cornu of the thyroid to the side of the cricoid; a *capsular ligament* surrounds the joint between the arytenoid and cricoid.

Within the larynx are two *thyreo-arytenoid ligaments* on either

side. The *inferior* ligaments extend from the angle of the thyroid to the base of the arytenoid, and are usually called the vocal cords; the space between them is the *rima glottidis*. The *superior* ligaments extend from the angle of the thyroid to the middle of the arytenoid cartilages. The space between them is the glottis. These ligaments are not cords, as they appear to be, but merely edges of a membrane lining the larynx, and composed of yellow elastic fibrous tissue.

The mucous membrane lining the larynx is continuous with that of the mouth, and forms numerous folds between the cartilages, of which the most remarkable is a pouch between the superior and inferior thyro-arytenoid ligaments, which has been called the *ventricle* of the *larynx*, or ventricle of Galen. To the ventricle of either side is attached an additional pouch, which is called the *sinus of Morgagni*. In the fold between the arytenoid and epiglottis cartilages is a small *gland*, called the *arytenoid*, which is of the shape of the letter L.

The muscles of the larynx move the various cartilages, and modulate the voice.

Thyreo-hyoid.—This was described with the muscles of the neck.

Crico-thyroid, arises from the anterior and lateral surfaces of the cricoid, and passes backwards to be inserted into the inferior cornu of the thyroid; it draws these two cartilages together obliquely.

Posterior crico-arytenoid,[7] arises from the flat surface on the back of the cricoid, and is inserted into the posterior part of the base of the arytenoid; it draws the arytenoid backwards, and thus tightens the vocal ligaments. (Fig. 110.)

Lateral crico-arytenoid.[8]—Arises from the side of the cricoid, and is inserted into the side of the base of the arytenoid; it separates the arytenoid from its fellow, and widens the glottis.

Thyreo-arytenoid.[8]—Arises from the posterior face of the thyroid near the angle, and is inserted into the anterior surface of the arytenoid, which it draws forwards, and thus relaxes the vocal ligaments.

Oblique arytenoid.[5]—They consist of oblique fibres arising from the top of one cartilage, and inserted into the base of another. (Fig. 111.)

Transverse arytenoid.[6]—Arises from the side of one cartilage, and is in-

Fig. 110.

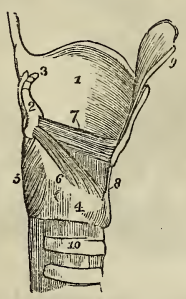

Fig. 111.

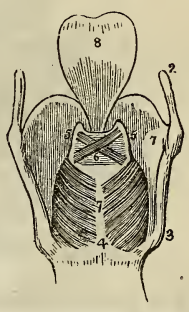

serted into the side of the other. These last two muscles are often considered as one, and by them the glottis is narrowed.

Thyreo-epiglottideus.—Consists of a few fibres passing between these two cartilages.

Aryteno-epiglottideus.—A few indistinct fibres passing between the cartilages from which it derives its name. These last two draw the epiglottis downwards.

TRACHEA.

The trachea is a cylindrical tube, four or five inches in length, reaching from the larynx as low as the third dorsal vertebra, where it divides into the *bronchi*. It is formed of from *sixteen* to *twenty* rings of *cartilage*, united by *ligamentous* tissue, which is of an elastic character. Each ring is about two lines broad and constitutes two-thirds of a circle; the first ring is the largest, and the last ring is of such a shape as to be adapted to the first rings of the bronchi.

Fig. 112.

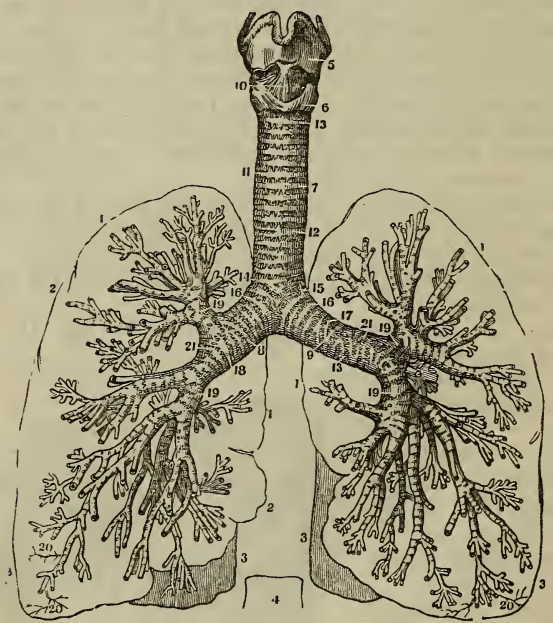

The posterior third of the trachea is completed by an involuntary *muscular* structure, whose fibres are transverse, and the contraction

of which diminishes its diameter, by which expectoration is facilitated; it is lined by a *mucous* membrane continuous with that of the larynx, which is extremely vascular, and covered with numerous follicles. At the bifurcation of the trachea into the bronchi, there are a number of hard, *black* glands, which are lymphatic in their character, and called *bronchial* from their position.

The *bronchi* are essentially of the same structure and arrangement as the trachea; the right bronchus is shorter, and of a larger diameter than the left; they soon ramify into numerous subdivisions, which finally terminate in the lobules of the lungs. In the smaller ramifications of the bronchi there is some modification of structure; the tube is no longer flattened behind, because the cartilages form complete circles; the cartilages are less numerous; each cartilaginous ring is not composed of a single piece, but of several segments of a circle; there is also a semilunar cartilage at each of the lesser bifurcations.

THYROID GLAND.

It is situated in front of the first two rings of the trachea, and upon the sides of the larynx; it consists of two lateral lobes, placed on either side, united by a narrow isthmus in front; it is extremely vascular, of a reddish-brown colour, and of tolerably firm consistence. A process called the pyramid or middle lobe sometimes extends from the isthmus to the hyoid bone. Occasionally a small, narrow muscle attaches one lobe to the hyoid bone. It is granular in its structure, has no excretory tube, but very large lymphatic vessels. It consists of minute closed vesicles, surrounded by capillary vessels, and invested by areolar tissue. These vesicles are composed of an external capsule, and a yellow fluid containing corpuscles resembling cell-nuclei: albumen enters largely into the composition of the fluid. It is supplied by the superior and inferior thyroid arteries. It is sometimes much enlarged, constituting bronchocele or goitre.

THE LUNGS.

The lungs are the organs of respiration properly; they are two in number, and situated in the thorax, placed side by side, being separated from the abdomen by the diaphragm. The size varies with the capacity and condition of the thorax, age, inspiration, expiration, and disease. They are conical in shape, are longer posteriorly than anteriorly, and have concave bases. The colour of the lungs is of a pinkish-gray, mottled with black; these black spots are more numerous in adult life than in infancy.

The right lung is shorter but larger than the left, whose transverse diameter is somewhat diminished by the position of the heart. It has three lobes, the left having but two.

The *structure* of the lungs is spongy, and its compression between

the fingers produces a crackling called *crepitation.* It consists of a number of air-vesicles held together by cellular tissue, called *parenchyma;* through which blood-vessels and air-vessels are ramified. A certain number of air-cells communicate with each other, and

Fig. 113.

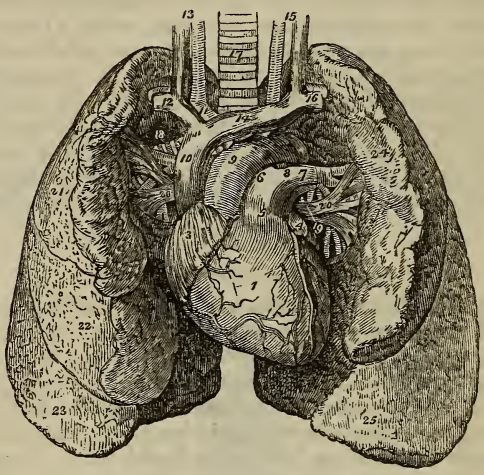

with a single branch of the bronchial tube; these are separated from neighbouring cells by partitions of parenchyma, and thus are formed *lobules.* These subdivisions are evident upon the external surface of the lung. The air-vesicles are formed of ligamentous tissue lined by a mucous membrane.

The *root* of the lung, consists of the bronchus, pulmonary artery, two pulmonary veins, bronchial artery and vein, nerves, and lymphatics. These enter upon its internal surface, and in some degree retain the lung in its proper position. The branches of the pulmonary artery terminate in capillaries, upon the walls of the air-vessels, from which arise the branches of the pulmonary veins.

The bronchial artery is the nutritious artery of the lung. Its nerves are derived from the sympathetic and eighth pair.

PLEURÆ.

The pleura is a serous membrane investing each lung, and then reflected upon the parietes of the chest. That portion in contact with the chest is called *pleura costalis;* that covering the lung, *pleura pulmonalis.* It also covers the diaphragm and the root of the lung, between which there exists a fold called *ligamentum pulmonis.*

MEDIASTINUM.

The space between the two pleuræ of the lungs is called the mediastinum, and it is divided, by the position of the heart, into the anterior, posterior, and superior mediastinum.

The *anterior mediastinum* is that space between the sternum and the heart; it contains some loose cellular tissue, and a portion of the remains of the thymus gland.

The *posterior mediastinum* is that region between the vertebral column and the heart, and through it passes the œsophagus, par vagum nerve, aorta, vena azygos, and the thoracic duct.

The *superior mediastinum* is above the heart, and surrounded by the first ribs and sternum; it contains the roots of the large vessels, and the remains of the thymus gland.

THYMUS GLAND.

This is a triangular body of a pinkish hue, occupying a portion of the superior and anterior mediastina. It grows until the end of the second year, after which it diminishes, and almost entirely disappears. It has a large lymphatic vessel, which has been supposed to be an excretory duct. Its structure is lobulated, and surrounded by loose cellular tissue. Each lobule contains several membranous cells or vesicles, which contain a white fluid and open into a central cavity or reservoir. The fluid contains corpuscles resembling the white blood corpuscle and the chyle corpuscle.

PERICARDIUM.

The pericardium is a membranous sac, in which the heart is contained. It consists of two layers, the external of which is fibrous, dense, and white, and the internal is serous. The serous lamina lines the fibrous layer, and then is reflected over the heart and the roots of its vessels.

THE HEART.

The heart is a hollow muscular organ, surrounded by a membranous sac called the pericardium. It is situated between the two pleuræ, and rests upon the cordiform tendon of the diaphragm, in the cavity of the thorax.

Its *shape* is conoidal, though it is somewhat flattened upon that side which rests upon the tendon of the diaphragm. Its apex inclines to the left side, touching the walls of the thorax, between the fifth and sixth ribs. It *measures* five inches and a half from its apex to its base, three inches and a half in the diameter of its base, and *weighs* about six or eight ounces. It contains *four cavities*, which perform two functions, that of receiving the blood and throwing it into the lungs, and that of receiving it again after it has been oxygenated, and distributing it throughout the body. The receptacles are

auricles, and the *ventricles propel* the blood to the lungs and through the system.

The auricle and ventricle of the *right side* receive and propel the venous blood into the lungs. The auricle and ventricle of the *left side* receive and propel the arterial blood throughout the body.

The *circulation* of the blood is as follows: the ascending and descending vena cava empty the venous blood into the right auricle; from here it passes to the right ventricle, through an opening protected by a valve opening downwards; from the right ventricle it is propelled through the pulmonary artery, which divides into two branches, to the lungs; after it has been subjected to the influence of the respiratory process, it is brought from the lungs, by four pulmonary veins, into the left auricle. The left auricle has an opening into the left ventricle, protected by a valve opening downwards, and from the left ventricle it passes into the aorta, thence to be distributed throughout the body.

The *right auricle*[1] is an irregularly-shaped cavity, somewhat oblong and cuboidal; anteriorly it has a convexity which is called its *sinus;* superiorly there is an elongated process resembling the ear of an animal, whence the term auricle. Its walls are thin, and composed of muscular fibres, which from their parallel arrangement resemble the teeth of a comb, and hence are called *musculi pectinati.* The superior[5] and inferior vena cavæ enter the auricle from behind, and between their orifices there is an elevation, called *tuberculum Loweri.* On the septum or partition between the auricles, is a depression called *fossa ovalis*, where formerly existed the foramen ovale of fœtal life; the ring or edge surrounding it, is called the *annulis ovalis*, from which there extends downwards to the inferior semi-circumference of the ascending cava, a crescentic doubling of the lining membrane, which is the remains of the *Eustachian* valve. The *coronary* veins open into this cavity, and their orifice is protected by the *valve of Thebesius.* The opening to the ventricle, called the *ostium venosum*, is circular and surrounded by a dense white line.

Fig. 114.

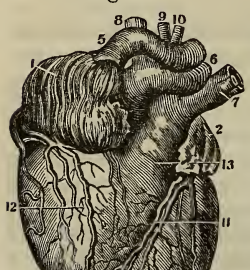

The *right ventricle*[3] is a triangular cavity, with thick walls, and of greater capacity than any other cavity of the heart. Its muscular structure is in the form of large fleshy bundles, called *columnæ carneæ*, from which proceed thin, white cords, called *chordæ tendineæ*, which are attached to the edge of the *tricuspid valve.* The tricuspid valve is circular, and its upper edge is attached to the tendinous line of the ostium venosum; its lower edge has three spear-

pointed or leaf-like processes, whence its name; since it opens downwards, the contraction of the ventricle closes the ostium venosum, and prevents the blood from returning into the auricle, and therefore it passes out by the *pulmonary artery*. The orifice of the *pulmonary artery* is protected by three valves opening outwards, which are called semilunar valves, formed by three crescentic folds of the lining membrane; in their loose edges there is often a small tubercle, called *corpus Aurantii:* the use of these valves is to prevent the blood returning from the artery to the ventricle, when it dilates. Behind each valve is a pouch or dilatation, called the *sinus of Valsalva*, into which the blood flows by its reflux tendency, upon the dilatation of the ventricle, and thus these valves are closed. The pulmonary artery is of the same diameter as the aorta, but its walls are thinner; after its origin it curves upwards and backwards, and divides into two branches, the right of which is larger than the left,[7] and passes under the arch of the aorta.

The *left auricle*[2] is more concealed in its natural position than the right. Into it enter four pulmonary veins, which give it a quadrangular shape. Its walls are muscular, and somewhat thicker than those of the right auricle. In its ear-like appendage the muscular fibres are arranged as *musculi pectinati;* the opening, by means of which it communicates with the left ventricle, is called *ostium venosum*, and surrounded by a white tendinous ring. The septum between the auricles is not always perfect even in adult life.

The *left ventricle.*[4]—This cavity forms the apex of the heart; it is conoidal in its shape. Its walls are thick, and its *columnæ carneæ* numerous, strong, and projecting; the *chordæ tendineæ* are well developed, and attached to the *bicuspid* or *mitral valve.* This valve consists of but two leaflets, one of which is much larger than the other; its base is attached to the ring surrounding the ostium venosum, and its edge opens downwards into the left ventricle: hence the contraction of the ventricle closes this opening, and the blood passes out by the *aorta*,[6] at whose orifice there are three *semilunar* or *sigmoid* valves, each having a corpuscle of Arantius in its edge, and *sinuses* of Valsalva or Morgagni behind them. The vessels supplying the heart with blood are the right and left coronary arteries;[11 12] the veins which accompany them empty by a common trunk into the right auricle. The nerves are derived from the cardiac plexuses of the sympathetic.

SECTION V.

VESSELS.

STRUCTURE OF ARTERIES.

Arteries are composed of three coats; external, middle, and internal.

The external is firm and strong, formed of condensed cellular tissue; it does not yield upon the application of a ligature.

Fig. 115.

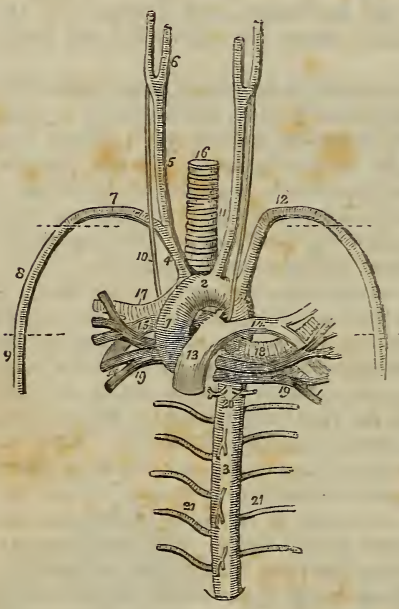

The middle is formed of elastic, fibrous tissue, and was formerly called the muscular coat. It is thick, and its fibres are arranged circularly; in which direction they readily yield to a ligature. It contains a few involuntary muscular fibres.

The internal is a thin, serous covering, which diminishes the friction of the passage of the blood. It is smooth and transparent, and readily torn.

Arteries convey blood *from* the heart, and *veins* carry blood *to* the heart; thus, the pulmonary artery conveys blue or what is usually called venous blood, and the pulmonary veins convey red or what is termed arterial blood.

The nutritious vessels of the arteries are called *vasa vasorum*, and their nerves are derived from the sympathetic.

AORTA.

The aorta arises from the left ventricle opposite the articulation of the fourth costal cartilage with the sternum. At first it ascends to the right, then curves backwards and to the left, and descends on the left side of the vertebral column to the fourth lumbar vertebra.

The *ascending aorta* is partially covered in front and at its origin by the pulmonary artery. The upper edge of the *arch* is on a level with the second dorsal vertebra, and under it passes the right pulmonary artery. It is frequently enlarged into a *sinus* in old persons. The descending aorta[3] while passing through the thorax is termed *thoracic*, and while passing through the abdomen, *abdominal.*

The coronary arteries are the first branches of the aorta, and are distributed to the heart, through the grooves between the auricles and ventricles. They arise just beyond the semilunar valves.

The Innominata.[4]—This artery arises from the arch of the aorta, is an inch and a half in length, ascends obliquely towards the right side in front of the trachea, and behind the transverse vein. Opposite the sterno-clavicular articulation, it divides into the right carotid and right subclavian. (Fig. 115.)

The right carotid[5] arises from the innominata, and ascends the neck as far nearly as the hyoid bone, where it divides into the external and internal carotids.

The left carotid[11] arises from the arch of the aorta, ascends obliquely through the thorax until it reaches the neck, and then it is distributed as the right. Each primitive carotid is on the inner side of the internal jugular vein, with which and the par vagum nerve it is included in a sheath. (Fig. 115.)

Fig. 116.

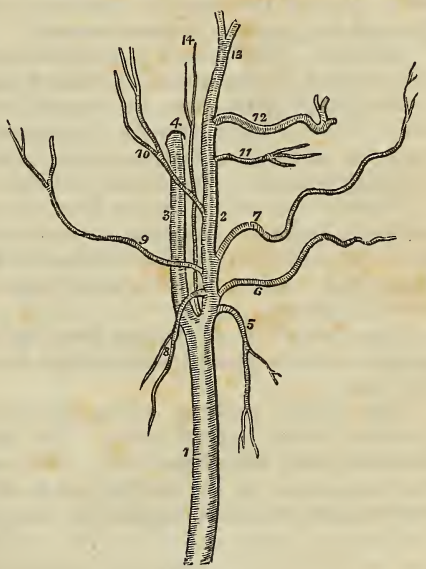

EXTERNAL CAROTID.

(Fig. 116.)

It ascends perpendicularly from the bifurcation of the carotid, and passing through the deep portion of the parotid gland it divides into the *internal maxillary*[12] and *temporal.*[13]

Superior thyroid,[5] arises near the root of the external carotid and is its first branch; it pursues a curved course downwards and is distributed to the thyroid gland, after giving off a *laryngeal branch.* (Fig. 116.)

Lingual,[6] ascends obliquely from its origin, which is just above the superior thyroid. It penetrates the hyoglossus muscle just above the cornu of the hyoid bone, and then courses between the muscles of the tongue, giving off the dorsalis linguæ, sublingual and ranine branches. The ranine reaches the tip of the tongue.

Facial.[7]—This arises above the lingual, is tortuous, becomes imbedded in the submaxillary gland, and then passes over the lower jaw, in front of the insertion of the masseter muscle, and gives off several branches to the face.

Sub-mental, arises from the last, and supplies the chin.

Masseteric, also arises from the facial, and is distributed to the masseter muscle.

Inferior labial, is spent upon the integuments and muscles between the chin and the lip.

Superior and inferior coronary, surround the lips and mouth. The remainder of the facial artery is distributed by a branch upon the side of the nose and one to the inner angle of the eye, where it anastomoses with the ophthalmic.

Inferior pharyngeal,[14] arises near the bifurcation of the carotid, or from the external carotid, and is distributed to the pharynx. It often gives off the *posterior meningeal*, which enters the cranium through the *posterior foramen lacerum*.

Mastoid.[8]—This branch is irregular and uncertain in its origin, and supplies the muscles and glands of the neck.

Occipital,[9] arises from the external carotid a little below the facial, forming a loop with the hypoglossal nerve; it is distributed upon the muscles and integuments upon the back of the head, anastomosing with the temporal and its fellow.

Posterior auricular,[10] arises from the external carotid, ascends obliquely backwards, beneath the parotid gland, and passing between the external meatus and mastoid process, is distributed upon the integuments. A branch of it, called *stylo-mastoid*, enters the stylo-mastoid foramen.

Transversalis faciei,[11] arises from the carotid, and crossing the masseter muscle parallel with the duct of Steno, is distributed upon the face.

The anterior, posterior, and middle temporal are the terminating branches of the temporal artery. The *anterior* is distributed upon the temple and side of the head. The *posterior* is distributed upon the integuments on the back of the head. The *middle* perforates the temporal fascia and supplies the temporal muscle.

INTERNAL MAXILLARY.

This[12] commences at the bifurcation of the external carotid, and pursues a very tortuous course, supplying the back portions of the

mouth and palate. At first it is horizontal, then ascending, it terminates in a horizontal course. Its branches are numerous, and are as follow : (Fig. 117.)

Fig. 117.

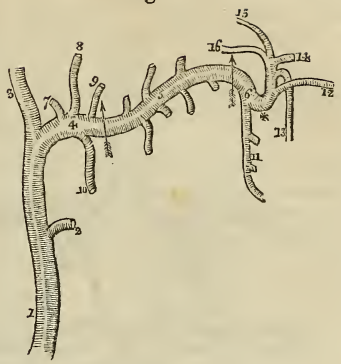

Tympanic,[7] is distributed to the tympanum through the Glaserian fissure.

Meningea magna,[8] passes through the foramen spinale and becomes the middle artery of the dura mater.

Meningea parva,[9] arises from the last or near to it, and is also distributed to the dura mater, having entered the cranium through the foramen ovale.

Inferior dental,[10] descends to the posterior mental foramen, and supplies the teeth of the lower jaw, then emerging at the anterior mental foramen, anastomoses with the facial.

Deep temporal.—These are two branches distributed to the temporal muscles.

Pterygoid and Buccal.—These are muscular branches supplying the muscles and the lining of the cheek.

Superior dental, or alveolar, or maxillary,[11] descends, and winding round the tuberosity of the upper jaw, gives off branches to the molar teeth, antrum, and gums.

Infra-orbital,[12] enters the orbit of the eye, and passes along the infra-orbital canal; it sends branches to the teeth and integuments of the face.

Superior palatine,[13] passes through the posterior palatine foramen, and supplies the mouth and palate.

Superior pharyngeal,[15] supplies the upper part of the pharynx and the Eustachian tube; from it arises the *vidian*.[16]

Spheno-palatine,[14] enters the nose through the spheno-palatine foramen, and is distributed by branches to the mucous membrane of the nose.

ARTERIES OF THE BRAIN.

The arteries at the base of the brain are derived from the vertebrals and internal carotids. (Fig. 118.)

The *vertebral* arteries[1] enter the cavity of the cranium through the foramen magnum occipitis, and coalescing, form a thick trunk called the *basilar*.[6] Previous to their union are given off the *anterior*[2] and *posterior*[3] spinal arteries. The *inferior cerebellar* arises from the vertebral also. The basilar pursues its course along the median line of the pons varolii, giving off several branches in its

Fig. 118.

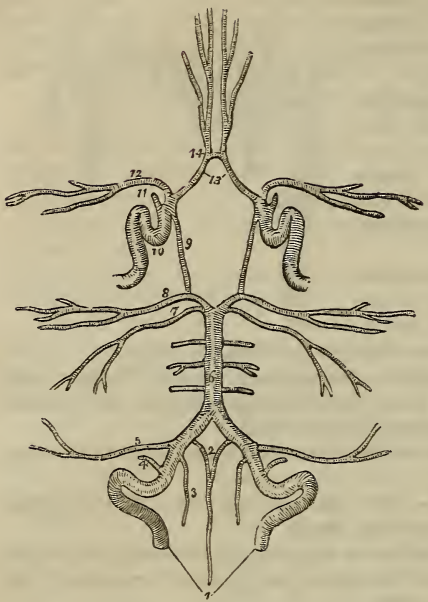

course. The principal being the *superior cerebellar*[7] and the *posterior cerebral* arteries.[8]

The *posterior communicating*[9] joins the carotid[10] with the posterior cerebral.

From the carotid, which enters through the carotid canal, are given off the *ophthalmic*,[11] *middle cerebral*,[12] and *anterior cerebral arteries*.[13] The two anterior cerebral arteries are connected by a transverse branch[14] called the *anterior communicating* artery, and thus is formed the circle of Willis. These vessels are distributed to the *pia mater*, and the substance of the brain.

SUBCLAVIAN.

The *subclavian*[3] of the right side arises from the innominata,[1] and the subclavian of the left side from the arch of the aorta. The right is shorter and more superficial than the left. The subclavian emerges from the thorax by passing over the first rib between the anterior and middle scaleni muscles. Its branches are numerous, and vary in their mode of origin. Some arise by a common origin,[5] called the *thyroid axis*.

Fig. 119.

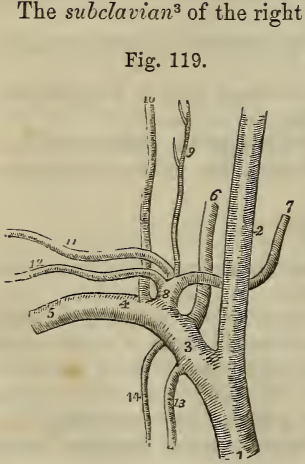

Vertebral,[6] is the first and largest branch of the subclavian. It passes through the foramina of the transverse processes of the six superior cervical vertebræ, and enters the cavity of the cranium through the foramen magnum occipitis.

Inferior thyroid,[7] arises from the thyroid axis or the subclavian, and curves forwards and upwards behind the great vessels of the neck to supply the thyroid gland, giving off the *ascending* or *superficial cervical*.[9]

Superior intercostal,[14] arises from the subclavian, and descending, supplies the two upper intercostal spaces. It frequently gives off the *profunda cervicis*.[10]

Internal mammary,[13] is larger than the last, and entering the cavity of the thorax, descends within a few lines of the sternum, giving off branches to the diaphragm, thorax, and abdomen.

Posterior or transverse cervical,[11] arises from the subclavian in an irregular manner, and winds round the root of the neck, in front of the brachial plexus and scalenus anticus muscle, until it reaches the base of the scapula, along which it descends, and supplies the muscles upon the back. The subclavian artery, passing under the subclavius muscle, is afterwards called *axillary*.

Profunda cervicis,[10] arises from the subclavian or the superior intercostal. It ascends the back of the neck between the complexus and semi-spinalis colli muscles.

Supra-scapular, or transversalis humeri.[12]—This usually arises from the thyroid axis, but sometimes from the axillary. It passes over the scapula, and supplies the muscles upon its dorsum, sending a small branch through the coracoid notch.

Fig. 120.

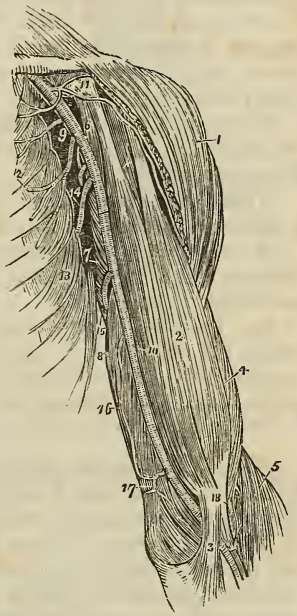

AXILLARY.

This artery may also be considered as extending from the lower edge of the subclavius muscle to the lower margin of the tendon of the latissimus dorsi.

External mammaries.—Usually are four in number, arising singly or together, from the axillary. They are the *acromial thoracic*,[11] distributed upon the shoulder, and sending a branch between the pectoralis major and deltoid muscles; *superior* and *inferior thoracic*,[12] which are distributed upon the *pectoralis* and the *serratus magnus muscles;* and the

axillary thoracic, which is distributed to the fat and glands of the axilla.

Scapular.[14]—This is the largest branch of the axillary; it passes along the external edge of the scapula, and gives off a large branch, called *dorsalis scapulæ,* which anastomoses with the supra-scapular, on the dorsum of the scapula.

Anterior and Posterior Circumflex, arise from the axillary, opposite the neck of the humerus. The anterior is small, and supplies the front of the joint; the posterior is large, and passes backwards, supplying the joint and deltoid muscle. Sometimes it arises from the *profunda major.*

BRACHIAL.

The *brachial* artery extends from the axilla to the elbow joint, descending upon the inner edge of the coraco-brachialis and biceps flexor muscles, in company with the median nerve. (Fig. 120.)

Profunda major,[15] arises from the brachial at its upper part, and passing between two heads of the triceps muscle, with the spiral nerve, supplies the external portion of the arm, and at the external condyle inosculates with the radial recurrent.

Profunda minor,[16] is small, arises below the last, is distributed superficially about the internal condyle, and anastomoses with the ulnar recurrent.[18]

Nutritious artery, arises opposite the nutritious foramen of the humerus, which it enters to supply the bone.

Anastomotic,[17] arises from the brachial just above the elbow, and winding round the internal condyle, anastomoses with the ulnar recurrent. (Fig. 121.)

The brachial, passing under that portion of the brachial fascia which is connected with the tendon of the biceps, divides into the *radial* and *ulnar,* although this division may take place at any point between the arm-pit and elbow.

RADIAL.

The *radial*[12] is more superficial than the ulnar. It descends the outer side of the arm,[12] between the tendons of the supinator radii longus and flexor carpii radialis.

Radial recurrent,[13] arises from the radial and inosculates with the profunda major. In its descent, the radial gives off numerous muscular branches, until it reaches the wrist, it then passes backwards under the extensor tendons of the thumb.

Superficialis volæ,[14] is given off from the radial, and distributed upon the palmar surface of the thumb, joining the superficial arch.

Dorsalis carpi, arising from the radial, is distributed upon the back of the wrist beneath the extensor tendons.

Magna pollicis, one of the terminating branches of the radial, supplying the thumb.

Radialis indicis,[17] arises in connexion with the last, and is distributed upon the radial side of the forefinger.

Palmaris profunda, or *deep arch,* another terminating branch of the radial, which passes between the flexor tendons and bones of the metacarpus, to join the cubitalis manus of the ulnar.

ULNAR.

It passes[15] under the bellies of several superficial muscles arising from the internal condyle, and descends the inner side of the arm, between the tendons of the flexor carpi ulnaris and flexor sublimis muscles; then passes over the annular ligament of the wrist, to form the superficial arch. (Fig. 121.)

Fig. 121.

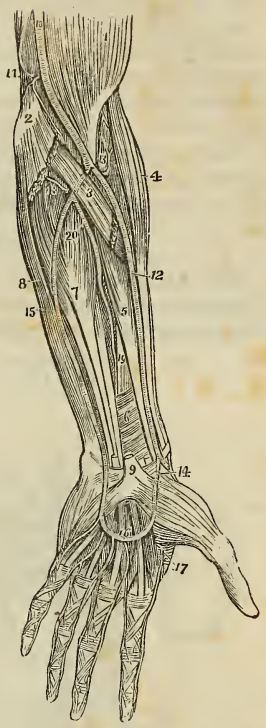

Ulnar recurrent,[18] arises from the ulnar near its commencement, and then winding under the internal condyle, anastomoses with the anastomotic.

Interosseous,[19] arises from the ulnar opposite the tubercle of the radius, and divides into an anterior and posterior branch; the anterior interosseous descending to the wrist in front of the interosseous ligament; the posterior perforates the ligament, and is distributed to the extensor muscles of the arm.

Dorsalis manus, arises from the ulnar, and is distributed upon the back of the hand.

Superficial arch,[16] is a continuation of the ulnar artery, immediately beneath the palmar fascia.

Cubitalis manus profunda, a branch of the ulnar, arising near the superficial arch; it joins the deep arch.

Digital arteries.—These are three in number, and arise from the superficial arch. At the metacarpo-phalangeal articulation, they divide into the digito-radial and digito-ulnar, for each side of the finger. The ulnar side of the little finger is supplied by a distinct branch from the superficial arch.

THORACIC AORTA.

The Thoracic Aorta descends upon the left side of the vertebral column through the posterior mediastinum.

Bronchial,[20] vary in size and origin. Sometimes arising by a

common trunk from the arch of the Aorta. They enter the root of each lung, and supply its parenchymatous structure, glands, &c. (Fig. 115.)

Œsophageal,[3] are from four to six in number, arising from the anterior convexity of the aorta, to be distributed to the œsophagus.

Intercostal.[21]—These are ten in number on each side, arising from the posterior convexity of the aorta.

They supply the ten inferior intercostal spaces, the right being somewhat longer than the left. They are received in the intercostal groove upon the under edge of each rib, for two-thirds of its length.

ABDOMINAL AORTA.

The Abdominal Aorta commences at the hiatus aorticus of the diaphragm and terminates at the junction of the fourth and fifth lumbar vertebræ, in the iliacs and middle sacral.

Fig. 122.

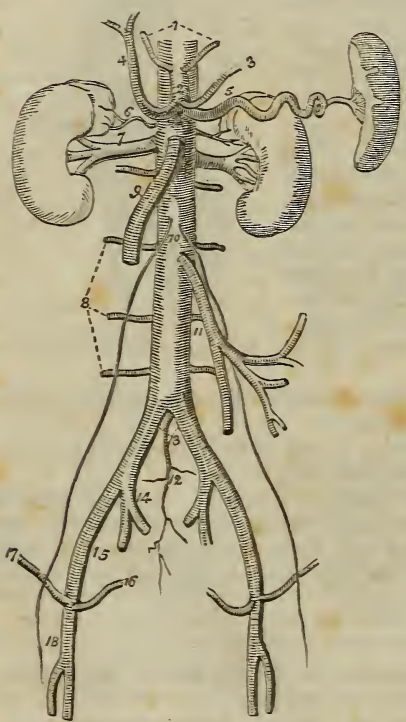

Phrenic.[1]—These are two in number, one for each side of the diaphragm, to which they are distributed; sometimes they arise by a common trunk from the cœliac.

Cœliac axis.[2]—A short, thick trunk about half an inch in length, given off opposite the junction of the last dorsal and first lumbar vertebræ; it divides into the gastric, hepatic, and splenic.

Gastric,[3] is the smallest branch of the cœliac, and supplies the lesser curvature of the stomach.

Hepatic,[4] enters the transverse fissure of the liver, and divides into two or three branches, before entering the substance of the liver. It gives off the *cystic*, which supplies the gall-bladder and the *right gastro-epiploic*, which supplies the right side of the greater curvature of the stomach.

Splenic.—This is the largest branch of the cœliac. It is very tortuous, and passes transversely to the spleen over the upper edge of the pancreas; from it are given off the *vasa brevia* and *left gastro-epiploic arteries*, supplying the left extremity and left side of the greater curvature.

Superior mesenteric,[9] arises immediately below the cœliac and is nearly as large. It passes beneath the pancreas and over the duodenum, and descending towards the right side it forms a curvature, the convexity of which is to the left. (Fig. 123.) From it are given sixteen or twenty large branches, which form an arch;[16] from this arch are given off secondary branches to form a second arch, and from this a third is formed. From this last arch the branches are derived which supply the small intestines. From the superior mesenterics are also given off three branches to the right side of the large intestine: *ileo-colica*[15] supplying the cæcum and a portion of the ileum; *colica dextra* supplying the ascending colon, and *colica media*[11] supplying the arch of the colon.

Fig. 123.

Capsular,[6] arise from the aorta or renal, and supply the supra-renal capsules. (Fig. 122.)

Renal or Emulgent.[17]—These are of large diameter, though not very long. They pass transversely to the kidney, and divide into several branches before entering it. The right is longer and more oblique in its course than the left, and is partly concealed by the ascending vena cava. (Fig. 122.)

Spermatic.[10]—These are about the size of a large knitting-needle, arising from the aorta and sometimes from the renal. They are tortuous in their course and pass through the abdominal rings; after which they divide into several branches before reaching the testicles.

In the female, they are distributed to the ovaries.

Fig. 124.

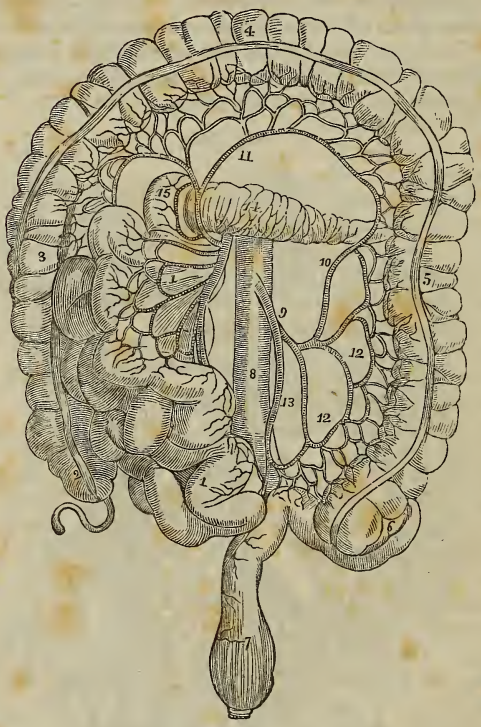

Inferior mesenteric,[11] arises from the aorta an inch above its bifurcation. (Fig. 124.) It is about the size of a goose-quill, and gives off the *superior left colic,*[11] *middle left colic,*[12] *and inferior left colic* arteries, which supply the descending colon, and also the *superior hemorrhoidal,*[13] which is distributed to the upper part of the rectum.

Lumbar.[8] (Fig. 122.) Arise on each side of the aorta, and are four or five in number; they correspond with the intercostals of the chest, and supply the muscles of the loins and abdomen.

Middle sacral.[12]—Is the termination of the aorta arising at its bifurcation into the iliacs. It descends along the median line of the sacrum.

COMMON ILIAC.

The aorta[1] divides into the *iliacs* at the lower part of the fourth lumbar vertebra. The iliac[2] descends obliquely outwards to the sacro-iliac articulation, being crossed by the ureter, and divides into the *external*[3] and *internal iliac.*[6]

Fig. 125.

INTERNAL ILIAC.

This is a short trunk,[6] descending in front of the sacro-iliac junction into the cavity of the pelvis, and giving off numerous branches with great irregularity and variety from its two principal trunks, the *gluteal*[8] and *ischiatic.*[7] (Fig. 125.)

Ilio-lumbar.[16]—Arises from the internal iliac or one of its principal trunks, ascends outwardly toward the crest of the ilium, and is spent upon the loins, anastomosing with the circumflex ilii.

Obturator.[17]—May arise at various parts of the internal iliac, and passing forwards below the brim of the pelvis, escapes from it at the upper part of the thyroid foramen; it is distributed by two branches upon the obturator and adductor muscles. Sometimes it arises from the epigastric.

Lateral sacral.[18]—This artery sends four branches through the anterior sacral foramina, anastomosing with the middle sacral.[20]

Gluteal.[19]—Is a continuation of the posterior trunk. It passes out of the pelvis at the upper part of the sacro-sciatic notch above the pyriformis muscle, and is distributed by two or three branches to the glutei muscles.

Vesical.[10]—Arises from the remains of the *umbilical*,[9] or from the internal iliac, and is spent upon the bladder. There is sometimes an inferior vesical.[15]

Middle hemorrhoidal.[13]—Is of variable size and origin. It is distributed to the rectum, vesiculæ seminales, and prostate gland.

Ischiatic.[14]—Is the anterior of the two principal trunks of the internal iliac. It passes out of the pelvis through the sciatic notch, between the pyriformis muscle and great sacro-sciatic ligament. It supplies the muscles on the floor of the pelvis and back of the thigh.

Internal pudic.[11]—Arises from the last, previous to its emergence from the pelvis. It also escapes from the pelvis, and returns between the sciatic ligaments; ascending upon the ramus of the ischium and pubes, it supplies the penis and perineum. (Fig. 126.)

Fig. 126.

Lower hemorrhoidal.[10]—Arises from the internal pudic,[9] and is distributed upon the anus and rectum. There are sometimes two arteries.

Transverse perineal.[11 12]—Arises near the crus of the penis, and runs across the transverse perineal muscles. It is cut in the lateral operation for stone.

Urethro-bulbar.[13]—Is given off from the pudic near its perforation of the triangular ligament, and enters the corpus spongiosum, which it supplies.

Dorsalis Penis.—Ascends until it gets under the arch of the pubes, and then runs along the back of the penis.

Cavernous.[14]—Another terminal branch which enters the corpus cavernosum.

EXTERNAL ILIAC.

This artery[3] extends (Fig. 125) from the sacro-iliac junction along the inner border of the psoas magnus muscle to the crural arch; when it passes under Poupart's ligament it becomes the *femoral*.[22]

Epigastric.[4]—Arises from the external iliac just behind Poupart's ligament, and ascends obliquely upwards and inwards, in the transversalis fascia, and between the two abdominal rings, whereby it is endangered in the operation for hernia. A branch of it supplies the cremaster muscle.

Circumflex ilii,[5] arises from the external iliac opposite the epigastric, and ascends obliquely until it reaches the crest of the ilium, where it divides and supplies the muscles of the loins and abdomen. The last two arteries anastomose freely with the internal mammary and lumbar arteries.

FEMORAL.

This artery commences at Poupart's ligament, being a continuation of the external iliac. It passes spirally down the inner side of the thigh, and perforating the tendon of the adductor magnus muscle, becomes the *popliteal*. Its upper third is superficial, and upon the outer side of the femoral vein. Its lower two-thirds are covered by the sartorius muscle.

Superficial artery of the abdomen,[2] arises from the femoral, just below Poupart's ligament, and ascends obliquely upon the integuments on the lower portion of the abdomen. It may be cut in the operation for inguinal hernia.

External pudics.[15] [16]—These are several branches, arising from the upper part of the femoral, and distributed to the integuments and glands of the groin.

Profunda,[17] is almost as large as the femoral, from which it arises at about two inches below Poupart's ligament. It passes downwards and backwards between the adductor brevis and vastus internus muscles.

External circumflex[18] is a branch of the profunda, and passes outwards between the rectus and cruræus, to supply the upper part of the muscles of the thigh.

Fig. 127.

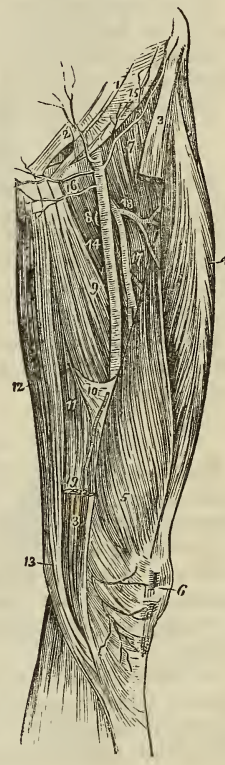

Internal circumflex[8] is larger than the external, and supplies the muscles upon the inner side of the thigh, and gives off a *perforating* artery. The *perforating* arteries are branches of the internal circumflex and profunda, which perforate the adductor magnus, and supply the muscles upon the back of the thigh.

Anastomotic,[19 6] arises from the femoral above its perforation of the adductor magnus tendon, and anastomoses with the articular arteries of the knee.

POPLITEAL.

This artery is a continuation of the femoral, and extends from the perforation in the adductor tendon, to its division into the anterior and posterior tibial below the knee. (Fig. 129.)

Superior articular.[9]—These are two in number, one internal and one external, given off above the condyles, anastomosing with each other and the anastomotic artery.

Inferior articular.—These are also external and internal, and supply the knee-joint below the head of the tibia.

Middle articular.—Is small, and perforates the ligament of Winslow, to supply the interior of the joint.

Gemellar.—These supply the heads of the gastrocnemius muscle.

POSTERIOR TIBIAL.

This artery[11 12] descends the back of the leg, under the muscles which form its calf, and nearer to the tibia than the fibula. (Fig. 128.)

Peroneal or *fibular*,[13 14] arises from the posterior tibial, and divides into several branches, which are distributed upon the muscles arising from the fibula.

As the posterior tibial approaches the ankle, it passes between the internal malleolus and the tendo Achillis into the sinuosity of the os calcis.

ANTERIOR TIBIAL.

This artery[10] (Fig. 129) perforates the interosseous membrane, at its upper part, and descends in front of it to the ankle. Its upper third[9] is situated between the tibialis anticus and extensor longus digitorum muscles; below, it runs between the tibialis anticus and extensor proprius pollicis. In its course it gives off numerous muscular branches, and when it reaches the ankle becomes more superficial, being covered by the tendons upon the instep.

Recurrent tibial,[10] ascends beneath the tibialis anticus, and anastomoses with the articular arteries of the knee-joint.

Internal malleolar.[11]—Arises from the anterior tibial above the ankle-joint, and is distributed upon its inner side.

External malleolar.[17]—Arises below the last, and is distributed upon the outside of the ankle.

Tarsal.[8]—Arises from the anterior tibial, and arches transversely across the tarsus, beneath the extensor brevis digitorum muscle.

Metatarsal.[11]—Arches across the bases of the metatarsal bones, and gives off three interosseal branches, which supply the toes.

Fig. 128.

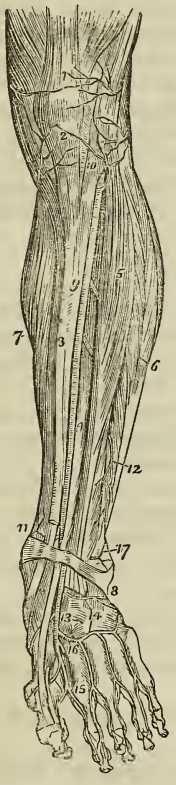

Fig. 129.

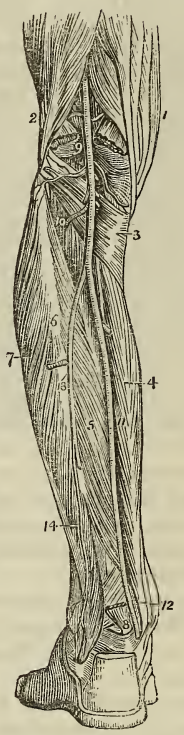

Dorsalis hallucis.[15]—Is the terminating branch of the anterior tibial, and supplies the outer side of the great toe and the inside of the second toe.

Pedal.[16]—This branch forms the communication between the anterior tibial and external plantar arteries. It descends to the sole of the foot, through the first interosseous muscle.

PLANTAR.

Fig. 130.

These arteries (Fig. 130) are two in number, and are branches of the posterior tibial,[2] which reaches the sole of the foot through the sinuosity of the os calcis.

External plantar.[7]—This is the larger of the two, and passing obliquely outwards upon the sole of the foot, it forms a deep arch[8] above the muscles of the foot. From it are given off digital arteries for the supply of the interosseous spaces, and which, bifurcating into the external and internal branches, supply the toes. The external plantar terminates in the pedal artery.

Internal plantar.[6]—This is a small artery, which passes along the inner border of the foot, and terminates in the digital artery of the great toe.

VEINS.

The veins return the blood to the heart. They are much more numerous than the arteries, and differ from them in having valves opening towards the heart.

These valves are formed of two or three crescentic folds of the lining membrane, and give the veins a knotty appearance when injected. They are more numerous in the superficial vessels.

The veins have three coats, but they are much thinner than those of the arteries; this deficiency, particularly in the middle elastic coat, gives them a flaccid appearance when empty, whereby they can be readily distinguished from arteries, which retain their cylindrical character.

The *superficial* veins are more tortuous and irregular than the deep. The *deep* accompany all the arteries, with the exception of those of the largest class. There are two veins for each artery, and they are called *venæ comites*, or *satellites*.

Sinuses are channels conveying venous blood, and lined by the internal coat of the veins.

The distribution and anastomoses of the veins are much more irregular than those of the arteries.

VEINS OF THE HEAD AND NECK.

The venous blood from the face is for the most part collected by veins accompanying the arteries, and which have the same name.

The principal trunks, viz., the *temporal*, *internal maxillary*, and

occipital, join to form a superficial vein of the neck, called *external jugular.*

Fig. 131.

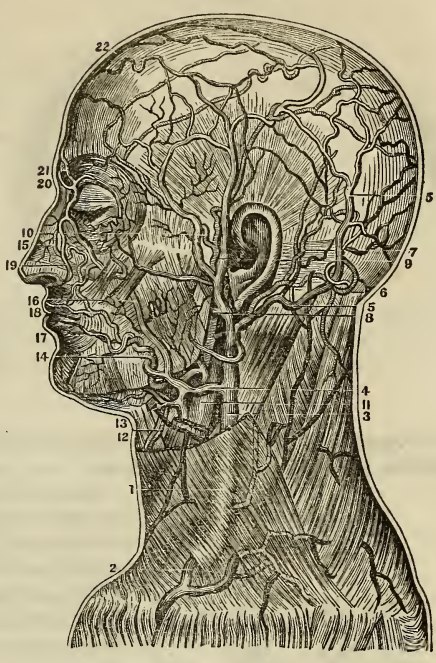

External jugular.[3] — Receives the blood from the temporal,[8] occipital,[5] and internal maxillary. It commences at the lower edge of the parotid gland, and descends the neck superficially, being merely covered by the skin, platysma myoides muscle, and superficial fascia. Its course is towards the middle of the clavicle. It crosses obliquely the sterno - cleido - mastoid muscle, and empties into the subclavian, outside of the origin of this muscle. It is frequently selected for bleeding in children.

Internal jugular.[11] — This vein is the largest of the neck. It receives the blood from the lateral sinus of the dura mater, and also from some superficial veins.

The facial vein[16] empties into the internal jugular, and also forms a communication[4] between it and the external jugular. The internal jugular descends the neck in a sheath with the carotid artery, being on the outer side. The par vagum nerve is in the same sheath and between the vessels. This vein empties into the subclavian on the inner side of the origin of the sterno-cleido-mastoid muscle. This junction forms the *vena innominata.*

SINUSES OF THE DURA MATER.

These are channels between the laminæ of the dura mater, which remove the blood from the brain. (Fig. 133.)

Superior longitudinal sinus.[1]—This is a triangular channel, commencing at the foramen cæcum by a small vein from the nose, and gradually increasing in size by the junction in an oblique manner, of the veins of the pia mater.[2] It forms an arch in the median line of the vault of the cranium, which terminates at the internal occipital cross in an enlargement called *Torcular Herophili.*[7]

Fig. 132.

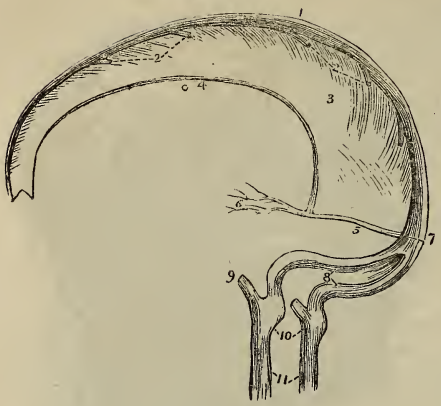

Inferior longitudinal sinus.[4]—This is situated in the inferior margin of the falx cerebri; it empties into the straight sinus at the interior edge of the tentorium.

Straight, or *Fourth sinus.*[5]—It reaches from the junction of the inferior longitudinal sinus to the torcular Herophili, in the median line of the tentorium, where it is joined by the falx cerebri.

Venæ Galeni.[6]—These veins are in the velum interpositum; they frequently unite into a trunk called *vena azygos*, before entering the straight sinus.

Fig. 133.

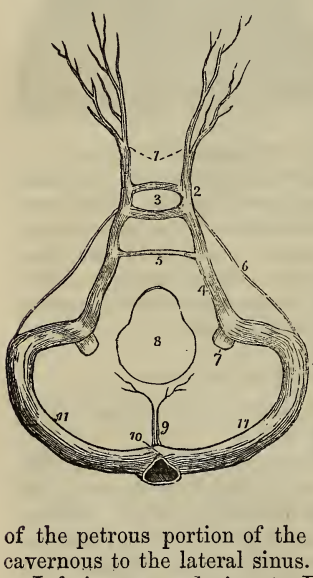

Lateral sinuses.[11] — These commence at the torcular Herophili, are oval-shaped channels, and pursue a curved course over the occipital, parietal, and temporal bones, until they reach the posterior foramen lacerum, where they emerge, and form the commencement of the internal jugular vein.[7] In their course they receive blood from several other sinuses. (Fig. 133.)

Cavernous sinuses,[2] are venous cells on either side of the *sella turcica*, containing a spongy structure; into them empty the ophthalmic veins,[1] and through them pass the internal carotid artery and the sixth nerve.

Circular sinus.[3]—It surrounds the pituitary gland in the *sella turcica*, and communicates upon each side with the cavernous sinus.

Superior petrosal sinus.[6]—This is a small sinus, running along the edge of the petrous portion of the temporal bone, and reaches from the cavernous to the lateral sinus.

Inferior petrosal sinus.[4]—Extends from the cavernous sinus on

each side, along the inferior margin of the petrous portion of the temporal bone, and opens into the lateral sinus near its exit from the cranium.

Anterior occipital sinus.[5]—It passes transversely across the basilar process of the occipital bone, connecting the two inferior petrosal sinuses.

Posterior occipital sinus.[6]—This is in the inferior edge of the falx cerebelli, descending from the torcular Herophili; when it reaches the foramen magnum, it bifurcates and empties into the lateral sinus upon each side. This communication is not represented in the diagram.

The venous blood from the channels in the diploic structure empties into the sinuses at the base of the cranium.

Emissaries of Santorini, are small veins passing through minute foramina of the bones of the cranium and forming a communication between the vessels of the scalp and the sinuses of the brain.

VEINS OF THE UPPER EXTREMITY.

The superficial veins of the upper extremity are readily seen beneath the skin; the *deep veins* have the usual arrangement of the *venæ comites.* The *superficial veins* are the following:

Cephalic.[2]—This originates upon the thumb by a branch called *cephalica pollicis*, and also upon the back of the hand; ascending upon the radial side[1] of the fore-arm, it is joined at the elbow by the *median* cephalic. It pursues its course along the outer side of the biceps, and entering a fissure between the *pectoralis major* and *deltoid* muscle, it empties into the subclavian vein under the clavicle. It sometimes communicates with the external jugular.

Fig. 134.

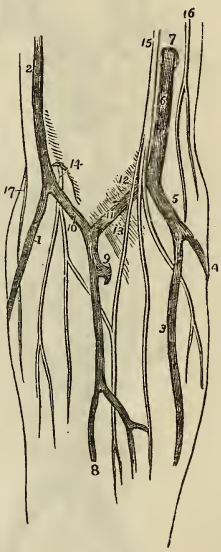

Basilic,[7] commences with the *vena salvatella* of the little finger, and receiving large branches[3 4] upon the ulnar side of the fore-arm, it is joined at the elbow by the median basilic. It then ascends the arm along the inner edge of the biceps muscle, and about its middle it joins the venæ comites to form the *axillary* vein.

Median.[8]—This collects the blood from the anterior face of the fore-arm, and near the elbow communicates[9] with the deep veins. It afterwards divides into the *median basilic*[11] and *median cephalic.*[10] The latter is the smaller of the two, and under it pass

branches of the external cutaneous nerve.[14] A branch of the internal cutaneous nerve[12 13] passes over the median basilic, and may be cut in bleeding.

Axillary.—It is formed by the junction of the basilic with the venæ comites of the brachial artery. It lies in front of the artery, and at the subclavius muscle terminates in the subclavian vein.

Subclavian.—This is a continuation of the axillary. It passes under the clavicle and over the first rib to join the internal jugular and form the vena innominata. It lies in front of the artery, and is separated from it while passing over the first rib by the scalenus anticus muscle.

SUPERIOR OR DESCENDING VENA CAVA.

The veins which form the descending cava[1] are the right and left venæ innominata.

Fig. 135.

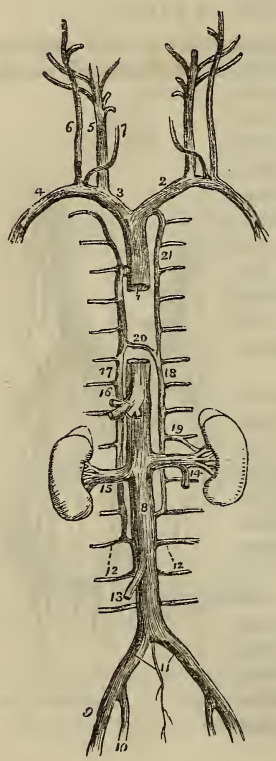

Right Innominata,[3] is about an inch and a quarter in length, and is formed by the junction of the internal jugular[5] and subclavian[4] veins. At this junction it receives the right thoracic duct. It descends superficially and obliquely in front of the arteria innominata to join its fellow.

Left Innominata.[2]—This is much longer than the right, and is formed in the same manner. It receives at its commencement the left thoracic duct. It passes horizontally across the chest in front of the large vessels arising from the arch of the aorta, and behind the first bone of the sternum. It is frequently called the *transverse vein.* With its fellow, it forms the *descending* vena cava.

The descending vena cava is about three inches in length, and descends perpendicularly to enter the upper part of the right auricle.

INFERIOR OR ASCENDING VENA CAVA.

This is formed by the junction of the iliac veins between the fourth and fifth lumbar vertebræ. It ascends[8] upon the vertebral column to the right of the aorta, and in its course receives the lumbar, right spermatic, renal, and he-

patic veins; it passes through the fissure of the liver between the right lobe and the lobulus Spigelii, and then enters the foramen quadratum of the diaphragm, to terminate at the right auricle of the heart.

Spermatic veins.—These originate in the vasa pampiniformia of the cord and testicle. The *right*[13] empties into the ascending cava, and the *left*[14] into the left renal.

Renal or Emulgent.—These are large, and return the blood from the kidney to the ascending cava. The right[15] is much shorter than the left. The left passes in front of the aorta.

Hepatic.[16]—These convey the venous blood from the liver by three large branches, which open at its posterior notch, into the ascending cava, as it passes through the fissure in the liver.

VENA AZYGOS.

This vein [17] commences in the lumbar regions, and being joined by the intercostal veins of the right side, it winds around the root of the right lung, and empties into the descending cava. It also receives the right bronchial and the right superior intercostal veins.

Vena hemiazygos.[18]—This is formed by the lower intercostal and superior lumbar veins, and passes in front[20] of the vertebral column to join the vena azygos.

Left superior intercostal.[21]—This receives the blood from the six superior intercostals, and the left bronchial vein; it forms a communication between the left subclavian and azygos veins.

The above veins form a communication between the venous blood of the upper and lower extremities, independent of its mingling in the heart. (Fig. 135.)

Fig. 136.

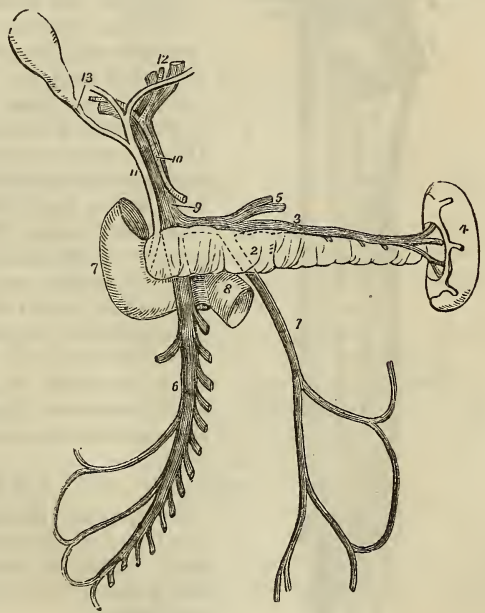

PORTAL VEIN.

This vein[9] collects the blood from all the chylopoietic viscera, and enter-

ing the transverse fissure of the liver, divides into the right and left sinuses. In its course it receives the inferior[4] and superior[6] mesenteric veins, splenic,[3] and gastric;[5] and then is included with the hepatic artery,[10] and the ductus communis choledochus[11] in the capsule of Glisson. The veins forming the portal vein have no valves.

Vesical plexus.—This plexus surrounds the neck of the bladder, seminal vesicles, prostate gland; its blood passes into the internal iliac vein.

Uterine plexus.—Surrounds the uterus and vagina, and empties as the vesical does.

Hæmorrhoidal veins.—Surround the rectum, and empty into the inferior mesenteric and internal iliac veins.

VEINS OF THE LOWER EXTREMITY.

The superficial veins of the lower extremity are two in number.

Fig. 137.

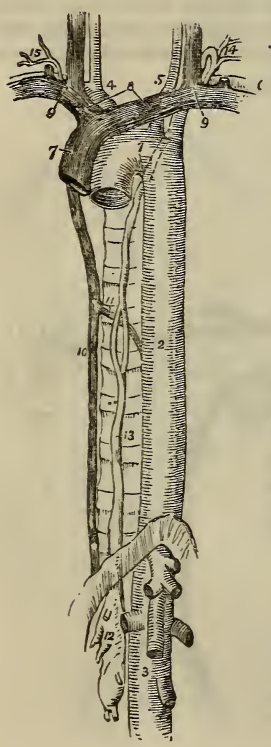

Internal saphena.—Commencing upon the inside of the foot and ankle it ascends upon the inside of the leg, and passing behind the internal condyle, it traverses the superficial fascia of the thigh and enters the femoral vein at the saphenous opening of the fascia lata.

External saphena.—Commencing upon the outer and posterior parts of the foot, it ascends upon the back of the leg and enters the popliteal vein above the knee.

Popliteal, is formed by the junction of the deep veins accompanying the anterior and posterior tibial arteries. It is superficial to the popliteal artery.

Femoral vein.—The femoral vein commences at the opening in the adductor magnus tendon, and ascends the thigh in company with the femoral artery. It passes under Poupart's ligament, to become the external iliac vein. It lies upon the inside of the femoral artery, as it passes over the pubes, and forms the outer boundary of the crural ring.

LYMPHATICS.

Lymphatics are small, pellucid vessels found in almost all portions of the body. They are exceedingly numerous, and found most constantly in company with veins.

They enter the lymphatic glands,

which are most numerous in the neck, groin, axilla, loins, and mesentery, and then emerge from them.

The lymphatics of the intestine, commence in the villi of the intestine; they are often called *lacteals*, and contain the chyle.

They have three coats, like arteries, and present a knotted appearance when distended, owing to the existence of sinuses and valves.

Left thoracic duct.[13]—This is the principal lymphatic vessel of the body; it receives the contents of the lymphatics or absorbents of the lower extremity, by an enlargement called *receptaculum chyli*[12] (Pecquet); and entering the thorax through the hiatus aorticus, it traverses the thorax through the posterior mediastinum in front of the vertebral column, and between the vena azygos[10] and aorta.[2] After reaching the fourth dorsal vertebra it ascends obliquely to the left side, and enters[14] the junction[9] of the left subclavian and the internal jugular veins.

Right thoracic duct.[15]—It is a short trunk, formed by the union of the lymphatics of the right side of the head and neck, and right upper extremity. It terminates at the junction of the right subclavian in the right internal jugular vein.

SECTION VI.

NERVOUS SYSTEM.

The principal *divisions* of the nervous system are the Brain, Spinal Marrow, and Nerves.

The *tissue* of this system is included in membranes or sheaths, and consists of two differently coloured pulpy materials; one of which is the *white* or *medullary*, and the other the *gray*, *cortical*, or *cineritious*.

The *white* or *medullary structure* is *fibrous;* in the centre of each fibre or tubule is a stripe called the *cylinder axis of Purkinje.*

The *gray* is more vascular, and is *vesicular* in its structure. These vesicles contain a nucleus with a nucleolus. They are soft, and of a yellow or brownish colour.

All ganglia and nervous centres consist of a mixture of white fibres and gray globules. (See "Physiology.")

The sheath of the nerves is called the *neurilemma*, and the internal material *neurine.*

An *anastomosis* is the interchange of fasciculi between two trunks; each fasciculus remaining unaltered by, although in contact with, another.

A *plexus* is a combination of anastomoses into a network.

Pacinian corpuscles are small elliptical bodies, found attached to the ulnar and digital nerves. They are of a dull white colour, or opalescent, and about two-thirds of a line in length.

MEMBRANES OF THE SPINAL MARROW.

Fig. 138.



Fig. 139.



The spinal marrow has three coverings. The *dura mater* is a white fibrous membrane, and is external. It is continuous with that of the brain, and, investing the spinal marrow loosely, terminates at its inferior extremity in a pointed cul-de-sac. It does not adhere closely to the bony canal, except at the intervertebral foramina, where it affords sheaths for the nerves. Between it and the walls of the bony canal is a quantity of loose cellular tissue infiltrated with fat and serum.

The *arachnoid* is the middle covering. This is a serous membrane, investing the spinal marrow, and lining the inner surface of the dura mater, to which it gives a smooth, polished appearance. It is extremely thin and transparent, and destitute of red blood-vessels.

The *pia mater* is the immediate covering. This is a cellular membrane, consisting almost entirely of vessels. It terminates in a round cord-like process, which reaches from the end of the spinal marrow to the bottom of the canal, and is concealed in the roots of the nerves which constitute the *cauda equina*.

SPINAL MARROW.

The spinal marrow is the medullary column included in the spinal canal of the vertebræ. It is cylindrical, and reaching from the atlas, terminates in a point at the first or second lumbar vertebra. It is flattened anteriorly and posteriorly, and has an enlargement in the neck and loins. It is divided longitudinally into symmetrical portions, by an anterior and a posterior fissure. The anterior[2] fissure is broad and shallow; the posterior[3] is deep and narrow. Each half is divided unequally by a lateral fissure; the anterior column being the larger.[1]

A transverse section of the spinal marrow exhibits the arrangement of its medullary and gray matter. The medullary matter is external, and the gray, in this section, resembles two crescents united by a commissure.

The posterior horns[4] of the crescent extend to the surface in the lateral fissure, in which originates the posterior[5] roots of the nerves.

From the sides of the spinal marrow proceed 30 pairs of nerves, each originating by two roots; the anterior from the anterior column, and the posterior from the lateral fissure, where they connect with the posterior horns. The posterior root is the larger, and upon it is a ganglion, which is in the invertebral foramen, beyond which the two roots unite. These two roots are separated by the *ligamentum denticulatum*, a pointed process of pia mater, which contains between its laminæ a good deal of yellow fibrous tissue.

Fig. 140.

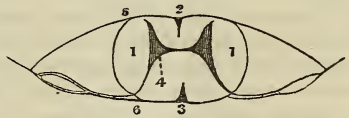

MEMBRANES OF THE BRAIN.

The brain has three membranes, of which the most external is the *dura mater*. It is of the same structure as the dura mater of the spinal cord, composed almost entirely of white fibrous tissue. It consists of two laminæ, which are only separate at the points where the *sinuses* exist.

It adheres firmly to the bones of the cranium, particularly to those at the base of the skull. The internal lamina forms several processes. The *falx cerebri* is a fold of the internal lamina, reaching in the median line from the crista galli to the tentorium, and separating the two hemispheres of the brain. The *tentorium* is another fold, stretched horizontally, and also of a crescentic shape, separating the cerebrum from the cerebellum. The *falx cerebelli* is a smaller fold, reaching from the internal occipital cross to the foramen magnum, and separating the lobes of the cerebellum.

The *arachnoid* is the serous membrane covering the brain, and

lining the inner surface of the dura mater. It is thin and transparent.

The *pia mater* is a vascular covering consisting of arteries and veins united by a small quantity of cellular tissue. It passes down in the fissures, between the convolutions, so as to invest them completely. The *Glands of Pacchioni* are usually small and white granulations, but sometimes are very large, especially in old persons. They are usually found along the margin of the longitudinal fissure, and sometimes produce absorption of the dura mater.

THE BRAIN.

The brain consists of four principal parts: Medulla Oblongata, Pons Varolii, Cerebrum, and Cerebellum.

MEDULLA OBLONGATA.

This is the upper part of the spinal cord; it is conical in its shape, and extends from the atlas to the pons Varolii. It is divided by the anterior and posterior fissures symmetrically, and each half consists of three different parts.

Corpus pyramidale.—This is a narrow, cylindrical portion, resembling a cord, and situated in front. It communicates freely with its fellow, by a decussation of their fibres, about one inch from the pons.

Corpus olivare.—This is an oval, convex mass, behind and above the corpus pyramidale, from which it is separated by a fissure. It is about half an inch in length. A section of it exhibits an arrangement of cineritious matter called *corpus fimbriatum.*

Corpus restiforme is the posterior division of each lateral column, and is separated from the corpus olivare by a groove. Between it and its fellow is a continuation of the posterior fissure called *calamus scriptorius,* across which pass transverse fibres of medullary matter, giving origin to the auditory nerve.

PONS VAROLII.

This is formed of medullary matter, and is cuboidal in shape. Externally, the fibres are transverse; internally, they are longitudinal, being a continuation of those of the medulla oblongata. It is situated in front of the medulla oblongata, and rests upon the basilar process of the occiput. From it proceed *four crura.*

CEREBRUM.

The cerebrum is an oval mass, weighing from three to four pounds, and divided into two hemispheres by the superior longitudinal fissure. Each hemisphere consists of an anterior, middle, and posterior lobe. The anterior and middle lobes are separated by the fissure of Sylvius. The division between the middle and posterior,

is an imaginary line in front of the anterior edge of the cerebellum. The surface presents a number of *gyri*, or convolutions, each separated by deep *sulci*, or fissures. The interior of each hemisphere is medullary, and the surface of each convolution is cineritious for the depth of one or two lines.

Island of Reil is a cluster of radiated convolutions in the fissure of Sylvius.

Crura Cerebri, are two thick, cylindrical white cords, which diverge from the anterior border of the pons, and their fibres terminate in the hemispheres of the brain. In a triangular space between them, is a layer of medullary matter called the *locus perforatus*.

Eminentiæ Mammillares, are two white, globular bodies, about the size of a pea, situated between the crura of the brain, and in front of the locus perforatus.

Tuber Cinereum, is a soft, gray mass, in front of the eminentiæ mammillares, and behind the chiasm of the optic nerves.

Infundibulum, is a hollow, conical body, of a reddish colour, with its base upon the *tuber cinereum*, and its apex attached to the *pituitary gland*.

Pituitary gland, is a vascular mass of a light colour, situated in the sella turcica. It consists of two lobes.

Corpus Callosum, is a white, arched band, seen at the bottom of the longitudinal fissure, forming a commissure between the two hemispheres. It is three inches and a half long, and about an inch broad. Its fibres are for the most part transverse, and consist of medullary matter, with the exception of a few, which pass longitudinally, and are called the *raphé*.

Septum Lucidum, is a vertical partition, consisting of two laminæ, and separating the lateral ventricles. Its upper edge is in contact with the *corpus callosum*, and its lower with the *fornix*.

Fornix.—It is a triangular, medullary arch, whose base is continuous with the *corpus callosum* posteriorly, and whose apex divides into two crura, which terminate in the *eminentia mammillares;* its under surface is termed *lyra*. Under these crura is the *foramen of Monro*, by which the third and two lateral ventricles communicate.

Velum Interpositum, is a triangular reflection of pia mater, immediately under the fornix; its edges contain a plexus of veins called *plexus choroides*.

Pineal Gland, is a small, reddish-gray, conical body, situated upon the *tubercula quadrigemina*, and connected by two crura with the optic tubercles.

Tubercula Quadrigemina are four prominences situated over the junction of the pons and crura cerebri. Under them is a passage called aqueduct of Sylvius, or *iter e tertio ad ventriculum quartum*.

Corpus Striatum, a gray mass of an oblong shape, situated in the lateral ventricle on either side. It is medullary within.

Thalamus Opticus, is an oval, convex mass, behind the corpus striatum on each side. It consists of a mixture of medullary and gray matter, and has three prominences called *corpora geniculata*, one on either side, and one in front. It is connected with its fellow by some cineritious substance, called the soft commissure.

Tænia Striata, is a thin edge of medullary matter, in the groove between the corpus striatum and thalamus opticus.

Hippocampus major, is a scroll extending into the inferior cornu of the lateral ventricle, the extremity of which resembles a foot, and is called the *pes hippocampi*.

Corpus Fimbriatum, or *Tænia Hippocampi*, is a thin edge of medullary matter upon the concave side of the hippocampus major; beneath which is a layer of cineritious matter, having a serrate appearance, and called the *fascia dentata*.

Hippocampus Minor, or *Ergot*, resembles a cock's spur; is a conical elevation pointing backwards into the *posterior cornu*.

Ventricles of the Brain.—These are five in number. They are called the *right* and *left lateral*, the *third*, *fourth*, and *fifth ventricles*.

Lateral ventricles exist in each hemisphere, and contain the *corpus striatum* and *thalamus opticus*. Each communicates with the third and its fellow by the foramen of Monro, being separated partially by the *septum lucidum;* the roof is formed by the corpus callosum. It contains three angular depressions called *cornua;* the anterior contains nothing; the posterior, the hippocampus minor; and the inferior, the hippocampus major.

The third ventricle is the space between the *thalami optici*. Its roof is formed by the velum interpositum and fornix, and its floor by the locus perforatus and the tuber cinereum. It is traversed in front by the anterior commissure, a medullary cord extending between the *corpora striata*, and by the posterior commissure, which extends transversely between the *thalami optici*. It communicates with the lateral ventricles by the foramen of Monro, and with the fourth by the aqueduct of Sylvius.

The fourth ventricle is situated between the pons Varolii, cerebellum, and medulla oblongata. Its floor is the calamus scriptorius, and its roof is the *valve of the brain*. Laterally, it is limited by the pia mater and the arachnoid. It communicates with the third.

The fifth ventricle is situated between the laminæ of the septum lucidum. It does not communicate with the other ventricles.

CEREBELLUM.

This constitutes about one-sixth of the brain, and is contained between the occiput and tentorium. It is oblong and flattened: its greatest diameter being transverse. It is composed of white and gray substances, the latter of which is external, and apparently arranged in laminæ. It is divided by a longitudinal fissure into two lobes; the superior part of which fissure contains a ridge called

vermis superior, in advance of which is an elevation called *monticulus*. In the inferior part of this fissure is a smaller ridge called the *vermis inferior*.

At the root of the crura cerebelli are two small protuberances; the one below it, in the erect position, is the *lobulus nervi pneumogastrici*, and the other the *lobulus amygdaloides*.

The valve of the brain is a thin *white lamina*, extending from the inferior surface of the cerebellum to the *corpora restiformia*.

Arbor vitæ, a section of either lobe of the cerebellum, presents an arborescent arrangement of the medullary matter.

Corpus Dentatum, or *Rhomboideum*, is a name applied to a gray mass with serrated edges, in the trunk of this medullary tree.

CRANIAL NERVES.

These are nine in number, and are so called from their emerging through the foramina, at the base of the cranium. They are designated by their function, as well as numerically. Their origin is as follows:

1st. *Olfactory.*—Arises by three roots, which coalesce in the fissure of Sylvius.

2d. *Optic.*—Arises from the thalamus opticus and the tubercula quadrigemina.

3d. *Motor Oculi.*—Arises from the crus cerebri.

4th. *Patheticus.*—Arises from the valve of the brain.

5th. *Trifacial.*—Arises from the superior and posterior part of the pons Varolii.

6th.—*Motor Externus.*—Arises from the corpus pyramidale.

7th. *Facial and Auditory.*—The facial or *portio dura* arises in a groove between the corpus olivare and corpus restiforme near the pons Varolii. The auditory or *portio mollis* arises from transverse striæ upon the calamus scriptorius. The *portio intermedia* of the 7th arises in the corpus restiforme, and may be considered as the posterior or sensitive root to the facial.

8th. *Pneumogastric, glosso-pharyngeal, and spinal accessory.*—The first two arise by filaments from the fissure between the corpus olivare and the corpus restiforme; and the last arises from the spinal cord by a series of slender roots, as low down as the fourth or fifth cervical vertebra.

9th. *Hypoglossal.*—Arises in the fissure between the corpus pyramidale and corpus olivare.

The cranial nerves may be divided into three classes, according to their function, viz.:—*Nerves of special sense*, including the 1st, 2d, and the auditory branch of the 7th. *Nerves of motion*, including the 3d, 4th, 6th, facial branch of the 7th and 9th. *Compound nerves*, comprising the 8th and 5th.

The distribution of the cranial nerves—

1st. *Olfactory.*—It has a large, soft bulb, which rests on the cribriform plate of the ethmoid bone, and sends filaments through its foramina to the Schneiderian membrane.

2d. *Optic.*—Forms a chiasm with its fellow, and enters the globe of the eye through the foramen opticum, to join the retina. It is a flattened cord.

3d. *Motor Oculi.*[3]—Passes through the external wall of the cavernous sinus to escape at the sphenoidal foramen, and then is distributed upon the muscles of the eyeball, with the exception of the superior oblique and external rectus. It sends a *branch* to join the ophthalmic ganglion, from which proceed the ciliary nerves,[8] which supply the iris.

Fig. 141.

4th. *Pathetic.* — Passing through the external wall of the cavernous sinus, and through the sphenoidal foramen, it is distributed upon the superior oblique muscle of the eyeball. It is the smallest cranial nerve.

5th. *Trifacial.*—The trifacial or trigeminus is the largest of the cranial nerves, and has a fibrous appearance. It resembles the spinal nerves in arising by two roots, which can be traced into the anterior and posterior columns of the spinal marrow, and also in having a ganglion upon its posterior and larger root.

This ganglion is called Casserian, and rests upon the depression upon the anterior portion of the petrous portion of the temporal bone. From it proceed three large branches, called ophthalmic, superior maxillary, and inferior maxillary nerves. The first and second branches confer sensibility on the structures on which they ramify; but the third receives the motor filaments of the anterior root, and, therefore, confers motion as well as sensibility to the structures upon which it is distributed.

The *ophthalmic*[6] passes out through the sphenoidal foramen into the orbit by three branches, the nasal, frontal, and lachrymal. The *nasal*[11] gives off the *internal nasal,* which enters the cranium at the anterior ethmoidal foramen, and then goes through the cribriform plate into the nose; and also a branch (*ramus ciliaris*) to the lenticular or ophthalmic ganglion. It is distributed

to the muscles of the orbit, eyelids, and conjunctiva. The *frontal*[9] divides into two branches, and is spent upon the integuments and muscles of the forehead; one branch goes through the supra-orbitary foramen. The *lachrymal*[10] branch supplies the lachrymal gland, and the contiguous portions of the orbit.

Fig. 142.

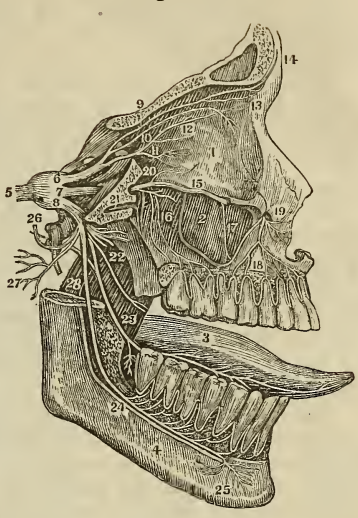

The *superior maxillary*[7] passes through the foramen rotundum, and then enters the pterygo-maxillary fossa.[20] A large branch called *infra orbital*[18] traverses the infra-orbital canal, and emerges at the infra-orbital foramen[19] to supply the face; giving off the *dental nerves*[16 17] in its course. The *pterygo-palatine branch*, or branches, join the *ganglion of Meckel* in the pterygo-maxillary fossa, from which proceed the spheno-palatine branches, which enter the nose through the spheno-palatine foramen; one of these branches is long, and called naso-palatine, which joins its fellow at the ganglion of Cloquet in the *foramen incisivum;* the posterior palatine descends from the ganglion through the posterior palatine foramen, and is distributed to the palate and fauces; the *vidian*, or *pterygoid*, or *recurrent*,[21] passes backwards from the ganglion through the pterygoid foramen, and divides into two branches, called *superficial* and *deep petrous*. The superficial petrous enters the *hiatus Fallopii*, and passing between the smaller bones of the ear, emerges at the Glaserian fissure under the name of *chorda tympani*, which joins the submaxillary ganglion. The deep petrous enters the carotid canal, and joins the ganglion of *Laumonier*, which was formerly considered the origin of the sympathetic nerve.

The *inferior maxillary*,[8] is the largest branch of the 5th pair. It is composed of filaments from the Casserian ganglion, and of the anterior or motor root of the tri-geminus. It emerges from the cranium through the foramen ovale, and soon divides into two principal trunks which are separated from each other by the external pterygoid muscle. The *external* trunk is composed mostly of the motor filaments, and splits into five branches, which are distributed to the masseter, buccal, pterygoid, and temporal muscles. One

of the temporal branches perforates the temporal fascia and communicates with the auricular and facial nerves. The internal trunk gives off three branches, viz., the gustatory, superficial temporal, and inferior dental.

The *gustatory*, passes between the pterygoid muscles, and then curves forward above the sublingual gland and beneath the mylo-hyoid muscle and parallel to the stylo-glossus muscle.—It accompanies the Whartonian duct, and is distributed to the papilla and mucous membrane upon the sides and tip of the tongue.

The chorda tympani nerve joins it near the condyle of the lower jaw, and parts from it near the angle, to join the submaxillary ganglion, whose branches pass in the submaxillary gland.

The *superficial temporal*, or auriculo-temporal, often commences by two roots, between which passes the meningea magna artery. From it proceed several branches, to the parotid gland, to the joint, to the external ear, and to the side of the head, in company with the branches of the temporal artery.

The *inferior dental* descends between the pterygoid muscles, and enters the posterior mental foramen after having given off the *mylo-hyoidean* branch to the muscle of the same name. It then runs along the canal in the lower jaw, supplying the teeth, and then sends a branch through the anterior mental foramen, which is distributed upon the chin.

Fig. 143.

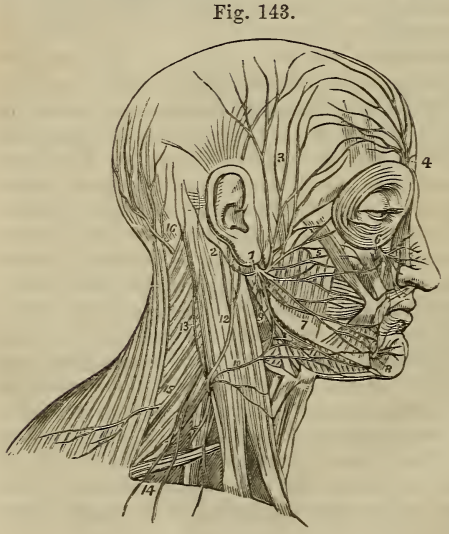

The *otic ganglion*, a small, reddish-gray body, is situated upon the inferior maxillary nerve, near its emergence from the foramen ovale.

6th. *Motor Externus.*—Passing through the cavernous sinus, it escapes from the cranium through the sphenoidal foramen or fissure, and is distributed to the external rectus muscle of the eyeball. Its paralysis will produce an internal squint. A branch enters the carotid canal to join the ganglion of Laumonier.

7th. *Facial and auditory.*—Both branches enter into the internal meatus; the auditory is also called *portio mollis,* and is distributed to the internal ear. The facial, also called *portio dura,* passes through the aqueduct of Fallopius, where it is formed by the superficial petrous, and emerges from the temporal bone at the stylo-mastoid foramen.[1] (Fig. 143.)

Before it enters the parotid gland, it gives off the posterior auricular, digastric, and stylo-hyoid branches. As it passes through the gland a plexus is formed, called the pes anserinus, from which proceed two principal branches, viz., the temporo-facial and cervico-facial. The temporo-facial is distributed by temporal, buccal, and malar branches, to muscles of the face; the cervico-facial is distributed by branches to the muscles upon the lower jaw and neck, which communicate with the cervical nerves.

Fig. 144.

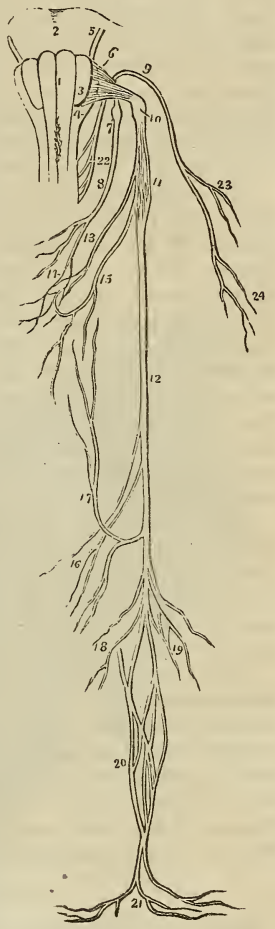

The 8th consists of three branches, the glosso-pharyngeal, the pneumo-gastric, and the spinal accessory, all of which emerge from the cranium at the posterior foramen lacerum or jugular foramen. (Fig. 144.)

The *glosso-pharyngeal* is the highest branch of this pair. It passes out of the cranium by a distinct fibrous canal in the foramen, and descends between the internal jugular vein and the carotid artery in curved line, adhering to the stylo-pharyngeus muscle. It is inferior to, and deeper in the neck than the gustatory nerve. Upon it are two ganglions—one is in the jugular foramen, and involves only a part of the nerve; and the other is the petrous or Anderschian ganglion.[7] From it arises numerous branches, which communicate with the facial, the sympathetic, and the pneumo-gastric, and also the filament called Jacobson's nerve. This nerve enters the tympanum through a small opening between the jugular and carotid foramina, to form the *plexus* upon the inner wall of the tympanum, in which the 5th pair and the sympathetic communicate.

From the glosso-pharyngeal are given off branches, which with others from the sympathetic and pneumogastric form the *pharyngeal* plexus.[14] It supplies the papillæ at the posterior part of the tongue and the mucous membrane of the pharynx, and also some of the muscles of the tongue and pharynx.

The *pneumogastric* having escaped from the cranium by the posterior foramen lacerum, or jugular foramen, presents a ganglionic enlargement[11] called plexus gangliformis. A small ganglion[10] is also found upon that portion which passes through the foramen. It then descends within the sheath of the vessels of the neck, lying behind and between the artery and vein, and entering the thorax and abdomen, supplies the lungs and stomach, giving off the following branches: the *superior pharyngeal*,[13] which assists in forming the pharyngeal plexus,[14] assisted by branches from the glosso-pharyngeal, the superior laryngeal, and sympathetic. This plexus is distributed to the muscles and mucous membrane of the pharynx.

The *superior laryngeal*[15] arises from the ganglionic plexus, enters the larynx, and is distributed to its mucous membrane. The *cardiac* branches[16] are two or three in number, and descend to join the cardiac plexus. The *inferior laryngeal*,[17] or *recurrent laryngeal*, curves around the aorta upon the left side, and the subclavian upon the right; ascending between the trachea and the œsophagus, it is distributed to the muscles of the larynx, communicating with the superior laryngeal and the sympathetic nerve. *Anterior* and *posterior*[18 19] *pulmonary* branches are given off in the thorax to form the pulmonary plexus. The *œsophageal branches*[20] surround the œsophagus, and with it enter the abdomen through the diaphragm, there to be spent upon the stomach and neighbouring viscera, and also communicate with the solar plexus.

Spinal accessory.—This branch[9] of the eighth pair escapes also at the jugular foramen, and divides into two branches, one of which gives filaments to the superior pharyngeal nerve; the other, which is the larger, descends obliquely backwards, and piercing the sterno-mastoid muscle, is distributed to the trapezius, after having communicated with the upper cervical nerves.[23 24]

9th. The *Hypoglossal nerve* emerges from the cranium through the anterior condyloid foramen; it then passes between the internal carotid artery and internal jugular vein, and curving around the occipital artery, sends branches to the muscles of the tongue. A branch, *descendens noni*, descends as a long, thin filament, in front of the sheath of the vessels, and below the middle of the neck; forming a loop with a branch from the second and third cervical nerves. It communicates with the pneumogastric and sympathetic.

SPINAL NERVES.

There are thirty pairs of spinal nerves, each arising by two roots. After the union of the anterior or motor root with the posterior

or sensitive root in the intervertebral foramen, the spinal nerves divide into two trunks, the *posterior* of which are much the smaller, and supply the muscles of the back; the *anterior* are large, and communicating with the ganglions of the sympathetic nerve, form plexuses which give off the principal nerves to the muscles of the trunk and extremities.

CERVICAL NERVES.

These are eight in number: the first is called the *sub-occipital;* it passes out of the spinal canal between the occiput and atlas, in a groove beneath the vertebral artery. It supplies the recti muscles, and unites with the first cervical so as to form a loop around the transverse process of the atlas. (Fig. 143.)

Three superior cervical nerves anastomose freely and form a *cervical plexus*, which sends numerous branches to the muscles and skin of the neck, forming communications with the ninth and facial nerves. The principal branches from this plexus are the superficial,[10 12 16] the great auricular,[12] the occipital,[16] and the supra-clavicular. The *phrenic* nerve[16] (Fig. 145), is formed by filaments from the second and third cervical nerves, and passing over the scalenus anticus muscle, and through the anterior mediastinum, adheres to the pericardium. It is distributed to the diaphragm by several branches. The right passes in front of the innominata, the left passes in front of the aorta, and is more deeply situated than the right in the thorax.

Fig. 145.

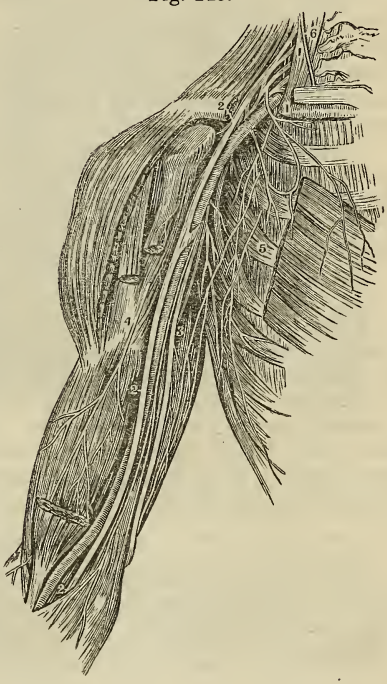

The *four inferior cervical* nerves, together with the first dorsal, emerging from the spinal canal between the scalenus anticus and medius muscles, form a large plexus, by their anterior branches, which is plaited around the subclavian and axillary arteries.

The *brachial plexus* gives off the following branches: the *supra-scapular* branch, which ascends upon the shoulder and supplies its muscles; passing through the coracoid notch.

The *Posterior* or *long thoracic branch* is distributed to the serratus anticus muscle. (External respiratory nerve of Bell.)

The *sub-scapular* branches are two in number, and supply the sub-scapular muscle.

The *anterior* or *short thoracic* are two in number, and supply the pectoral muscles.

The lesser internal cutaneous, or nerve of Wrisberg, is distributed to the skin of the upper and posterior part of the arm. It is frequently joined by the first intercosto-humeral nerve.

The *circumflex* or *axillary* nerve winds round the head of the humerus, in company with the posterior circumflex artery, and is distributed to the deltoid muscle. The *internal cutaneous* is a very small, thin filament passing down the inside of the arm, and sends branches across the superficial veins at the elbow, then is distributed to the skin, fascia, and fore-arm. The *external* or *musculo-cutaneous*[4] perforates the coraco-brachialis, and is also distributed to the muscles in front of the arm and integument of the fore-arm.

The *ulnar*,[3] descending the arm, passes superficially under the internal condyle, and is finally distributed to the little finger, and the ulnar side of the ring finger.

The *radial* or *musculo-spiral* is the largest of these nerves which come from the brachial plexus; it winds around the humerus, between the head of the triceps muscle, which it supplies with branches, and then descends the fore-arm supplying its muscles; a large branch accompanies the radial artery, supplying the wrist and thumb.

The *median*[2] descends the arm in close company with the brachial artery, until it reaches the elbow; it there passes between the two heads of the pronator teres muscle, and descending the fore-arm, between the flexor sublimis and profundus muscles, it is distributed to the fingers, with the exception of those supplied by the ulnar.

DORSAL NERVES.

These are twelve in number; the anterior branches are the larger, and are received into the intercostal grooves, in which they run, to be distributed to the muscles of the chest.

The *first dorsal nerve* joins the brachial plexus. The *intercosto-humeral nerves*[5] are two in number; they proceed from the second and third dorsal nerves, and perforate the second and third intercostal spaces, to be distributed upon the skin of the arm; the first frequently joins the nerve of Wrisberg.

LUMBAR NERVES.

These are five in number; the anterior branches of the four superior descending form the *lumbar plexus*, which is situated behind the psoas magnus muscle; it is frequently connected with the last dorsal nerve.

The *abdomino-crural*[3] branches are two or three in number, and pass obliquely over the quadratus lumborum muscle, and supply the muscles of the abdomen and the skin of the groin and genitals.

The *external cutaneous*[4] crosses obliquely the iliacus internus muscle, towards the anterior superior spinous process. It perforates the fascia lata, and is distributed to the integument of the thigh.

The *external spermatic*[9] or genito-crural perforates the psoas muscle, and descending to the groin, supplies the cremaster muscle and skin of the thigh.

The *anterior crural*[8] is the largest branch of the lumbar plexus. It emerges from under the psoas magnus muscle and passes under Poupart's ligament. It gives off the *anterior, middle,* and *internal cutaneous* branches,[5 6 7] which are distributed to the integuments; the *long*, or *internal*, or long *saphenous* nerve, accompanies the femoral artery as far as its perforation of the adductor tendon, and then accompanies the saphena vein to the foot.

Fig. 146.

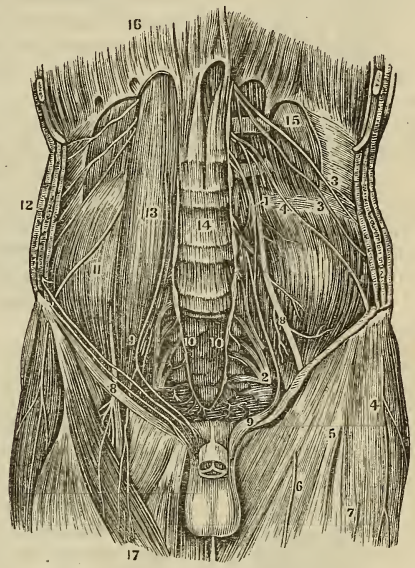

The *obturator* accompanies the obturator artery, and emerges from the pelvis at the upper portion of the thyroid foramen. It is distributed upon the obturator and adductor muscles.

SACRAL NERVES.

These are five and sometimes six in number; the anterior trunks of the four upper, with a portion of the last dorsal, constitute the *sacral plexus.* The fifth and sixth are distributed to the gluteus maximus muscle, and to the skin. The sacral plexus is triangular in its shape, and situated upon the pyriformis muscle. From it are derived a few small branches sent to the muscles and viscera of the pelvis, and also the following nerves to the lower extremity.

The *gluteal,*[1] which, emerging from the sacro-sciatic notch, divides into two large branches to supply the glutei muscles. (Fig. 147.)

The *pudic,*[2] or *superior long pudendal,* accompanies the internal pudic artery, and supplies the perineum, and organs of generation;

Fig. 147.

it divides into two branches, the *superior* continuing to the extremity of the penis with the dorsal artery.

The *lesser ischiatic*[3] escapes from the pelvis between the pyriformis muscle and the great sacro-sciatic ligament, and divides into the *inferior long pudendal* or *perineal*,[5] which winds around the tuberosity of the ischium, and is distributed to the integuments of the perineum; and the *posterior cutaneous*,[6] a long filament passing down the back of the thigh and leg, to be spent upon the integuments.

The *great sciatic*[7] is the largest nerve in the body; it escapes from the pelvis beneath the pyriformis muscle, and descends the back of the thigh between the flexor muscles; about one-third above the knee, it divides into two large branches, called *peroneal* and *popliteal*.

The *popiteal*[8] descends through the popliteal space, giving off numerous muscular and cutaneous branches, one of which is the *external* or short *saphenous nerve*,[10] is joined by the internal peroneo-cutaneous nerve,[11] and becomes superficial near the ankle; it then passes behind the external malleolus, and supplies the skin, external malleolus, and the foot.

The *posterior tibial*[9] is a continuation of the popliteal, descending the back of the leg in company with the posterior tibial artery; it is finally distributed upon the sole of the foot by two branches called the *external* and *internal plantar* nerves.

The *internal plantar* is the larger, and is distributed to the first, second, and third toes, and to the inner side of the fourth.

The *external plantar* is distributed to the little toe, and the outer side of the next toe.

The plantar nerves are distributed to the toes upon the same plan as the median and ulnar nerves are to the fingers.

The *peroneal nerve* extends towards the head of the fibula, passing between the external side of the tendon of the biceps and the outer part of the external head of the gastrocnemius. It gives off the following

cutaneous branches, and then divides into the external peroneal and anterior tibial. The *internal peroneo-cutaneous* is the largest cutaneous branch; it joins with the external saphenous or *communicans tibiæ*.

The external peroneo-cutaneous is distributed to the skin along the fibula.

The *external peroneal* passes down upon the fibular side of the leg, through the peroneus longus muscle, and becoming superficial in the lower third of the leg, perforates the crural fascia, and is distributed to the integuments of the foot and ankle.

The *anterior tibial* descends in front of the interosseous ligament, in company with the anterior tibial artery, and is distributed to the muscles of the leg, and to the muscles and skin upon the foot.

SYMPATHETIC NERVE.

The sympathetic system consists of two chains of ganglia, united to each other and to the cranial and spinal nerves. Each ganglion may be considered as a distinct nervous centre, and is placed opposite the intervertebral space. The two sides of the sympathetic system are united in the head by the ganglion of Ribes, which may be considered as the origin of the sympathetic nerve. There is also a ganglion in the median line of the coccyx, whereby the two lateral halves of the sympathetic are united below.

It is distributed in connexion with all the other nerves of the body, and by means of plexuses supplies all the internal organs; these plexuses take the name of the artery with which they are connected, or of the organ to which they are distributed.

Fig. 148.

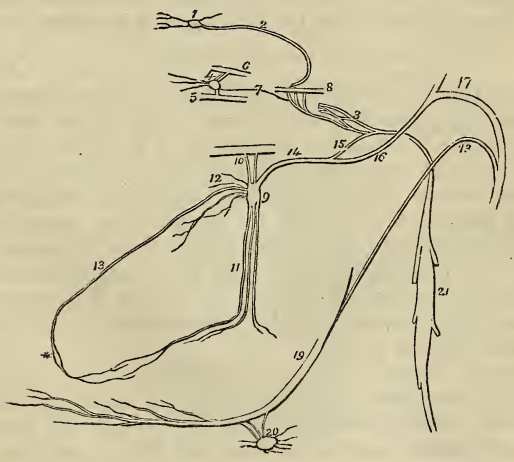

The *cranial* ganglia of the sympathetic are five in number, viz.: *ganglion of Ribes,*[1] which is small, and situated upon the anterior communicating artery; a filament of it[2] joins the sixth nerve,[3] which communicates with the carotid plexus.[3] The *carotid plexus* surrounds the carotid artery in the carotid canal, and frequently contains a ganglion called after *Laumonier.* This plexus is joined by the *deep petrous* branch of the vidian nerve, and was formerly considered the origin of the sympathetic.

The *lenticular* ganglion[4] is small and flattened, reposing between the optic nerve and the external rectus muscle. This ganglion communicates with a branch of the nasal nerve,[6] and a branch of the third, called ciliary[5]; a small filament[7] passes from this ganglion to join the carotid plexus.

The *spheno-palatine* ganglion is called also *Meckel's* ganglion.[9] From this are given off the vidian nerve,[14] the deep petrous branch of which joins the carotid plexus, as has been mentioned, and the superficial petrous,[16] which enters the hiatus Fallopii, and emerging at the Glaserian fissure as the chorda tympani,[12] descends in connexion with the gustatory nerve[19] to join the *submaxillary ganglion.*

The *ganglion of Meckel* communicates with the superior maxillary nerve by means of its two ascending branches, called *pterygo-palatine.*[10] One of its spheno-palatine branches,[12] called naso-palatine,[13] joins its fellow in the foramen incisivum, to form the ganglion of Cloquet,* or naso-palatine ganglion. Its descending branches[11] supply the palate, gums, and fauces.

The *otic* ganglion (Arnold's), is a small oval ganglion, adhering to the inner surface of the inferior maxillary nerve, below the foramen ovale; it sends branches of communication to the superior and inferior maxillary, to the vidian and tympanic nerves, and it also supplies the tensor tympani and the tensor palati muscles.

CERVICAL GANGLIA.

These are three in number. The *first*[1] is a long, gray, spindle-shaped ganglion, extending to the lower border of the third cervical vertebra, behind the sheath of the vessels of the neck. Its branches are numerous, and some are very soft, hence termed *nervi molles.* They communicate with the anterior trunks[4] of the first, second, and third cervical nerves; and by an ascending branch[2] with the carotid plexus, and by a descending branch[3] with the second cervical ganglion. Its internal branches[5] join the facial, eighth, and ninth nerves, and the pharyngeal plexus. A number of branches join to form the *superior* cardiac nerve,[6] which descends behind the vessels and joins the cardiac plexus.

The *middle cervical* ganglion is usually small, and sometimes wanting. It rests upon the inferior thyroid artery in front of the fifth or sixth cervical vertebra. It is often called the *thyroid* ganglion. Its branches join the superior and inferior cervlica ganglia,

and the anterior trunks of the third, fourth, and fifth cervical nerves; it also sends the *middle cardiac nerve*[7] to join the cardiac plexus.

The *inferior cervical ganglion* is larger than the last, and is situated in front of the root of the transverse process of the seventh cervical vertebra. Its filaments join the sixth, seventh, and eighth cervical nerves, and also form the *inferior cardiac* nerve, which joins the middle cardiac nerve and the cardiac plexus.

The *cardiac plexus* is situated behind the arch of the aorta, upon the bifurcation of the trachea. Its branches, in conjunction with the par vagum and descendens noni, form the anterior and posterior cardiac plexuses; from these plexuses are derived the filaments which supply the heart.

THORACIC GANGLIA.

These are twelve in number, situated at the intervertebral spaces. They are small and connected with each other as well as with the anterior trunks of the spinal nerves. The great *splanchnic*[3] is formed by filaments from the sixth to the tenth ganglion; it descends in the posterior mediastinum, and pierces the diaphragm at or near the foramen aorticum, to form the semilunar ganglion. The *lesser splanchnic nerve*[14] is formed by filaments from the tenth and eleventh ganglia; it pierces the diaphragm and joins the semilunar ganglion and the renal plexus.

The *semilunar ganglion*[13] consists of a number of smaller ganglia formed upon filaments of the splanchnic nerve after it has entered the abdomen; they are arranged in a crescentic manner,[13] and situated upon the aorta and cœliac axis.

The *solar plexus* is a network on the sides of the aorta, and extends as far as the renal arteries. It is a number of filaments connecting the portions of the semilunar ganglia; and from it proceed smaller plexuses, which accompany the large arterial trunks; thus, the *hepatic plexus* is the network which surrounds the hepatic artery, and is distributed to the liver, gall-bladder, &c. The *splenic plexus* accompanies the splenic artery and supplies the spleen; thus also, are distributed, the renal, mesenteric, and other plexuses.

Fig. 149.

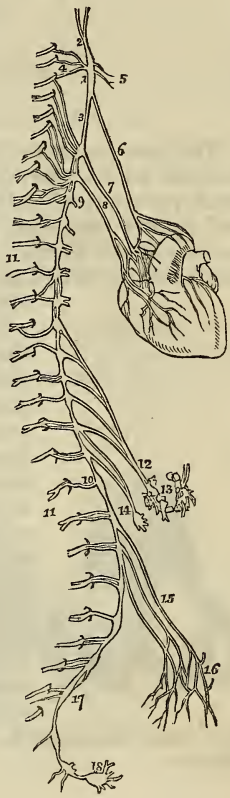

LUMBAR AND SACRAL GANGLIA.

The *lumbar ganglia* are four or five in number, which are united with each other and the spinal nerves. They form a plexus upon the aorta, which receives filaments from the solar and hypogastric plexuses.

The *hypogastric plexus*[16] is formed by branches of the lumbar[15] and aortic plexuses and filaments from the *sacral ganglia*. From it are supplied all the viscera of the pelvis. The sacral ganglia are three or four in number. The last is called *impar*[13] or *azygos*, being situated in the median line of the coccyx, and constituting the *terminating ganglion* of the sympathetic.

SECTION VII.

ORGANS OF SENSE.

NOSE.

THE nose consists of two portions, an external projection upon the face, and an internal cavity. The *external* portion is formed by the nasal processes of the superior maxillary bones, the nasal bones, and by five cartilages, two of which are placed upon either side and one in the middle. The *cartilaginous septum* is placed in the median line;[2] it is thick, flat, and triangular, uniting by its superior edge with the ethmoid, and by its inferior edge with the vomer. Its anterior edge unites with the *lateral* and *alar* cartilages. It frequently deviates from the median line. The *lateral* cartilages[3] are triangular, one being placed on either side, attached above and behind to the bone, in front with the septum, and below with the alar cartilage. The *alar* cartilages[4] are two in number; they form the lower portion of the nose, and the opening called the nostril. It is an irregular, semi-elliptical cartilage, and has a number of small pieces of cartilage attached to it, by which the nostril is kept open. These cartilages are held together by a fibrous tissue. The skin which covers the nose is thick and strong, and covered with numerous sebaceous follicles, which are frequently recognised by their being discoloured. The hairs visible in the nostril are termed *vibrissæ*.

Fig. 150.

The *cavity* of the nose is formed by the nasal fossæ. The roof is the cribriform plate of the ethmoid, the floor is the hard palate. Upon each side there are three scrolls formed by the turbinate bones. Between the superior and middle turbinate bones is the *superior meatus;* between the middle and inferior turbinate bones is the *middle meatus;* between the inferior turbinate bone and the floor of the nose is the *inferior meatus.* It is lined by a mucous membrane called *pituitary,* or *Schneiderian,* which is thick, soft, and red, owing to its vascularity, and largely supplied with nerves, being the seat of smell. It lines the meatuses of the nose, and is continuous with the mucous membrane of the mouth, lachrymal canal, Eustachian tube, frontal sinus, and ethmoidal cells. It is supplied by the first and fifth pairs of nerves.

THE EYE AND ITS APPENDAGES.

The *eyeball* is a sphere, of about one inch in diameter, antero-posteriorly, and somewhat less transversely. It is surrounded by a fibrous capsule, which is continuous with the sheath of the optic nerve behind, and the cartilages of the eyelids in front. All the muscles of the ball of the eye lie behind this capsule or fascia, and perforate it, in order to be inserted into the sclerotic coat.

The *sclerotic coat*[1] is a dense, fibrous, white membrane, thinner in front, where it receives the cornea, than it is behind, where it is perforated by the optic nerve. The circular edge in contact with the cornea is bevelled. The external surface is anteriorly covered by the *conjunctiva,* and posteriorly by fat. Its internal surface is connected with the choroid coat. It is perforated by numerous small foramina transmitting arteries and nerves.

The *cornea*[2] fills up the opening in the anterior part of the sclerotica, and forms about one-sixth of the whole eyeball; it is more convex than the sclerotica, and therefore forms a projection in front.

Fig. 151.

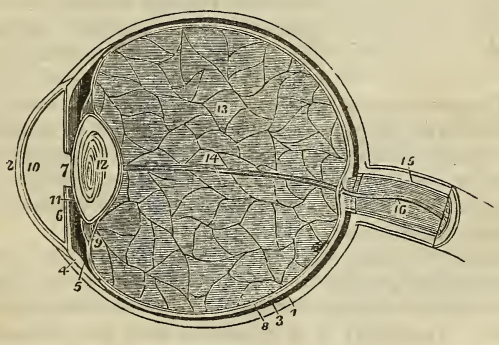

It is transparent and apparently homogeneous, but is in fact composed of numerous laminæ, between which there is a slight quantity of fluid. It is covered anteriorly by the conjunctiva, and posteriorly by the epithelium of the aqueous humour.

The *canal of Fontana* is a venous sinus, near the border of the cornea.

The *choroid coat*[a] is a thin, vascular tunic of the same extent as the sclerotica, with which it is in contact externally. It is filled with a black colouring matter called *pigmentum nigrum*, and consists principally of arteries and veins. It is traversed by several nerves. Its internal layer is composed principally of arteries, and called *membrana Ruyschiana;* externally it is composed principally of veins, called *vasa vorticosa*.

The *ciliary ligament*[c] is a flat, gray, delicate ring, at the junction of the cornea and sclerotica, which unites the external border of the iris and the ciliary body.

The *ciliary body*[3] is formed by the anterior portion of the choroid coat, in contact with the ciliary ligament, and from it proceed seventy or eighty short folds, called *ciliary processes*, which converge and are smaller behind than they are in front; they surround the lens.

The *ciliary muscle* is a small, gray structure, behind the ciliary ligament,[d] and covering the outside of the ciliary processes. Its contraction presses the lens[a] towards the cornea.[b]

Fig. 152.

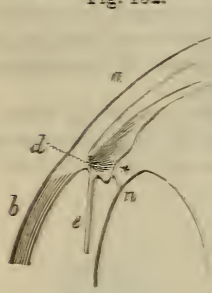

The *iris* (fig. 151) is a thin, circular membrane,[6] consisting of contractile tissue, and forming a vertical septum between the anterior and posterior chambers of the eye. It is perforated nearly in the centre by a foramen called the *pupil*,[7] which in fœtal life is closed by the *membrana pupillaris*. Its external border is attached to the ciliary ligament. The anterior surface is flat, of a bluish or brown colour, speckled and striated; towards the pupil the colour is deeper. Its posterior surface (sometimes called the *uvea*) is covered with a thick layer of pigmentum nigrum, and is in contact with the ciliary processes. It may contain a few muscular fibres in its structure. It is supplied by the ciliary arteries, branches of the ophthalmic, and by the ciliary nerves, which pass from the lenticular ganglion through the choroid coat to be distributed upon it.

The *retina*,[3] is a soft, white membrane, within the choroid coat, and is considered by some to be an expansion of the optic nerve, and by others as a distinct nervous structure in connexion with the optic nerve. Internally it is in contact with the vitreous humour.

It commences at the optic nerve, and terminates anteriorly by a jagged edge, called *ora serrata*, behind the ciliary body. It is thicker behind than it is in front. When perfectly fresh it has a pinkish tint, and is semi-transparent. Its inner surface is of a fibrous character, consisting of radiating tubular fibres of the optic nerve. Its external surface consists of a finely-granulated matrix, interspersed with very delicate vessels. The *optic nerve*,[15] enters the globe of the eye on the inner side of its axis, and the point where it is connected with the retina is incapable of vision. Directly in the axis there exists upon the retina the yellow spot of *Soemmering*, a slight elevation with a minute perforation in its summit. The central artery of the retina enters through the optic nerve, and traversing the vitreous humour, supplies the retina and lens.

Membrana Jacobi.—Is a thin lamina, existing between the choroid and the retina, consisting of a number of club-shaped rods, interspersed with transparent cells.

The *vitreous humour*[13] has a transparent, jelly-like appearance, and is of a globular form. It consists of a viscous fluid, held in cells formed from the hyaloid membrane, which surrounds it. It is colourless, and its structure is best exhibited by freezing.

The *canal of Petit*,[9] is formed between the laminæ of the hyaloid membrane, and surrounds the edge of the lens.

The *zone of Zinn*, is a circle of plaitings upon the vitreous humour, which dove-tail with the ciliary processes.

The *Crystalline lens*[12] is a double convex lens, whose posterior surface is more convex than its anterior. In childhood it is spherical, and in old age it is flattened. It is transparent and soft, and surrounded by a capsule which contains a thin fluid, called *liquor Morgagni*. It consists of concentric laminæ, having a tendency to divide into three equal segments.

The *aqueous humour*[10] is a transparent fluid, occupying the anterior and posterior chambers of the eye, bathing the posterior surface of the cornea, and the anterior surface of the capsule of the lens. It is from four to five grains in quantity. This is said to be secreted by the membrane of Demours, which lines the whole of the anterior and posterior chambers. This membrane can only be traced upon the posterior surface of the cornea.

The *eyebrows* are two elevations of the skin covered with short, stiff hairs, protecting the eye from too strong a light, and from the perspiration flowing down the forehead; they materially affect the expression of countenance. The space between the two is called *glabella*.

The *eyelids* or *palpebræ*, consist of skin, muscular fibres, cartilage, and mucous membrane; and when in contact, leave a triangular canal, which passes transversely between them. Their edges are

covered with *cilia*, or eyelashes, which are short, stiff, curved hairs, protecting the eyeball.

Tarsal cartilages.—Are two in number. That of the upper lid is larger than that of the lower; they are crescentic in shape, and attached by the external and internal palpebral ligaments.

Fig. 153.

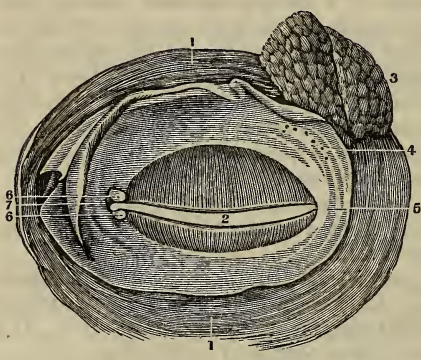

Conjunctiva.—Is a soft mucous membrane lining the lids, and covering the anterior surface of the ball, forming a fold called *plica semilunaris*, near the inner canthus. It is vascular, and well supplied with nerves.

Meibomian glands.—Are twenty or thirty small yellow thread-like glands between the conjunctiva and the posterior surface of the lids, discharging by numerous orifices along the edges of the lids a viscid fluid which prevents the overflow of tears at night.

Caruncula lachrymalis.[7]—A small, red elevation, in the internal canthus, about the size of a grain of wheat; consisting of an aggregation of small sebaceous glands, and often furnished with hairs.

Lachrymal gland.[3]—A lobulated gland, about the size of a filbert, and of a light pink colour, situated in a fossa on the roof of the orbit, near the external angular process. It consists of two portions, viz., orbital and palpebral. It discharges tears by ten or twelve ducts,[4] whose orifices open upon the upper and outer part of the conjunctiva.

Lachrymal canals.—These open by two small orifices upon a papilla at the inner part of each lid, called *puncta lachrymalia*.[6] The tears enter these orifices and are conveyed along a bent canal into the lachrymal sac.

Fig. 154.

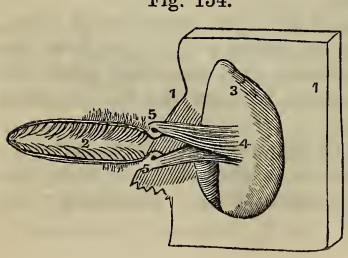

Tensor tarsi or *Horner's muscle.*—(Fig. 154.)—Arises from the os unguis,[4] and is inserted by two divisions[5] into the orifices of the lachrymal canal. Its nasal face adheres to the lachrymal sac.

Lachrymal sac and *nasal duct.*—Is a continuous tube

contained in the passage formed by the nasal process of the superior maxillary, the unguiform, and inferior turbinated bones. Its external coat is fibrous, and its internal mucous; it is larger above than it is below, and opens into the inferior meatus of the nose. The mucous lining forms a semicircular fold or valve.

The muscles: *Levator palpebræ superioris.*[4]—*Origin*, near the optic foramen. *Insertion*, by a broad aponeurosis into the upper lid. It draws the lid upwards.

The *four straight muscles*, arise around the optic foramen; and are inserted, by tendinous expansions, within a few lines of the cornea. They are called superior,[9] inferior,[13] internal,[10] and external.[11]

Fig. 155.

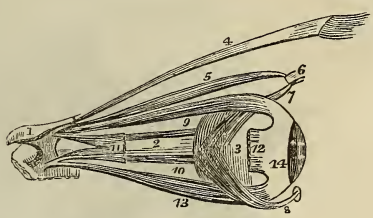

The *superior oblique muscle*,[5] arises from the edge of the optic foramen, and plays over a tendinous pulley[6] upon the orbitary ridge of the frontal bone; is inserted into the sclerotica beneath, and beyond the superior rectus.

The *inferior oblique*,[8] arises from the nasal process of the superior maxillary bone; and passing below the inferior rectus, is inserted beyond it, into the sclerotica.

THE EAR.

The organ of hearing is composed of three parts: the External Ear, the Middle Ear, or tympanum, and the Internal Ear, or labyrinth.

The *external ear* consists of two parts, the *pinna*, which is moveable upon the side of the head, and the *meatus*, a tube leading from it.

The *pinna* has a number of ridges and hollows upon its surface; these are: a prominent rim or *helix;* and within it another curved prominence, the *antihelix*, which bifurcates above, so as to enclose a space, called the *scaphoid fossa*, and surround a deep, capacious, central cup, the *concha*. The space between the helix and antihelix is the *fossa innominata*. At the end of the helix, in front of the concha, is a small detached eminence, the *tragus*, so named from its bearing a tuft of hair, resembling a goat's beard. Opposite this, behind and below the concha, is the *antitragus*. Below is the pendulous *lobe*, composed of dense areolar and adipose tissues. The *concha* is imperfectly divided into an upper and lower part, by the anterior curved extremity of the helix.

The *skin* of the pinna is thin, and contains an abundance of sebaceous follicles.

The *fibro-cartilage* is an oval, elastic plate, of a yellowish colour, in which are several fissures filled up with fibrous tissue. It is attached by an *anterior ligament*, which is triangular, broad, and strong, to the zygomatic process, and by the *posterior ligament* to the mastoid process.

Fig. 156.

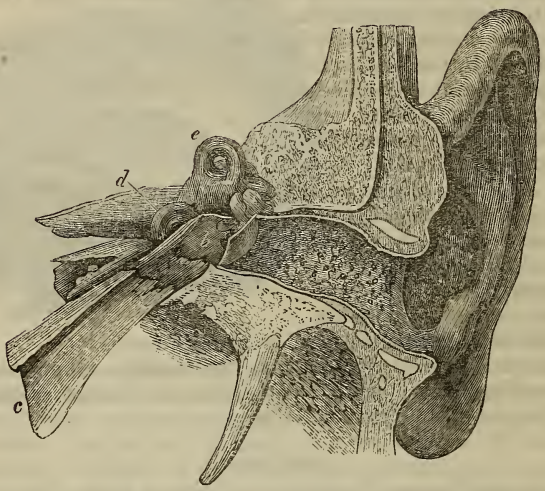

The muscles which move the pinna as a whole are the *attollens auriculæ*, arising from the aponeurosis of the occipito-frontalis; and inserted into the outer side of the cartilage of the ear opposite the scaphoid fossa: the *attrahens auriculæ*, arising also from the same aponeurosis in front of the zygoma, and inserted into the forepart of the helix; and the *retrahens auriculæ*, arising from the mastoid process of the temporal bone, and inserted into the back part of the concha. There are also some small muscles upon the pinna itself. The *major helicis* is narrow, about half an inch long, thin, and situated at the arched superior and anterior part of the helix; its fibres are vertical. The *minor helicis* is very small, and situated at the inferior and posterior arch of the helix. The *tragicus* is three-cornered, tolerably thick, with vertical fibres upon the tragus. The *antitragicus* is narrow and short, and passes from the antitragicus to the antihelix. The *transversus auriculæ* is on the posterior surface of the ear, extending from the convexity of the concha to the external part of the antihelix. The *dilatator conchæ* extends from the meatus auditorius to the anterior part of the tragus, which it draws forwards, and thus dilates the concha. The

obliquus auriculæ is upon the internal surface of the ear, between the elevations of the fossa innominata and the concha.

The *meatus*[a] is a cartilaginous and bony canal, of about one inch in length, narrow in the middle, and curved downwards; the skin lining it is covered with hairs, and glands secreting wax.

Fig. 157.

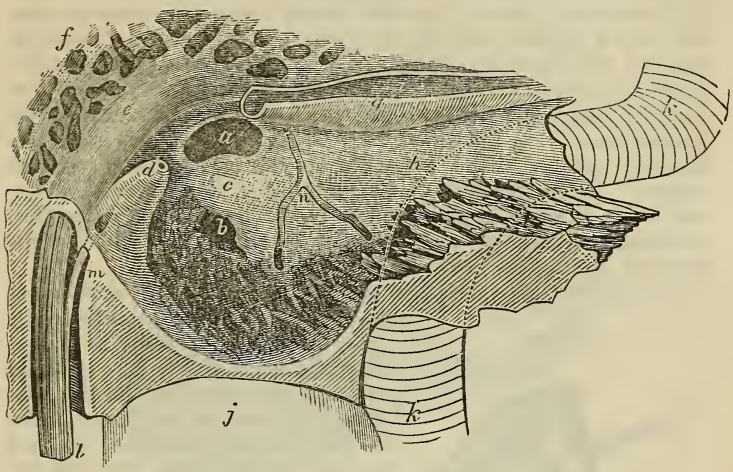

Membrana tympani.—The drum of the ear is a thin, semi-transparent, oval membrane, separating the cavity of the tympanum from the external ear. Its internal surface is slightly convex, and attached to the handle of the malleus. It is directed obliquely downwards and inwards, and it consists of three laminæ, the middle of which is strong and fibrous, and attached to the rim of the bone. The external surface is a continuation of the cuticle, and the internal of the mucous membrane, lining the cavity.

The *middle ear* or *tympanum*[b] is a small, irregular, bony cavity, in the petrous portion of the temporal bone, and bounded in front by the membrana tympani. It is filled with air, which enters by the Eustachian tube;[c] and contains a chain of small bones, and openings into the mastoid cells.

The internal wall of the tympanum has two orifices of communication with the internal ear in the dried bone; the *fenestra ovalis*,[a] an oblong opening leading to the vestibule, and the *fenestra rotunda*,[b] opening into the cochlea; both of these are closed by membrane, which prevents the escape of fluid contained in these inner chambers, and communicates vibrations to it. The fenestra ovalis is also closed by the foot-piece of the stapes. Between the fenestra

is the promontory,[c] an elevation corresponding to the first turn of the cochlea, and furrowed with two or three grooves for the nerves which form the anastomosis of Jacobson. The *pyramid*[d] is a small conical projection behind the fenestra ovalis, presenting a small orifice at its summit, through which emerges the tendon of the stapedius muscle, which is contained within. At the base of the pyramid is an aperture through which the chorda tympani enters the tympanum; thence this nerve passes forwards between the handle of the malleus and the long arm of the incus, and emerges through the Glaserian fissure. Above the pyramid an arched prominence[e] indicates the course of the aqueduct of Fallopius, close to the tympanum, and behind this is the free communication with the mastoid cells. At the upper part of the tympanum is the cochleariform process, which bounds the canal of the tensor tympani muscle. Below this is the commencement of the *Eustachian tube*, which is a straight canal, about two inches long, at first bony, then cartilaginous, and opening by a trumpet-shaped orifice into the pharynx, behind the inferior turbinated bone.

The *Bones* of the tympanum are four in number;[1] the *malleus*, or hammer, has a *head*,[m] separated by a *neck* from a *handle*,[h] which is imbedded in the drum of the ear. A slight projection from the neck, receives the insertion of the tensor tympani muscle. The *processus gracilis* is long and thin, and extends from the neck forwards and outwards to enter the Glaserian fissure; to it is attached the laxator tympani muscle. A short conical process projecting from the back of the head, articulates with the incus.

Fig. 158.

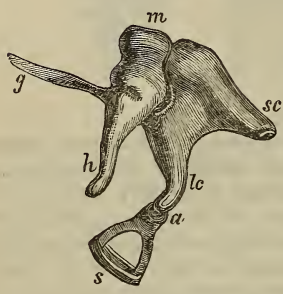

The *Incus*, or anvil, resembles a molar tooth. Its body articulates with the malleus. Its *short crus*[sc] is directed backwards, and projects towards the mastoid cells. Its *long crus*[lc] has a hooked apex, which is bent inwards, and in contact with a small lenticular bone, called *orbiculare*,[a] which is often fused into the incus.

The *stapes* or stirrup has its base or foot-piece[s] fitting the fenestra ovalis; one of its sides is more curved than the other, and its head is in contact with the orbiculare.

The *muscles* moving these bones are the *tensor tympani*, arising from the spinous process of the sphenoid bone and from the Eustachian tube, and passing through that canal above the Eustachian tube, to be inserted into the upper part of the handle of the malleus, which it draws inward, and thus stretches the membrane of the tympanum.

The *laxator tympani* arises from the spinous process of the sphenoid bone, and passes through the Glaserian fissure, to be inserted into the processus gracilis of the malleus. There is sometimes another and lesser laxator tympani. The *stapedius* arises from the interior of the pyramid, and its tendon escapes from its summit, to be inserted into the head of the stapes.

Fig. 159.

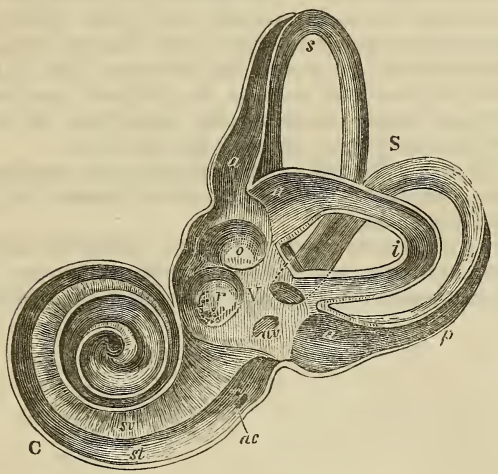

The *Internal ear*, or *labyrinth*, consists of a bony and membranous portion; the bony labyrinth consists of three parts, the *vestibule* (V), the *semicircular canals* (S), and the *cochlea* (C).

The *vestibule* is a small, three-cornered cavity, behind the internal wall of the tympanum; into it open the semicircular canals,[s] by five orifices behind, and the cochlea, by a single one in front. On its outer wall is the fenestra ovalis,[o] and on its inner, several minute holes, including the macula cribrosa, for the entrance of a portion of the auditory nerve. The *aqueduct* of the vestibule also penetrates it, from the posterior surface of the petrous bone. It also contains two depressions, called *fossa hemispherica* and *fossa semi-elliptica*.[o]

The semicircular canals[s] are three curved cylinders of half a line in diameter, whose extremities open into the vestibule by five orifices, each extremity being expanded like a flask and called *ampulla*.[a] Two of these canals[sp] are vertical, and one is horizontal.[o]

The cochlea resembles a snail-shell, and consists of a conical canal, which makes two turns and a half spirally around an axis called the

modiolus, which is a porous mass of bone, whose base is perforated by the filaments of the cochlear nerve. The *tube* of the cochlea is divided into two passages by the *lamina spiralis*, which terminates at the apex with a hook, called *hamulus;* which is covered by the *cupola*. The upper passage of the canal is called *scala vestibuli*, and the lower is the *scala tympani*. These passages communicate by an opening at the apex called *helicotrema*. The scala vestibuli opens into the vestibule, and the scala tympani through the fenestra rotunda into the tympanum. The *aqueduct* of the cochlea opens by one extremity into the scala tympani, and by the other upon the inferior surface of the petrous portion of the temporal bone.

THE MEMBRANOUS LABYRINTH has the same shape as the bony cavities which it lines, and consists of a delicate membrane composed of several layers, containing the limpid fluid of Cotunnius, and the two small calcareous masses called *otoconites*.

The *endolymph* is the fluid contained within the membranous labyrinth; the *perilymph* is the fluid contained between the bony and membranous labyrinths.

THE AUDITORY NERVE enters the meatus auditorius internus and divides into a vestibular and cochlear branch, which are expanded upon the membranous labyrinth and the walls of the cochlea.

THE END.

LIBRARY OF CONGRESS
0 005 516 925 1